Jejunal Feeding Tube Causing Intestinal Pneumatosis and Fulminant Portal Venous Gas Embolism

Intestinal pneumatosis and gas in the portomesenteric vein are most often associated with intestinal infarction, necrotic small bowel, or gastric volvulus [1,2]. Surgical treatment should be considered in symptomatic patients [3].

We report here the case of a 21-year-old man with Niemann–Pick disease who presented with acute abdominal pain. Due to neuromuscular malfunctions, he had received a percutaneous endoscopic gastrostomy (PEG) with a jejunal extension 2 years previously, as well as a permanent tracheostoma. Initial laboratory findings showed an elevated lipase level, and ultrasonography revealed edematous pancreatitis. Liver enzymes, inflammatory parameters, and serum lactate were only slightly elevated.

When the abdominal symptoms became progressive, a second ultrasound examination showed a nearly completely extinguished liver signal, and contrast-enhanced computed tomography (CT) revealed distinct pneumatosis within the jejunal wall and fulminant gas embolism in the portal vein system (Figure **1**). An exploratory laparotomy was carried out due to suspected intestinal ischemia, but no signs of mesenteric ischemia or of a necrotic process were found. Since a small amount of blood emerging from the feeding tube was noted intraoperatively, an upper endoscopy was carried out, which showed ulcerative inflammation in the proximal jejunum. The end of the jejunal feeding tube was not visible. Because of the ulcerations, the jejunal tube was extracted, and it became apparent that the plastic protective cap that the system usually has was missing and that the metal end was lying bare (Figure **2**). Twelve hours after the endoscopic intervention, a control CT showed that most of the intrahepatic gas had spontaneously vanished. The abdominal symptoms receded, and the laboratory findings normalized.

With the absence of intestinal ischemia and the marked regression of the portal gas accumulation after extraction of the defective jejunal tube, the most likely explanation is that it was intramural invasion by the jejunal tube that caused the intestinal and portosystemic pneumatosis.

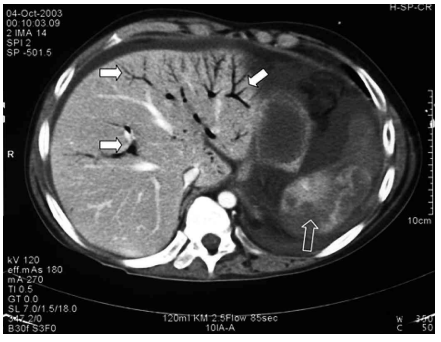

Figure **1** Contrast-enhanced computed tomography (CT) of the abdomen, showing marked air accumulations within the portal venous system (white arrows). The inhomogeneous imaging of the spleen, caused by lipid accumulation (empty arrow) due to the patient's Niemann–Pick disease. An unenhanced CT 12 h after extraction of the defective jejunal feeding tube showed distinct regression of the intrahepatic pneumatosis (not shown).

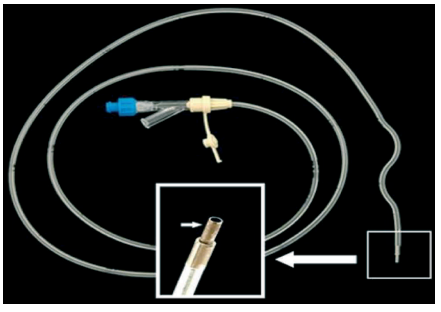

Figure **2** The extracted defective jejunal feeding tube. The arrow shows the bare metal end where the protective cap is missing.

P. Lebiedz[1], H. Ullerich[1], M. Seelig[2], W. Domschke[1], T. Kucharzik[1]

[1] Dept. of Medicine B

[2] Dept. of Surgery, University of Münster, Münster, Germany

References

[1] Lassandro F, Scaglione M, Rossi Get al. Portomesenteric vein gas: diagnostic and predicative value. Emerg Radiol 2002; 9: 96–99

[2] Pear BL. Pneumatosis intestinalis: a review. Radiology 1998; 207: 13–19

[3] Paran H, Epstein T, Gutman Met al. Mesenteric and portal vein gas: computerized tomography findings and clinical significance. Dig Surg 2003; 20: 127–132

Corresponding Author

P. Lebiedz, M. D.

Dept. of Medicine B
University of Münster
Albert-Schweitzer-Straße 33
48129 Münster
Germany
Fax: +49-251-8347570
E-mail: lebiedzp@uni-muenster.de

This document was downloaded for personal use only. Unauthorized distribution is strictly prohibited.