Paris Workshop on Columnar Metaplasia in the Esophagus and the Esophagogastric Junction Paris, France, December 11 – 12 2004

Contents

I Foreword: Exploring esophageal columnar metaplasia: a very laudable initiative
G. N. J. Tytgat, President of OMGE
(Organisation Mondiale de Gastro-Entérologie) page 880

II Foreword: Focus on landmarks at the esophagogastric junction
H. Niwa, President of OMED
(Organisation Mondiale d'Endoscopie Digestive) page 880

III Critical Review of the Diagnosis of Columnar Metaplasia in the Esophagus and the Esophagogastric Junction: the Paris Workshop, December 11 – 12 2004 page 881

IV Image Atlas page 902

This document was downloaded for personal use only. Unauthorized distribution is strictly prohibited.

Institution
International Agency For Research on Cancer

Remark
René Lambert and Prateek Sharma were guest editors for the proceedings of this workshop

Corresponding Author
R. Lambert M.D. FRCP · Screening Group · International Agency For Research on Cancer · 150 Cours Albert Thomas · Lyon 69372 · CEDEX 08 · France · E-mail: lambert@iacr.fr

Bibliography
Endoscopy 2005; 37 (9): 879–920 © Georg Thieme Verlag KG Stuttgart · New York · ISSN 0013-726X
DOI 10.1055/s-2005-870305

I Exploring Esophageal Columnar Metaplasia: a Very Laudable Initiative

Foreword by
Professor Emeritus G. N. J. Tytgat
President of the World Gastroenterology Organisation
(Organisation Mondiale de Gastro-Entérologie, OMGE)

Few entities in gastroenterology are obscured by as much confusion and uncertainty regarding definition, diagnosis, grading etc than esophageal columnar metaplasia, or Barrett's esophagus for short. Yet this nosologic entity is of particular importance as a premalignant lesion, especially now that the incidence of adenocarcinoma continues to rise. It was therefore more than timely and encouraging that René Lambert and Prateek Sharma took the initiative of bringing experts together in Paris from all corners of the world. The brief of this working party was to analyse and discuss points of agreement, of discrepancy and of uncertainty, in an attempt to come to a consensus view on this intriguing disease. The disease is indeed fascinating and challenging, not only because of its oncological significance, but also because columnar metaplasia turns out to be a unique model for studying molecular oncogenesis and also all the novel imaging modalities and facilities for tissue characterization.

Obviously to understand one another, to compare data from basic science and clinical medicine, it is essential that we all speak the same language and use the same definitions and staging modalities. As columnar metaplasia joins the cardia, it is readily conceivable that the endoscopic evaluation is prone to confusion and error. Moreover, much background noise can be created if biopsies are not meticulously targeted to either the genuine cardia or the genuine columnar segment to avoid blurring of the findings. The recognition and analysis in depth of trustworthy and reproducible landmarks (the proximal extent of gastric folds, the distal extent of palisaded vessels) for accurate and precise locating of the esophagogastric junction is obviously of vital importance in this overall diagnostic process, as shown in the detailed report that follows.

The executive office of the World Gastroenterology Organisation (WGO) is very well aware of the key importance of this in-depth analysis. The WGO/OMGE is convinced that the outcome of this working party will ultimately help and teach the practising gastroenterologist. The WGO/OMGE is convinced that Professor Lambert's creation of such a task force is the appropriate way forward and that the clinical impact will be equal to that seen after his task force on the diagnosis of colonic adenoma and early colonic cancer. It is hoped that the detailed information in this report will benefit our patients suffering from this potentially dangerous entity, and further support research to answer the many unsolved questions: whom and how to survey, how to apply chemoprevention, how to detect the person genuinely at risk, and how to manage low grade and high grade dysplasia or neoplasia and early cancer.

II Focus on Landmarks at the Esophagogastric Junction

Foreword by
Professor Hirohumi Niwa
President of the World Organization for Digestive Endoscopy
(Organisation Mondiale d'Endoscopie Digestive, OMED)

Thanks to the efforts of René Lambert and Prateek Sharma, a workshop was held in Paris in December 2004 on the subject of the endoscopic diagnosis and classification of Barrett's esophagus and columnar metaplasia in the esophagus and at the esophagogastric junction (EGJ). It was decided to publish the results of the discussions, and I would like to express my sincere congratulations on the publication of the proceedings.

It is widely acknowledged that the formation of Barrett's mucosa is based on esophageal irritation, and that cancer develops from metaplasia formed on the Barrett's mucosa. It is also known that cancer can develop from metaplasia in the proximal stomach near the cardia. These two occurrences are often confused as they have much in common, such as site, clinical findings, therapeutic methods, and prognosis.

One reason for the confusion is the lack of understanding about accurate and precise locating of the esophagogastric junction; landmarks are obviously important in standard diagnostic procedures in the EGJ and the proximal stomach near the gastric cardia. Researchers also use the terminology differently. To prevent the development of cancer in this area, a profound understanding of the premalignant lesions of the lower esophagus and proximal stomach is of critical importance. Above all, knowledge is needed most about Barrett's esophagus and the intestinal metaplasia that occurs in these areas and in the proximal stomach near the gastric cardia, and about early cancers in this area.

To understand the premalignant lesions of the lower esophagus, it is very important to know the anatomy of this region well and make correct conclusions concerning endoscopic findings, positional relationships, and pathology results. For this purpose, appropriate and standardized use of terminology is essential. A stronger emphasis has to be placed on precise knowledge regarding endoscopic findings in this area, whether gained from standard endoscopy or from the detailed examinations of the structure, condition, and consequential metaplasia of the inflamed epithelium that are made using the latest endoscopic technologies, such as magnifying scopes, endoscopic dye, and narrow band imaging video endoscopy, and so on. It is also important to have a good understanding of data gained by fluorescence endoscopy and endoscopic ultrasound (EUS).

In order to achieve proper screening and surveillance of Barrett's esophagus, it is especially important to describe the endoscopic findings using correct common terms; to have a deep understanding and precise knowledge about the condition of the areas described by those terms; and to make a proper diagnostic decision. Therefore, it was urgently necessary to standardize the vocabulary for endoscopic findings in this field so that researchers

This document was downloaded for personal use only. Unauthorized distribution is strictly prohibited.

from different countries could use the same terminology to share their understanding and discuss the areas involved.

The World Organization for Digestive Endoscopy (OMED) has several aims, including the following:

- Worldwide promotion of the study of gastrointestinal endoscopy
- Support for activities associated with the promotion of gastrointestinal endoscopy
- Establishment of standards of practice and training in gastrointestinal endoscopy
- Promotion of the standardization of endoscopic terminology and databases

The Paris Workshop on Barrett's esophagus served these aims of OMED. I would like to offer my deepest gratitude for the dedicated efforts made by Professor Lambert to bring about this achievement. I sincerely hope that the results will be fully utilized by everyone engaged in this field of study.

III Critical Review of the Diagnosis of Columnar Metaplasia in the Esophagus and the Esophagogastric Junction: the Paris Workshop*

Before 1950, a few authors had drawn attention to the possible presence of columnar epithelium in the esophagus (for example, Lyell in 1937). The anatomical finding was supported by firm evidence in 1950 when Norman Barrett demonstrated that chronic ulcers developed in esophagus that was lined by a columnar epithelium; he initially believed that this entity represented a congenital intrathoracic stomach. In 1953 Allison & Johnstone established that the columnar epithelium was located in the esophagus, and attributed its development to gastroesophageal reflux. Their point of view was adopted by Lortat-Jacob and later by Barrett himself. The presence of both complete and incomplete intestinal metaplasia (type I is complete, types II and III are incomplete), called specialized epithelium, was shown later by Boosher & Taylor and Morson & Belcher, after the initial description. Therefore the lesion was called columnar-lined esophagus (CLE) with or without intestinal metaplasia.

Since then, the name "Barrett's esophagus" has been used in most countries [1–4] to describe CLE with intestinal metaplasia as a premalignant condition; however, in the 1999 Report from the Japanese Society for Esophageal Diseases, this name is applied to CLE with or without intestinal metaplasia [5].

In addition, there is potentially misleading confusion in the description of very short segments of columnar metaplasia at the esophagogastric junction (EGJ). Indeed, errors frequently occur in the precise location of landmarks at the EGJ. In the distal esophagus above the epithelial squamocolumnar junction (SCJ), the squamous and columnar types of epithelium overlap; this is the area of development of columnar metaplasia and intestinal metaplasia in the esophagus. In the proximal stomach, just under the SCJ, areas of intestinal metaplasia in the short segment of cardiac mucosa should not be mistaken for intestinal metaplasia in the esophagus. At the EGJ, adenocarcinomas arise either from the distal esophagus or from the proximal stomach in the gastric cardia. The tumors are similar with respect to behavior, management, and prognosis; however they can arise in distinct types of columnar epithelium and relate to distinct causes of inflammation. With respect to cancer prevention, the distal esophagus and the gastric cardia should be examined as a single territory for the detection of intestinal metaplasia and neoplasia. The digital revolution in endoscopic imaging is expected to improve the classification and the reliability of epithelial characterization in this region.

Anatomical Landmarks For Endoscopy

I The Normal Situation

The EGJ is the point where the tubular esophagus joins the stomach at the cardia, with an angle between the opened esophagus and the gastric greater curvature. The distal esophagus and the proximal part of the stomach, or gastric cardia, constitute the esophagogastric region, with specific anatomical landmarks [6–18]. There are no conspicuous proximal and distal limits of the esophagogastric region. The landmarks are selected arbitrarily: 2 cm above and below the EGJ is a frequent standard. Meanwhile the classification of the upper digestive tract into three sectors:

* Participants: **Hugh Barr M.D.**, Cranfield Postgraduate Medical School, Gloucester GL1 3NN, UK; **Jacques J Bergman M.D.**, Academic Medical Centre, 1105 AZ Amsterdam, The Netherlands; **Marcia I Canto M.D.**, Johns Hopkins Hospital, Baltimore, Maryland 21205, USA; **Takao Endo M.D.**, Sapporo Medical University, Sapporo 060–8543, Japan; **Rikiya Fujita M.D.**, Cancer Institute Hospital, Tokyo 170–8455, Japan; **Pierre Hainaut Ph.D.**, International Agency for Research on Cancer, Lyon 69372, France; **Robert H Hawes M.D.**, Medical University of South Carolina, Charleston, South Carolina 29425 2220, US; **Yoshio Hoshihara M.D.**, Toranomon, Minato-ku, Tokyo 105–8470 Japan; **Haruhiro Inoue MD**, Showa Northern Yokohama Hospital, Yokohama 224–8504 Japan; **Edgar Jaramillo M.D.**, Karolinska Hospital, Stockholm, Sweden; **Michael Jung M.D.**, St Hildergardis Krankenhaus, 55131 Mainz, Germany; **Teruo Kouzu M.D.**, Chiba University School of Medicine, Chiba 260–8677, Japan; **René Lambert MD,** International Agency for Research on Cancer, Lyon 69372, France; **Charles J Lightdale M.D.**, Columbia Presbyterian Medical Center, New York 10032, USA; **Hiroyasu Makuuchi M.D.**, School of Medicine, Tokai University, Kanagawa 259–1193 Japan; **Hirohumi Niwa M.D.**, St. Marianna University School of Medicine, Kawasaki 216–8511, Japan; **Jean François Rey M.D.**, Institut Arnault Tzanck, St Laurent du Var 06700, France; **Robert Riddell M.D.**, Department of Pathology, Mount Sinai Hospital, Toronto, Ontario M5G 1X5, Canada; **Richard E Sampliner M.D.**, University of Arizona Health Science Center, Tucson, Arizona 85724 0001, USA; **Prateek Sharma M.D.**, VA Medical Center Kansas City, Missouri 64128, USA; **Stuart J Spechler M.D.**, VA Medical Center, Dallas, Texas 75216, USA; **Kaiyo Takubo M.D.,** Tokyo Metropolitan Geriatric Hospital, Tokyo,173–0015, Japan; **Hisao Tajiri M.D.,** The Jukei University School of Medicine, Tokyo 1058461, Japan; **Hidenobu Watanabe M.D.**, Niigata University School of Medicine, Niigata 951–8510, Japan

This document was downloaded for personal use only. Unauthorized distribution is strictly prohibited.

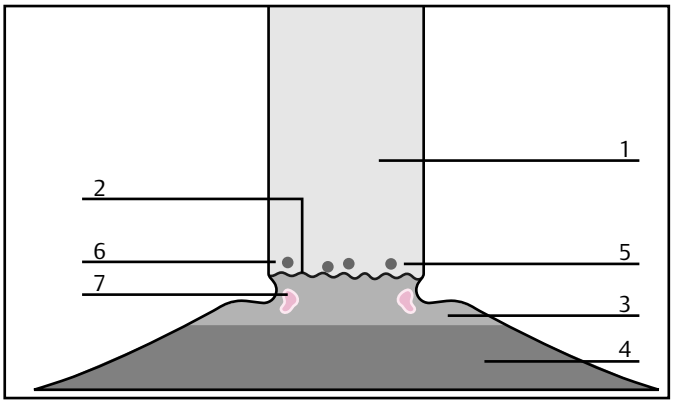

Diagram **1** Epithelial types at the esophagogastric junction (EGJ): 1, esophageal stratified squamous epithelium; 2, the squamocolumnar epithelial line in its normal position; 3, the cardiac gastric mucosa; 4, the oxyntic gastric mucosa; 5, overlapping esophageal cardiac mucosa; 6, an area of multilayered epithelium; 7, an area of intestinal metaplasia in the gastric cardiac mucosa.

esophagus, esophagogastric region or junction (EGJ), and the stomach is currently used in clinical practice [6].

The SCJ is also called the Z line ("Z" from zero, as the point where the squamous epithelial lining ends); its appearance is that of a serrated line [18]. In the normal situation, this conspicuous landmark (Figures **1**, **2**, **21**) is located in the distal esophagus, just above the pinch of the diaphragm and the dilated lumen of the stomach (Diagram **1**). In endoscopic vision, the normal esophagus is covered with a pale pink epithelium with an even surface; the stomach is covered with a darker epithelium with crests and pits. Other markers of the EGJ include the proximal extent of the gastric folds and the distal extent of longitudinal palisade vessels.

The thick and multistratified squamous epithelium of the esophagus differs from the single and folded layer of cells of the columnar epithelium in the stomach. In the columnar epithelium, the mucous cells have distinct histochemical features, due to the presence of neutral mucins that stain magenta with periodic acid/Schiff (PAS) and acidic sialomucins that variably stain in blue with alcian blue at pH 2.5. The blue stain is often confined to the mucous neck region, but sometimes extends onto the surface, although goblet cells (often referred to as "columnar blues") are absent. When goblet cells are present, these stain strongly with alcian blue because of their sialomucin and sulfomucin content, while the latter can be demonstrated in black using the high-iron diamines.

Immunostaining of tissue sections can prove helpful (Table **1**) in the following ways:

1. Characterization of glycoproteins in different mucous cells. Goblet cells and their precursor cells are positive for MUC-2 antibodies. The other mucous cells, that is gastric foveolar-type cells and cardiac (pyloric) gland-type cells, are positive for MUC-5AC and MUC-6 respectively.
2. Characterization of CD10 or villin, in the luminal membrane and brush border of intestinal absorptive cells.
3. Characterization of the phenotypes of cytokeratins (CK 7, CK 19, CK 20, CK 13, and CK 14), in the cytoskeleton; quantitative and qualitative variations of the cytokeratin phenotypes accompany cell maturation as differentiation markers. In the stratified squamous epithelium of the esophagus, the superficial cell layers express CK 4 and CK 13, poorly express CK 7, and do not express CK 18 and CK 20. In the columnar epithelium of the digestive tract, CK 8, CK 18, and CK 19 have a wide range of expression; CK 10 (characteristic of intestinal cells) is found in the gastric mucosa only in the surface cells in intestinal metaplasia of the upper digestive tract. In areas of intestinal metaplasia, the use of the ratio of CK 7 to CK 20 has been

Table **1** Phenotypic features of epithelial cells at the esophagogastric junction (EGJ). Cytokeratin (CK) 14 is associated with stratified squamous epithelium; CK 7 with columnar cells; and CK 20 with columnar cells. The mucin MUC-2 is associated with goblet cells and their precursors; MUC-5AC with foveolar gastric cells; and MUC-6 with pyloric and cardiac gland cells. The glycoprotein CD1O is associated with the brush border of small-intestine type absorptive cells. (From the series of H. Watanabe.)

	Cytokeratins			*Mucins*			*Cell membrane*
	CK14	*CK7*	*CK20*	*MUC–2*	*MUC-5AC*	*MUC-6*	*CD-10*
Esophageal squamous epithelium	+	+/–	–	–	–	–	–
Esophageal submucosal glands, ducts	+	+	–	–	–	–	–
Multilayered epithelium	–	+	+	–	–	–	+
Barrett's esophagus, incomplete intestinal metaplasia							
Surface	–	+	+	+	+	–	–
Depth	–	+	–	+	+	+	–
Gastric complete intestinal metaplasia							
Surface	–	–	+	+	–	–	+
Depth	–	–	–	+	–	–	+
Gastric cardiac mucosa							
Foveolae	–	+	+	–	+	–	–
Glands	–	+/–	–	–	–	+	–
Esophageal cardiac mucosa							
Nonexposed	–	+	–	–	–/+	+	–
Exposed	–	+	–	–/+	–/+	+	–

This document was downloaded for personal use only. Unauthorized distribution is strictly prohibited.

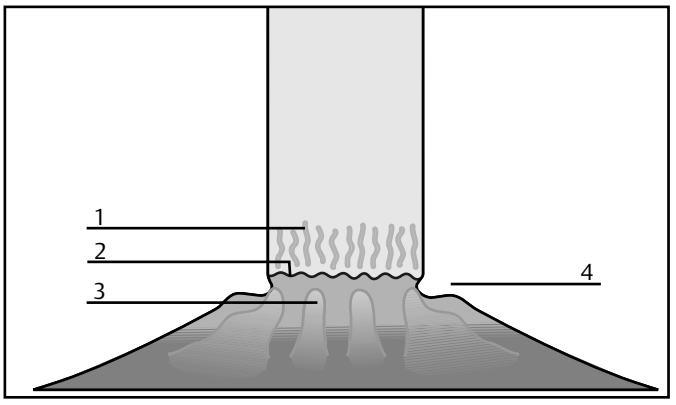

Diagram **2** Landmarks at the EGJ in the normal situation: 1, palisade vessels, proximal to the squamocolumnar epithelial line; 2, the squamocolumnar epithelial line; 3, upper pole of gastric folds; 4, diaphragmatic pinch.

proposed as a way of assessing gastric or esophageal origin; however conflicting results are presented in the literature.

1 The Proximal Border of the Squamocolumnar Junction

At this level the stratified squamous epithelium of the distal part of the esophagus shows characteristic features (diagram **2**).

Palisaded vessels in the mucosa. The palisade or longitudinal vessels, described on anatomical specimens in 1963–66 by de Carvalho [8,9], are superficial veins located in the lamina propria of the mucosa above the muscularis mucosae; these veins participate in the thoracic drainage of the submucosal venous network of the stomach. At the junction of esophagus and stomach, they pierce the muscularis mucosae and progress for a short distance in the esophageal mucosa, before returning into the submucosal layer and converging in large trunks. The distal limit of the palisade vessels is considered to be a precise marker of the junction of the esophagus with the stomach [12,15]. At endoscopy, the palisade vessels are best visualized in the distal 2 cm of the esophagus, at the level of the lower esophageal sphincter, when the lumen is distended by insufflation (Figures **3**, **22–25**). Palisaded intramucosal vessels are also present in the mucosa of the esophagus at the level of the upper esophageal sphincter (Fig. **31**, **32**). It has been postulated that the intramucosal location of the vessels in two areas that are subject to higher mechanical pressures is a protection against ischemia [10].

Small islands of ectopic gastric mucosa. At the epithelial junction, the columnar epithelium and the squamous epithelium frequently overlap (Figures **2,4,10–16**). The length of this overlap varies within the range 5–10 mm, and at endoscopy islands of gastric mucosa can often be found in the distal 1-cm segment of the esophagus. These islands correspond to more superficial areas of the epithelial overlap, and protrude slightly through the covering squamous epithelium. The islands have a yellowish color (Figure **33**) and remain unstained after application of iodine/potassium iodide solution (e.g. Lugol staining).

This ectopic gastric mucosa in the distal esophagus, has been analyzed in the pathology series from H. Watanabe [17], and was found to be mainly composed of cardiac (pyloric) gland-type cells, fewer mucous neck cells, a few surface mucous cells, and some parietal (oxyntic) cells. Its location justifies the name "esophageal cardiac mucosa". The pyloric gland cells express the MUC-6 antigen and express MUC-5AC slightly, with a few scattered cells being positive for ATPase (oxyntic or parietal cells). Others, the mucous neck cells and chief cells, are positive for pepsinogen I; the former being positive for MUC-6 and the latter negative for it. (Figures **11,12**).

The esophageal cardiac mucosa can be covered by the squamous epithelium (nonexposed type) or be exposed to intraluminal contents (Figures **15,16,34,35**). It is postulated that the ectopic epithelium in the exposed areas undergoes formation of more gastric foveolae and even occurrence of scattered goblet cells that are positive for MUC-2, and characteristic of intestinal metaplasia. (Figures **13,14**, from the series of G. and H. Watanabe). In the Japanese literature, the reported length of esophageal cardiac mucosa measured 4.6 mm (range 1.0–10.0 mm) on average [17] and, more recently, 5.6 mm (range 0.6–14 mm).

Areas with a multilayered epithelium. In Japan these have been reported to be present in up to 49% of surgical specimens at the EGJ [15,16]. The focal areas with a multilayered epithelium are classified as metaplastic pseudo-stratified epithelium [16]. These small areas are detected on histology but cannot be seen at endoscopy (Figure **17**). The multilayered epithelium is constituted by fewer than ten layers of stratified cells; the deep layers resemble basal squamous epithelial cells; the superficial layers show an increasing degree of mucinous differentiation and some ciliated cells similar to those of the respiratory tract (bronchial metaplasia). Immunohistochemical staining has confirmed the presence of neutral and acidic mucins. The cells express both CK 13 (a marker of mature squamous epithelium) and CK 7 and CK 20 (markers of columnar epithelium). In addition the multilayered epithelium often expresses the surface protein villin, which characterizes differentiation in the intestinal type.

Pancreatic acinar-like cells. Pancreatic metaplasia [15] occurs in the mucosa of the distal esophagus as nodules with pancreatic acinar-like cells that stain positive for lipase, trypsinogen, and amylase, and have fine eosinophilic granules. The cells are similar to those of the pancreatic exocrine glands (Figure **18**).

2 The Distal Border of the Squamocolumnar Junction

Distal to the Z line, the lumen is lined with the mucosa of the gastric cardia. A short segment of gastric cardiac epithelium (Figure **5**) is present between the Z line and the oxyntic epithelium which lines a part of the cardia (Figures **36–40,42–44**). The transition between the two epithelial types is often continuous with an area of oxyntocardiac mucosa followed by epithelium with parietal and chief cells. The cardiac type of epithelium comprises mucous neck cells expressing MUC-AC5 and pyloric gland cells expressing MUC-6, just as in the mucosa of pseudopyloric gland metaplasia of the fundic mucosa. The length of cardiac mucosa is very short (2–6 mm on average) [17] and its transverse extension is not always complete. In a study of operative specimens, the median length of cardiac mucosa was 5 mm and it was circumferential in only half of the specimens [14]. In a recent autopsy study, cardiac mucosa was missing in half the cases, and the median length of the cardiac plus oxyntocardiac mucosa was less than 5 mm in 76% of cases [11].

This document was downloaded for personal use only. Unauthorized distribution is strictly prohibited.

The morphology of the normal gastric cardiac mucosa (Figures **6**, **36–39**) is often altered by inflammation and hyperplasia e.g. foveolar hyperplasia (Figures **40**, **41**). In carditis, islets of intestinal metaplasia (complete, type I) are frequent (Figure **7**). The prevalence of carditis in adults is high and intestinal metaplasia has been demonstrated at endoscopy in up to 30% of persons, with or without reflux symptoms. Intestinal metaplasia at this level should not be mistaken for intestinal metaplasia of the esophagus.

3 *The "Pinch" of the Diaphragm and the Junction of the Esophagus and the Stomach*

During endoscopy, the passage of the distal esophagus through the diaphragmatic hiatus into the abdomen is marked by a pinching of the lumen that, in the normal situation, is visible just distal to the SCJ (Figure **19**, **20**). Near to the diaphragmatic pinch, the imaginary line corresponding to the anatomical junction of esophagus and stomach, can be located with the help of two landmarks: the proximal extent of the gastric folds, and the distal end of the palisade vessels, if visible.

In summary, as stressed in the proceedings of the American Gastroenterological Association (AGA) Chicago Workshop [4], the endoscopic description of the EGJ relies on three landmarks:

1. The first landmark, the squamocolumnar junction (SCJ) relates to the mucosal surface.
2. The second landmark, the anatomical junction of the esophagus and stomach, concerns the full thickness of the digestive wall. The upper pole of the folds in the gastric mucosa is an intraluminal landmark.
3. The third landmark, the pinch in the lumen caused by the diaphragm is exterior to the digestive wall.

In the normal situation the three landmarks are close to one another: the junction of the esophagus with the stomach is located in the abdomen, just below the diaphragmatic pinch with the upper margin of the longitudinal gastric folds coinciding with the SCJ. A minimal sliding (a few millimeters) of the anatomical junction to just above the diaphragmatic pinch is frequent, without formation of a hiatal hernia. Precise analyses have been conducted on anatomical specimens to assess the distance between the SCJ and the anatomical junction of the esophagus with the stomach; the figure averaged from 11 mm in Western countries [7] to just 3 mm in Japan [15]. Reliable assessment of this small distance during endoscopy is, however, difficult.

II The Abnormal Situation

1 *Hiatal Hernia*

In the presence of an hiatal hernia, the relative positions of the three endoscopic landmarks have been changed due to the intrathoracic location of the proximal stomach. The SCJ and the anatomical junction of the esophagus with the stomach have moved to a position frankly proximal to the pinch of the diaphragm.

2 *Columnar Metaplasia in the Esophagus*

When the SCJ is located proximally to the anatomical junction of the esophagus and stomach [19–27], a segment of the esophagus is lined with metaplastic columnar epithelium (CLE). The metaplastic epithelial lining shows a mapping of areas with a cardiac type of epithelium (Figure **47**), areas with an oxyntic mucosa, and areas with goblet cells showing a different distribution in surface and depth of cytokeratins CK 20 and CK 7 (Figures **48**, **49**). In these areas, intestinal metaplasia occurs as complete type I (Figures **50**, **51**) or incomplete type II or III (Figures **52**, **53**). The latter type, called a specialized epithelium, includes elements intermediate between gastric cells and intestinal goblet cells. The increased risk of cancer in patients having CLE is considered to be confined to those in whom this specialized epithelium is present, and in these cases the metaplastic segment is called a Barrett's esophagus.

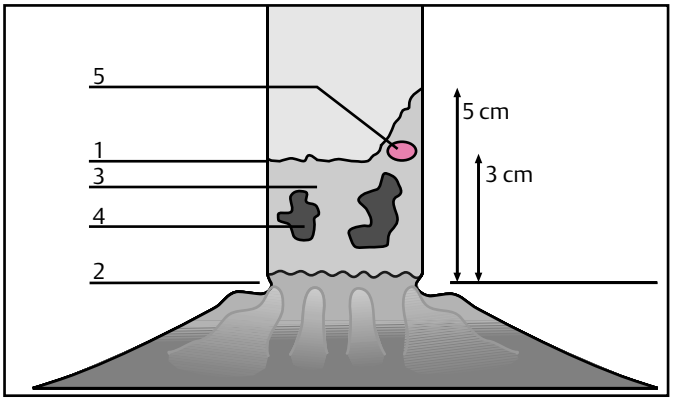

Diagram **3** Landmarks in the columnar-lined esophagus (CLE): 1, the squamocolumnar epithelial line, ascended a few centimeters; 2, the original squamocolumnar epithelial line; 3, gastric type of columnar metaplasia in the esophagus; 4, intestinal metaplasia in the esophagus; 5, island of squamous epithelium. The segment with metaplasia is classified as C3-M5 according to the C&M Prague classification.

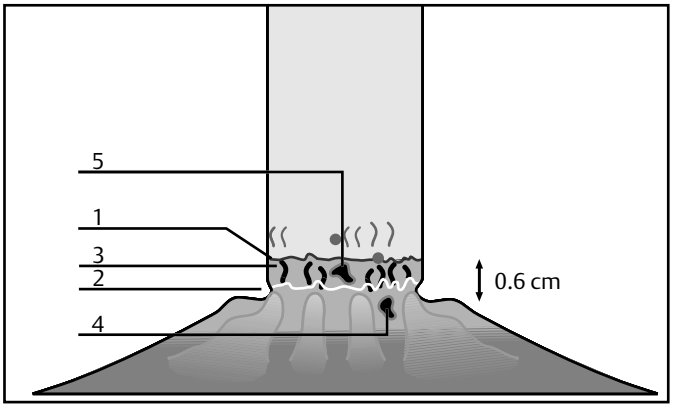

Diagram **4** Landmarks in columnar metaplasia at the EGJ junction: 1, the squamocolumnar epithelial line, ascended a few millimeters; 2, the original squamocolumnar line; 3, palisade vessels distal to the neo-formed squamocolumnar epithelial line in a segment of columnar metaplasia; 4, an area of complete intestinal metaplasia in the gastric cardiac mucosa; 5, an area of intestinal metaplasia in the short segment of gastric columnar metaplasia in the esophagus.

The length of the metaplastic columnar segment is the distance between the neo-formed SCJ and the anatomical EGJ (diagram **3**). The reliability of the evaluation depends on the precision of the determination of the EGJ at endoscopy. A segment of columnar metaplasia in the esophagus is classified as "long" (≥3 cm) or "short" (<3 cm). Recently a new definition of the endoscopic extent of this segment has been introduced and validated in the so-called Prague C&M classification: the endoscopist assesses the distance between the upper end of the gastric folds and the up-

This document was downloaded for personal use only. Unauthorized distribution is strictly prohibited.

per margin of the segment with circumferential metaplasia (the "C" value); and the maximal proximal extent of the metaplastic segment is also estimated (the "M" value). The evaluation may prove reproducible between operators when the segment reaches at least 1 cm in length. It is worth using the C&M classification rather than the "long" and "short" terminology. Very short segments (less than 1cm) should rather be called "CLE at the EGJ."

3 Columnar Metaplasia at the EGJ

At the EGJ, in the distal esophagus, short segments of CLE frequently exist; they occur either as small tongues protruding in the esophagus or as very short, less than 1 cm in length, circumferential segments (diagram **4**). In those very short segments (C < 1, M < 1), intestinal metaplasia is seldom found in random biopsies; but its frequency increases when multiple serial histological sections are made or when biopsies are repeated in follow-up endoscopies [21]. With regard to clinical practice, it is unclear whether there is an increased risk of cancer when intestinal metaplasia is not detected in random biopsies of a very short segment of columnar metaplasia.

At the EGJ, intestinal metaplasia is often present in the mucosa of the gastric cardia, and should not be mistaken for intestinal metaplasia in a very short CLE. Tissue sampling requires extreme precision with respect to the SCJ and the other anatomical landmarks. The columnar epithelium just distal to the SCJ must be scrutinized: the presence of palisade vessels or of small islands of squamous epithelium suggest the presence of a short segment of CLE (Figure **26–30**).

4 Residual Squamous Islands in Columnar Metaplasia

In the esophagus, in long segments of columnar metaplasia, small islands of stratified squamous epithelium are seen along the surface with a density of 3–4 per square centimeter (Figure **62**). In a recent study [25], such small islands of squamous epithelium were identified in 78% of patients with a segment of CLE. The openings of the excretory ducts of the esophageal glands proper, into the esophageal lumen, occur in the squamous islands.

At the EGJ, in very short segments of columnar metaplasia the presence of very small squamous islands just below the slightly displaced SCJ (Figure **26**, **27**) confirms that the zone explored corresponds to the esophagus.

III Verification in the Surgical Specimen

In operative specimens that include the EGJ, two distinct features are considered to be specific markers of the esophageal wall and help in assessing the respective positions of the SCJ and the anatomical junction of esophagus with the stomach, as well as the presence of columnar metaplasia in the esophagus. These are the double muscularis mucosae and the esophageal glands proper.

1 The Double Muscularis Mucosae

In the esophagus with columnar metaplasia, the muscularis mucosae often shows a superficial and a deep layer, similar to that seen in the colon in ulcerative colitis (Figure **45**). The deep layer is the original while the superficial layer develops in association with the metaplastic epithelium as a result of chronic inflammation [15]. The distal end of the superficial muscularis mucosae connects with the original deep layer at the EGJ.

2 The Esophageal Glands Proper

These tubuloacinar glands, located in the submucosa of the esophagus below the muscularis mucosae [15,24–27], develop in the postnatal period and are supposed to arise as ingrowth from the squamous epithelium [26,27] (Figures **5**, **8**). Their serous and mucous cells (Figure **9**) deliver bicarbonate and mucus into the esophageal lumen. Near the surface, the cuboidal cells of the excretory duct show a gradual transition with the stratified squamous epithelium [26] (Figure **8**). The ducts are often sinuous and oriented downwards toward the stomach (Figure **46**).

In surgical specimens with CLE the emergence of the ducts across the columnar epithelium occurs in the small persisting squamous islands [24,25]. In forceps biopsy samples taken in segments with CLE (Figure **56**), residual excretory ducts can often be detected.

Pathophysiology

I Gastroesophageal Reflux

1 Prevalence of CLE and Gastroesophageal Reflux Disease (GERD)

The prevalence of gastroesophageal reflux disease (GERD) and of CLE has been extensively analyzed in the literature [28–38]. Symptoms of heartburn are associated with intestinal metaplasia in the esophagus, as well as with intraepithelial neoplasia and adenocarcinoma, suggesting a common pathway among the severe manifestations of reflux disease.

Population-based studies have shown that occasional symptoms of reflux affect one-third of the population, while the prevalence of daily symptoms is 7–10% [36]. In recent years there has been an increased incidence of GERD in many Western countries. The trend is also occurring among Asiatic populations in whom reflux symptoms are less frequent.

The prevalence of CLE in the general population is difficult to estimate because as many as 80% of patients remain undiagnosed, as demonstrated by the Olmsted county (USA) autopsy study [29]. A recent study conducted in the same county has shown a 28-fold increase in the incidence of clinically diagnosed cases in the period 1965 to 1995; however this variation was paralleled by an increased use of endoscopy [31]. The widespread use of acid-inhibition therapy has reduced the risk of peptic strictures, but not that of CLE with intestinal metaplasia. The effect of proton pump inhibition therapy (PPI) remains to be clarified.

Studies of demographic characteristics (ethnicity, gender, age) have shown that CLE with intestinal metaplasia, is a disease of middle-aged white men. Recent studies have investigated the prevalence of CLE in patients undergoing a gastroscopy for dyspeptic symptoms, or in conjunction with a colonoscopy. The prevalence was found to be 6%–7% in caucasian populations

This document was downloaded for personal use only. Unauthorized distribution is strictly prohibited.

Table **2** Prospective series on the prevalence of columnar-lined esophagus (CLE). Gastroscopy was performed in patients who were asymptomatic, or complaining of dyspepsia, or having colonic endoscopy. The rates in Asiatic countries are lower for the long type

	Country	*Number of patients*	*CLE %*	*Type (short/ long/in total)*
Connor et al., 2004 [32]	USA	264	6.1	Total
Toruner et al., 2004 [38]	Turkey	395	7.5	Total
Rex et al., 2003 [37]	USA	961	5.5 1.2	Short Long
Gerson et al., 2002 [33]	USA	110	17.0 7.0	Short Long
Azuma et al., 2000 [28]	Japan	650	15.7 0.62	Short Long
Lee et al., 2003 [35]	Korea	1553	0.32	Total

which is 10-fold higher than in Asian populations (0.6%) (Table **2**).

Short segments of columnar metaplasia in the esophagus are more frequent and are often unrecognized at endoscopy. Epidemiological data on their prevalence may therefore be less reliable. Some data are shown in Table **2**. In the USA the prevalence of short segments varied between 5.5% [37] and 17.0% [33]; in Japan it was estimated at 15.7%, although that assessment was based on endoscopic appearance rather than histological confirmation after biopsy [28].

2 *Causal Factors of CLE and Carditis*

In patients with GERD, clinical studies have shown that several factors may be related to the occurrence of CLE [39–50]: gastroesophageal reflux of acid, bile, compromised clearance of refluxed material from the esophagus back into the stomach, esophageal dysmotility, weakened lower esophageal sphincter, and frequent transient relaxations of the lower esophageal sphincter (TRLES). Columnar metaplasia occurs as a response to chronic inflammation in the mucosa and the submucosa. Oxygen-derived free radicals play a role in inflammation of the submucosa.

In the cardia and distal esophagus the mucosa is exposed to acid stress. In the postprandial period the pH is usually lower in the distal esophagus than in the stomach and the 24-hour acid exposure (pH < 4) is greater just above the EGJ (5 mm) than at the conventional measurement level (5 cm); this occurs even in the absence of GERD [42,43]. The injurious effects of bile acids and salts is suggested in the experimental animal model that diverts duodenal reflux at the level of the cardia [45]. The diversion is followed by the development of a foveolar epithelium in the esophagus with mucous glands without parietal cells. Subsequently intestinal metaplasia develops with goblet cells. Endoscopic studies with biopsies have been conducted [40,49] in human patients treated by esophagogastrostomy after resection of the cardia: metaplasia of a gastric cardiac type of mucosa develops in the esophageal remnant, with intestinal metaplasia (complete type) in some cases.

At the EGJ the gastric cardiac mucosa distal to the epithelial junction is also exposed to multiple injurious factors, including acid and mechanical trauma. The presence of *Helicobacter pylori* infection in the stomach plays a role, while there is a negative association with the development of CLE.

3 *Reversibility of Columnar Metaplasia*

In CLE with intestinal metaplasia, columnar metaplasia shows no spontaneous tendency to revert to stratified squamous epithelium. There is debate about the amount of regression occurring during the medical and surgical treatment of reflux. Overall, the regression is partial and has not been shown to prevent the risk of neoplasia (Figure **54**).

II Intestinal Metaplasia

Multiple observations [51–68] have shown that the risk of cancer in columnar metaplasia is linked to the presence of intestinal metaplasia (incomplete type II or III). In the esophagus, the metaplastic transformation most likely starts with columnar metaplasia, which is then followed by the occurrence of incomplete intestinal metaplasia. Recent studies suggest a role of *TP63*, a member of the same gene family as *TP53*, which encodes several proteins specifically expressed in the maturation of squamous cells [60]. In the human esophagus, expression of p63 proteins is restricted to squamous cells and is undetectable in columnar metaplasia. The current hypothesis is that in the absence of p63, stem cells in the mucosa may be unable to enter the squamous differentiation pathway, resulting in their differentiation into columnar cells. In the gastric cardiac mucosa, distal to the normally located SCJ, intestinal metaplasia occurs frequently in association with inflammation (carditis) and manifests in most cases as complete type I.

1 *Intestinal Metaplasia in the Esophagus*

Some have attributed the development of specialized epithelium in the esophagus at the proximal border of the squamocolumnar epithelial line to the migration of pluripotent gastric stem cells. Migrant stem cells from extradigestive sites (medullary bones) may also play a role. However the most plausible source is in the esophagus itself. Distinct features at the proximal border of the esophagus, have been proposed as potential sources of metaplasia.

The multilayered epithelium [15,58,65], is a possible source, according to some Western experts [58]: it shows morphological characteristics of both squamous and columnar epithelium, and contains mucins; the double potential has been confirmed by the phenotyping of cytokeratins. Intestinal metaplasia and goblet cells (positive for MUC-2 and villin) have been associated with the multilayered epithelium, but the further steps of passing from the complete to the incomplete type of intestinal metaplasia have not been demonstrated. The role of this epithelium has been questioned by the pathology school of Bayreuth and in Japan [65]: CLE is rare in Japan while the multilayered epithelium is frequently encountered in surgical resection specimens.

This document was downloaded for personal use only. Unauthorized distribution is strictly prohibited.

The stratified cuboidal epithelium of the excretory ducts of the submucosal esophageal glands proper may be another possible source of the metaplastic process [15]. This epithelium also has a double potential with cells expressing cytokeratins of the immature stratified squamous epithelium (CK 14) and of columnar epithelium (CK 7 and CK 19), but they are negative for CK 13 and for mucins. In contradiction to the hypothesis supporting the role of the ducts, rats can develop a CLE-like epithelium [45] although submucosal esophageal glands and ducts are not present in rodents.

Ectopic gastric mucosa (esophageal cardiac mucosa) overlapping with the squamous epithelium, is accepted, particularly in Japan, as the most probable source of CLE. In the nonexposed (covered) islands, the phenotypic characteristics of the mucous cells differ from those of the cells in the in situ gastric cardiac mucosa. According to this theory, columnar metaplasia develops in the uncovered areas of esophageal cardiac mucosa exposed to gastroesophageal reflux. The exposed areas subsequently show changing phenotypic characteristics, and intestinal metaplasia (incomplete type II or III) can be present [15], as shown in the pathology series from H. Watanabe. The clinical relevance of the Japanese theory is that those islands of esophageal cardiac mucosa are accessible to endoscopic vision and deserve to be explored as specific targets.

2 *Intestinal Metaplasia in the Cardiac Mucosa*

The origin of the segments of cardiac mucosa is still a subject of debate: are they congenital and present in the embryo, or are they acquired through inflammation? Short segments of cardiac mucosa (mean length 1.8 mm) have been detected at autopsy in pediatric patients [11], as well as the aforementioned overlapping of the squamous and columnar epithelium.

In the cardiac mucosa, the frequent occurrence of complete intestinal metaplasia (type I) is considered to carry a very low risk factor for cancer. A study of demographic features has shown differences between intestinal metaplasia in the esophagus (short CLE) or at the gastric cardia [59]. Intestinal metaplasia in the esophagus and intestinal metaplasia of the cardia also have distinct immunohistochemical characteristics: for example, there is a difference between the ratio of cytokeratins 7 and 20 [54–56, 61, 68]; however the specificity of this distinction is challenged by other authors [62]. The debate also concerns the comparison of intestinal metaplasia in the esophagus and intestinal metaplasia of the gastric antrum: the clear-cut difference in the CK7/CK20 profile shown in one series [63], was not found in another. Other tests have been proposed, and immunohistochemical analyses using mucin antibodies have shown distinctly different patterns for intestinal metaplasia of esophageal or gastric origin [53, 58].

In summary, esophageal cardiac mucosa in the distal esophagus is the most plausible origin of metaplasia with specialized epithelium. The occurrence of intestinal metaplasia in the gastric cardiac mucosa is frequent. Differences have been shown between the phenotypic characteristics of intestinal cells at esophageal and gastric sites, but there is still debate about their specificity with regard to the determination of the origin of the cells.

III *Cancer In Columnar Metaplasia*

1 *Carcinogenesis in Columnar Metaplasia*

Factors increasing the risk of adenocarcinoma in the esophagus or at the cardia include excess body mass, smoking, alcohol, tobacco, and reflux symptoms [39, 44, 46–48, 50].

The hostile environment at the EGJ plays a major role in the transition from inflammation to metaplasia and cancer [69–79], with remodeling of the microvascular network [78]. An important promoting factor in this respect is the intraluminal generation of nitric oxide, which originates from nitrite that has been converted, by oral and pharyngeal bacteria, from dietary nitrate excreted in the saliva. The concentration of nitric oxide reaches a maximum at the EGJ and cardia, where it may be converted into carcinogenic N-nitroso compounds [75]. Inducible nitric oxidase synthetase (NOS) is also involved in angiogenesis; CLE with intestinal metaplasia is strongly neo-vascularized and neo-angiogenesis of immature blood vessels in the lamina propria has been confirmed by immunochemistry [69, 78].

Another factor relevant to the process of inflammation and carcinogenesis is the inducible cyclo-oxygenase (COX-2) which is found to be increased in CLE [77]. COX-2 inhibits apoptosis and promotes angiogenesis. The increased expression of COX-2 is an early event in the progression from metaplasia to neoplasia. As a result, there is a perspective for chemoprevention against esophageal adenocarcinoma, using COX-2 inhibitors [72, 76]. Based on immunohistochemical studies, the median staining scores for COX-2 enzyme were 2 in non-neoplastic metaplasia, 3 in low grade and 14 in high grade intraepithelial neoplasia, and 13 in confirmed adenocarcinoma (personal series from T. Endo).

2 *Adenocarcinoma in the Esophagus*

The information on the frequency of adenocarcinomas in the esophagus and at the EGJ is collected in tumor registries that publish annual numbers of new cases and deaths [79–87]. Population-based registries also take into account the age characteristics of the population. The incident cases and the crude incidence rate per 100 000 persons represent the actual burden in a country at a given time interval. Comparisons between countries require reference to the age-standardized incidence rate (ASR) using a world population as template.

The tumors are categorized according to topography and histology using the World Health Organization International Classification of Diseases for Oncology (WHO–ICD-O) classification. The four-digit registration includes subsites C15.5 for the distal third of the esophagus and C16.0 for the gastric cardia. The reliability of data depends on the proportion of unspecified or misclassified cases, (i.e. NOS, not otherwise specified). For esophageal cancer in most registries, the proportion of NOS is less than 15%. For stomach cancer this proportion may reach 50%–80% in some large registries. Imprecision in classifying cancers occurs in the distribution of cases in the distal third of the esophagus and in the gastric cardia; therefore the ratio of cases registered at the two distinct subsites is not fully reliable. Temporal variations in the incidence of cancer at one of the subsites may result from a change in tumor registration. This occurs when a new method of exploration or treatment is introduced, or when excessive attention is paid to a category of tumors (i.e. tumors of the cardia).

This document was downloaded for personal use only. Unauthorized distribution is strictly prohibited.

Table **3** Adenocarcinoma of the esophagus: incidence rate during the period 1993–97. Age-standardized (world population) incidence rates per 100 000, in some cancer registries. The figures are still low, even in countries with the highest rates. (From *Cancer incidence in five continents, vol. VIII*; IARC publication no. 155, IARC Press, Lyon, 2002 [83].)

	Incidence rates per 100 000	
	Men	*Women*
High rate		
USA, SEER (white)	2.75	0.34
Scotland (five registries)	5.93	1.55
Moderate rate		
France (Côte d'Or)	2.49	0.27
Low rate		
USA, SEER (black)	0.63	0.15
Italy (Varese)	0.72	0.04
Japan (Osaka)	0.32	0.05

SEER, Surveillance, Epidemiology, and End Results Program of the US National Cancer Institute

Table **4** Adenocarcinoma in the esophagus and the gastric cardia: new cases during the period 1993–97. Cases recorded in the esophagus and stomach, in some registries. For stomach cancers, the files only include the cases registered as "gastric cardia" (four-digit classification). In this series, the average ratio for cardial to esophageal cases is 1.7. (From *Cancer incidence in five continents, vol. VIII*, IARC publication no. 155, IARC Press, Lyon, 2002 [83].)

	Men		*Women*	
	Esophagus (all)	*Gastric cardia*	*Esophagus (all)*	*Gastric cardia*
USA, SEER, white + black	1838	2029	334	522
Japan, Myagi registry	40	562	5	179
Japan, Osaka registry	103	699	24	241
Singapore, all races	25	144	7	54
France, Bas Rhin registry	35	107	8	20
France, Côte d'Or registry	46	49	9	9
Italy, Varese registry	24	96	3	42
Netherlands, two registries	1590	2266	543	638
Norway, national registry	173	437	38	162
Switzerland, Basel registry	27	73	9	22
Total	3901	6643	980	1889

Data corrected for this bias can be obtained with the help of specific software.

Adenocarcinoma of the esophagus is not a frequent tumor outside of the USA and some areas of northern Europe. In most countries the ASR for 1993–97 [83] ranges between 1 and 2.5 per 100 000 in men and is less than 1 per 100 000 in women (Table **3**). These incidence figures are relatively low compared with those for stomach and colorectal cancer. In the International Agency for Research on Cancer (IARC) GLOBOCAN 2002 database, for the entire population of the more developed countries of the world (just under 1.2 billion people), the cancer ASRs for men and women, respectively, are estimated at 22.3 and 10.0 for the stomach and at 40.0 and 26.6 for the colon/rectum. With respect to subsite classification, there are fewer cases in the esophagus than at the gastric cardia, as shown in the 1993–97 files [83] of *Cancer incidence in five continents* (Table **4**).

Time trends for cancer incidence can be expressed as the per cent change per year. Data from registries in eight countries for the period 1973–95 are shown in Table **5**. In most countries, for both sexes, the incidence of adenocarcinoma of the esophagus has increased. In American surgical series (esophagectomy for cancer) a tenfold increase in the proportion of esophageal adenocarcinoma occurred in the interval 1970–1990. The increasing trend is present in the USA [79, 81, 87], in Australia, and in countries of Northern Europe such as UK, Netherlands, Denmark, and Norway [80, 82]. On the other hand, the incidence at the gastric cardia is stable when the figures are adjusted according to the quality of the data [85]. Finally, the incidence in the distal stomach is decreasing.

3 *Adenocarcinoma at the EGJ*

The burden of adenocarcinoma at the EGJ [88–99] is the sum of cases at the gastric cardia and in the lower third of the esophagus (C15.5 plus C16.0). The risk is higher in men than in women (Ta-

Table **5** Time trends for adenocarcinoma in the esophagus and gastric cardia during the period 1973–95. The trend is presented as per cent change per year of the incidence rate during the period. For the gastric cardia the observed rates are presented and also adjusted rates that take into account the quality of data registration. The incidence increases in the esophagus but is stable in the cardia after data adjustment. (From Vizcaino et al.)[85]

	Men			*Women*		
	Esophagus (all) Observed	*Gastric cardia Observed*	*Adjusted*	*Esophagus (all) Observed*	*Gastric cardia Observed*	*Adjusted*
USA, white, 1973–95, SEER (nine registries)	+8.6	+2.8	+0.3	+6.8	+2.6	−0.3
USA, black, 1973–95, SEER (nine registries)	+4.1	+3.0	+1.1	+13.8	+3.8	+2.2
Canada, seven registries	+4.6	+1.5	−0.8	+6.0	+1.1	−1.5
Scotland 1981–95, five registries	+3.1	+2.4	−0.5	+4.8	+0.8	−2.0
Denmark, 1978–95, national registry	+7.9	-0.8	−2.8	+4.6	−1.3	−3.7
Netherlands, 1978–92, Eindhoven registry	−1.6	+1.7	−1.7	+0.8	+4.6	+1.3
Switzerland, two registries	+4.2	+0.6	−0.5	+12.1	+1.8	−3.0
France, 1978–92, four registries	+2.8	+0.9	−0.7	+5.5	−0.6	−2.7

This document was downloaded for personal use only. Unauthorized distribution is strictly prohibited.

Table **6** Adenocarcinoma at the esophagogastric junction (EGJ): new cases during the period 1973–93. Cases recorded as occurring at the lower third of the esophagus and at the gastric cardia (four-digit registration), in some cancer registries. (From: Parkin M, Munoz M, Vizcaino P. Incidence time trends for cancers of the lung, esophagus and gastric cardia by histological type in the European community 1973–93. Final report to EU, 2000 (contract no. 97/CAN/33850).)

	Esophagus, lower third		*Gastric cardia*	
	Men	*Women*	*Men*	*Women*
USA, white, 1973–95, SEER (nine registries)	2694	392	6300	1530
USA, black, 1973–95, SEER (nine registries)	43	13	311	135
Denmark, 1978–95, national registry	169	25	793	216
France, 1978–92, four registries	358	96	2203	662
Italy, 1976–92, Varese registry	31	7	258	91
Japan, 1980–93, Osaka registry	15	6	2151	937
Total	3310	539	12016	3571

Table **7** Comparison of different characteristics with regard to adenocarcinoma in the esophagus, in the distal stomach and at the cardia. The values for the cardia fall between those for the esophagus and for the distal stomach

Characteristic	*Esophagus*	*Distal stomach*	*Gastric cardia*
Sex, male/female ratio	7/1	2/1	4/1
Race, white/black ratio	4/1	1/2	2/1
Importance of GERD	+++	0	+ –
Importance of *Helicobacter pylori*	– –	+++	+ –
Smoking	+++	+ –	++
Time trend for incidence	Increase ++	Decrease ++	Varies +/–

GERD, gastroesophageal reflux disease.

Table **8** Molecular patterns in adenocarcinomas of the esophagogastric junction. Based on a consecutive series of 123 patients recruited at the Hôpital E. Herriot, Lyon, France (Tanière et al. 2001 [98], and unpublished data from P. Hainaut)

Cancer type	*Adenocarcinoma of the esophagus**	*Adenocarcinoma of the cardia**
Siewert type [96]	*Type I*	*Type II*
Patient characteristics		
Male/female ratio	27/1	2/1
History of active smoking	72%	40%
History of other neoplasms	4%	20%
Differentiation markers		
CK7+/CK20–	24%	70.5%
Molecular markers		
TP53 mutation	56%	31%
MDM2 expression	12%	45%
MDM2 amplification	4%	19%
COX-2 expression	65%	40%

* Adenocarcinoma in the esophagus is regarded as a tumor arising at 1–3 m above the EGJ, with evidence of pre-existing CLE. Adenocarcinoma in the cardia is regarded as a tumor arising within 1 cm above or below the EGJ, without any macroscopic or microscopic evidence of Barrett's esophagus.

ble **6**). In the esophagus, the subsite "lower third" accounts for a significant proportion (two-thirds) of the cases in men. In the stomach, the subsite "gastric cardia" accounts for less than 15% of cases in men and 10% in women. It should be noted that the site 'gastric cardia' is often a misclassification in cancer registries [90].

From the perspective of the endoscopist, it is legitimate to consider adenocarcinomas at the EGJ as a single entity. After surgical treatment, tumors at the esophagogastric region (distal esophagus plus cardia) have been classified by the school of Siewert [96] into three groups, depending on the central point of the tumor: group I (esophageal origin), group II (gastric cardia), and group III (subcardial origin).

With respect to their origin, two distinct categories of tumor straddle the EGJ junction [89,92]. The comparison of some characteristics of tumors classified respectively in the esophagus, the cardia, or the distal stomach, confirms the heterogeneity of the cardia subsite and the results always fall between those of the esophagus and those of the stomach, as shown in Table **7**. Studies of molecular markers confirm the distinction between tumors of esophageal or gastric origin as shown in Table **8** [94,97,98]. A cytokeratin profile of CK7++/CK20$^-$ may correlate with an esophageal origin, although there is still debate on this issue. In the IARC database (P. Hainaut) for *TP53* mutations (DNA sequencing), adenocarcinoma of esophageal origin has a higher frequency of the G:C to A:T mutation at the CpG site than other tumors. This mutation is present in 47.9% of *TP53* mutations (82/171).

4 *The Risk of Cancer in CLE with Intestinal Metaplasia (Barrett's Esophagus)*

In symptomatic patients with reflux, columnar metaplasia is considered to be a premalignant condition if intestinal metaplasia is present. This means that there is a significant risk of developing a premalignant lesion in this susceptible epithelium. The risk of adenocarcinoma in CLE has been overestimated [100–105] and lower figures occur when the follow up is prolonged. After the index endoscopy, the risk of developing esophageal cancer during the follow up of patients having CLE with intestinal metaplasia and negative for neoplasia, was previously estimated at 1 per 100 patient-years. Actually this figure, based upon meta-analyses, is an overestimate [104]. In a recent literature survey, the incidence of cancer in Barrett's esophagus was found to vary with the size of the cohort series, and decreased as the number of patients in the cohort increased. Currently a reasonable estimate of the risk is 0.5 per 100 patient-years or one case for 200 patients followed during 1 year. The impact of esophageal adenocarcinoma on the mortality of persons with a Barrett's esophagus is probably small: a follow-up study conducted in the Netherlands in a group of 155 patients has shown that only two of them died from esophageal cancer [105]; a similar observation was made in Germany [102]. The surgical correction of reflux

This document was downloaded for personal use only. Unauthorized distribution is strictly prohibited.

does not suppress the risk for cancer [86]. Not all patients having CLE and intestinal metaplasia negative for neoplasia at the index endoscopy have the same risk for developing a cancer. Low risk factors include female sex, and asiatic and black ethnicity. High risk factors include caucasian race, male sex, old age, alcohol consumption, continuous smoking, and a long history of reflux symptoms. The most typical patient tends to be a white male over the age of 60 with an increased body mass index (BMI). Smoking and a diet poor in fruit and vegetables are other risk factors for malignant progression. This suggests that surveillance protocols should be adapted to a risk stratification.

Morphological factors also play a role: there has been debate about the correlation between the length of the segment with intestinal metaplasia and the risk of cancer. In a recent prospective cohort study [103], the odds ratio for the cancer risks of long segment (10 cm) and short segment (< 3 cm) Barrett's esophagus was 3.7 (1.8 versus 0.4 new cancers per 100 person-years). In fact, the difference in risk according to segment length is relatively small, and short segments deserve as much attention as long segments because they are more common. This justifies the specific attention given to short segments of CLE during the exploration of the EGJ.

In summary, carcinogenic agents may be present in the luminal environment at the EGJ. Adenocarcinoma at the EGJ may develop either from the esophagus or from the gastric cardia. Both tumors are more frequent in men than in women. The risk of adenocarcinoma in the esophagus increases in patients with CLE. However there has been an overestimation, and adenocarcinoma in the esophagus is still an uncommon tumor, even in the USA and some countries of northern Europe where figures are higher. However the burden may acquire a more significant dimension in the future if the temporal trend towards increase is sustained.

Endoscopic Examination

I Principles

Guidelines on principles and methods are concerned with good practice in the exploration of the esophagus and the EGJ as performed using a flexible video gastroscope [106–126]. The procedure should include a retroflexed inspection of the cardia. It has been shown that CLE can be detected endoscopically using a low resolution endoscope that includes instruments for nasogastroscopy [117,119,122]. However, when the technical standard for reliable exploration is not achieved, the index endoscopy must be repeated for precise analysis of the surface. The assessment of columnar metaplasia in the esophagus and the cardia is based on two distinct steps: detection and characterization.

1 Detection

In the everyday routine, detection of abnormalities suggestive of neoplasia will rely on standard endoscopy without the use of chromoscopy or magnification. Two elements are relevant for detecting abnormalities:

- Any irregularity of the surface of the mucosa, (slight elevation or slight depression) should be noted as a potential indicator for a neoplastic lesion.
- The color of the mucosa, which varies from a clear pink/white for squamous epithelium to reddish for columnar epithelium. The apparent color of the surface results from the absorption spectrum of the hemoglobin present in the network of capillaries across the translucent epithelium. A reddish color suggests hyperhemia and neo-vascularization; a whitish color suggests an increased density of cell nuclei, impeding the penetration of light across the epithelium

2 Characterization of Abnormalities

The characterization of identified lesions requires detailed inspection that is best performed using a recent model, high resolution video endoscope, and the routine use of chromoscopy. Optimal endoscopic imaging is completed by techniques of magnification and image processing. The elements to be analyzed are:

1. Location of the endoscopic landmarks, with special attention paid to the position and morphology of the SCJ and the anatomical junction of the esophagus and stomach.
2. Epithelial types in the area of columnar metaplasia in the esophagus or at the EGJ, with identification of areas with intestinal metaplasia.
3. Areas with an abnormal surface architecture, suggesting intraepithelial neoplasia; the clinical relevance of the procedure is linked to the reliable detection of early neoplasia.
4. The superficial vascular network (capillaries and collecting veins) visible across the translucent epithelium. In the stratified squamous epithelium of the esophagus, distinct patterns are observed in the middle esophagus and just above the SCJ. In the mucosa with columnar metaplasia, irregularities in the size and caliber of the small vessels occur in proportion to the progression of intraepithelial neoplasia.

II Methods

Techniques allowing the detailed inspection of a small area of digestive mucosa are rapidly advancing; however, such targets have to be noticed before they can be inspected. This is why standard techniques that image a broader area deserve at least equal attention. Nowadays, even in the absence of the newest technology, when chromoscopy is used, recent models of video endoscopes with high quality digital imaging meet some requirements for the detection of superficial neoplastic lesions and for their classification into subtypes.

1 Chromoscopy

Chromoscopy should be performed as needed, after identification of a target zone by means of the overview mode of a standard video endoscope or the standard view of a high resolution video endoscope. Preferably the dye should be applied with a spray catheter.

Lugol chromoscopy (iodine/potassium iodide, 1.5%–2% solution) stains the stratified squamous epithelium brown, and leaves the columnar epithelium unstained The SCJ is sharply delineated and some consider this to be helpful for demonstrating small tongues of columnar metaplasia at this level or to identify residual islands of columnar metaplasia after an endoscopic treatment. In fact, the procedure also helps in detecting the presence at the EGJ of small squamous islands distal to the SCJ (Figures **26**, **27**).

This document was downloaded for personal use only. Unauthorized distribution is strictly prohibited.

Indigo carmine chromoscopy (0.4% – 0.5% solution), is used for contrast staining of small irregularities of the surface, and is helpful in the morphologic analysis of slightly elevated, flat, or slightly depressed neoplastic lesions. In endoscopy with magnification, the distinct architecture of the epithelial types (oxyntic, cardiac, or intestinal metaplasia) may become more apparent with indigo carmine staining [120] (Figures **37**, **71**).

Methylene blue chromoscopy (0.5% solution) stains the differentiated enterocytes in blue and is proposed as a selective method for detection of intestinal metaplasia [112,115, 116,118,127,128]. The procedure requires a prior application of a mucolytic agent and, after the application of the dye, a large amount of water is required to rinse away the unabsorbed solution. Epithelial crests are stained and are evident with magnifying endoscopy (Figures **76**, **77**). Studies comparing biopsies targeted using methylene blue with random biopsies have shown that methylene blue improves the detection of intestinal metaplasia. On the other hand, staining is often weak or negative in incomplete-type intestinal metaplasia. and in areas with neoplasia. Randomized trials comparing the efficacy of methylene blue in the detection of neoplastic areas showed conflicting results: a significant improvement was shown in one trial [127], but not in others [118]. In addition, there is still debate about the clinical relevance of a report on the in vitro induction of genetic damage after methylene blue application and exposure to endoscopic light.

Cresyl violet (0.2% solution) has been used in Japan in the exploration of the EGJ, to stain columnar cells purple, during endoscopy or in stereomicroscopy of an operative specimen (Figures **102**, **103**).

Acetic acid chromoscopy (1.5% – 3%; 3% – 5% dilution) is routinely used in colposcopy for the aceto-white reaction of cervix. The transient white discoloration which occurs after spraying with acetic acid results from the increased opacity of the surface, masking the network of subepithelial vessels. Acetic acid can also be used in upper gastrointestinal endoscopy [106,107,114]. A volume of 10 – 15 ml of a 1.5% – 3% solution is sprayed in the esophagus. The application results in whitening of the stratified squamous epithelium and swelling of the columnar epithelium. In columnar metaplasia, the acetic acid test is used as a contrast agent in magnifying endoscopy (Figures **36**, **75**), but slight bleeding may follow its application. Future studies are necessary to assess the efficacy of this method in the exploration of the esophagus.

2 Magnification and Image Processing

The optical zoom. In magnifying endoscopy, an optical zoom (power range × 60 to × 150) is placed between the objective and the charge-coupled device (CCD) chip. In contrast to an electronic zoom, the optical zoom does not reduce the resolution since all the pixels on the CCD chip are used for constructing the image. Since the focal length after maximum optical zoom is short, the area covered is small. For fine adjustment of distance, a transparent cap attached to the distal tip of the endoscope is helpful for keeping the targeted area at a constant distance from the lens. The technique is still developing and further improvements are expected in the near future, such as a zoom "macro" that requires no distance adjustment, or contact objectives with the same magnification power as used in microscopy, for in vivo cytological inspection.

Magnification [106 – 116,120,121,123 – 126,128 – 131] offers the easiest approach to precise depiction of the architecture of the normal and abnormal epithelium. Magnification with contrast, after spraying an agent (i. e. indigo carmine, methylene blue, cresyl violet, or acetic acid) is done with the aim of describing the microarchitecture of the epithelial ridges [106,107,110,112,114 – 116,120,123,125,128,131]. Magnification in transparency requires no staining, and explores the network of capillaries and collecting veins [111,113,124,125,130]. The characterization of neoplastic lesions has the aim of establishing distinct patterns in low grade and high grade dysplasia, and intramucosal and invasive neoplasia.

Structure enhancement. Image processing with structure enhancement is applied to the reflected light energy and is available with instruments functioning using the RGB ("red – green – blue") sequential system or using a "color" CCD. The selective modulation (increase or reduction) of the amplitude of specific frequencies increases the contrast between areas containing small microstructures and elements containing large microstructures; this applies to pits and ridges. The endoscopist can observe the processed image in real time and the levels of enhancement are easily changed by pressing a switch. The structure enhancement function is activated in magnification endoscopy.

Color enhancement. Image processing with color enhancement also depends on the reflected light and relies on the absorption spectrum of hemoglobin. Changes in the color tone of the mucosa depend on the quantity of hemoglobin present. The technique is available with the RGB sequential imaging system; the gastrointestinal mucosa is illuminated sequentially with red, green, and blue light through a rotating RGB filter wheel. A monochromatic CCD incorporated into the distal tip of the scope detects the light reflected from the mucosa as corresponding signals in red, green and blue. A color image is reconstructed from the three sequentially obtained signals and is displayed on the color monitor. The system has a double potential: (i) correlation of the mucosal hemoglobin concentration and the calculated index of hemoglobin (IHb); and (ii) color enhancement with image processing (adaptive IHb) which makes the red areas redder and the pale areas paler. The color enhancement system coupled with magnification allows detailed inspection of the mucosal microvascular architecture of a neoplastic area.

Narrow-band imaging (NBI). Image processing with NBI is a recent development [109,121,126,129,130] and is based on the RGB sequential system. In conventional endoscopy, a broad spectrum of light is used to reproduce natural color. The depth of penetration of light depends upon the wavelength. The shorter the wavelength (or the higher the frequency of the light), the shallower the depth of penetration into the tissue. Blue light, with the shortest wavelength of visible light is absorbed, scattered, and reflected at the surface of the mucosa; mainly giving information about the epithelial surface. Green and red wavelengths penetrate more deeply into the tissue. In addition, the central

This document was downloaded for personal use only. Unauthorized distribution is strictly prohibited.

wavelength of blue light (415nm) lies within the absorbance spectrum of hemoglobin, thus emphasizing superficial capillary vessels in the endoscopic images.

In NBI a special set of filters is used to illuminate the tissue with three sequential narrow bands of light in the red, green, and blue wavelength spectra. The bandwidths vary from 20 to 30 nm, instead of from 80 to 100 nm as in a conventional RGB system, and they do not overlap. In addition the relative intensity of blue light is increased.

The blue channel collects information on the fine surface architecture of the mucosa with the superficial capillary network around the pits or the epithelial crests; the red channel provides data on the collecting vessels in the depth of the mucosa; and the green channel gives an intermediate image. In the final mixed image, superficial and deep details are superposed. There are several choices for the central wavelength for the NBI, e.g. 415, 445, or 500 nm; the central wavelength will be optimized through basic and clinical examinations.

The technique only requires the endoscopist to switch the optical filters to change from conventional imaging to NBI, allowing enhancement of the surface architecture without using a dye, and it also allows simultaneous examination of the capillary network and collecting vessels [109,121,130].

High Definition Television (HDTV). The resolution of the image increases with the number of pixels in the CCD; however the TV signal in the conventional NTSC or PAL systems (standards for television broadcasts) is another limiting factor. The number of pixels can be increased when the digital processing circuit is compatible with HDTV (high definition television), which improves the final image resolution by increasing the number of scanning lines. A considerable advance is expected from the emerging technology of HDTV which can be adapted to NBI endoscopy. In addition, electronic magnification may now prove to be just as effective as optical zooming without the difficulty of obtaining images that are in focus.

3 *Spectroscopic Techniques and Autofluorescence Imaging (AFI)*

Spectroscopic techniques involve optical measurements with spectrally resolved features that may precisely indicate the biological nature of the area examined [132–136]. However spectroscopy samples only a small area at a time and it does not function as a "red flag" technique. In a sense it can be compared with taking random biopsy samples. Various techniques have been proposed for the exploration of CLE; they require equipment not available in routine endoscopy and their sensitivity is higher than their specificity. These methods include: fluorescence imaging in ultraviolet light, with or without an exogenous fluorescent agent; fluorescence imaging in the near infrared range, for the analysis of the vascular network after injection of a fluorescent dye (indocyanin green), or for molecular imaging with fluorescent antibodies; trimodal spectroscopy, using three simultaneous spectroscopic methods, that is, autofluorescence, elastic scattering, and diffuse reflectance, for discrimination between low grade and high grade intraepithelial neoplasia; and proton magnetic resonance spectroscopy.

Prototype endoscopic imaging systems have only been developed for the fluorescence techniques. Earlier autofluorescence imaging (AFI) prototypes were incorporated into fiber optic endoscopes which reduce white light imaging. The most recent models of video endoscopes adapted to AFI use sequential RGB illumination, and detect an autofluorescent image that is excited by blue light and a reflectance image in the green spectrum. In the superposed image, the neoplastic areas are displayed in purple color on a greenish background of nondysplastic mucosa. The Amsterdam group [135] has shown that AFI in the exploration of CLE, may assist in drawing the attention of the endoscopist to areas that may potentially harbor neoplasia; AFI may increase the detection rate of early neoplasia in CLE, and the yield of metachronous lesions.

4 *Endoscopic Ultrasonography (EUS), and Optical Coherence Tomography (OCT)*

The endoscopic ultrasound (EUS) features of CLE [137–140] have been described using both conventional EUS instruments for endoscopic ultrasound and high frequency miniprobes (20–30 MHz). Mucosal thickening has been described in patients having CLE, but wall thickness in itself is not a reliable criterion for differentiating normal from dysplastic epithelium. A more reliable criterion might be the relative thickness of the second layer compared with the first. EUS does not contribute to the detection of CLE with intestinal metaplasia, but the technique is required for tumor staging prior to any decision regarding curative endotherapy.

Optical coherence tomography (OCT), which allows the in-depth exploration of the mucosa, is based on interferometry in the infrared range [141–142]. The probe transferring the incident and reflected infrared light is passed through the working channel of the endoscope and operates in air. There is a tenfold increase in resolution compared with EUS at 30 MHz, but the depth of penetration is limited to the submucosa. Distinct images are obtained for the stratified squamous epithelium and for the columnar metaplasia. The ability of OCT to detect the first stages of neoplasia is, however, still debated.

III Endoscopic Examination at the EGJ

1 *Without Magnification*

In the distal esophagus, the normal SCJ or Z line is easily detected as a serrated line (Figure **21**). Chromoscopy helps in the examination of the stratified squamous epithelium proximal to the SCJ: the islands of the ectopic or esophageal cardiac mucosa do not stain, or stain poorly, with iodine/potassium iodide solution; the SCJ is shown in greater contrast using acetic acid; and irregularities in the architecture of the cardiac mucosa can be enhanced with indigo carmine.

When there is a minimal ascension of the Z line, the careful identification of endoscopic landmarks is crucial to determine whether a short segment of columnar metaplasia lines the distal esophagus above the anatomic gastric cardia. The measurement of short segments (less than 1 cm) with metaplasia, is poorly reliable in this moving target, particularly when the EGJ slides across the hiatus. Attention should be focused rather on the position of the landmarks. Overinsufflation during endoscopy may flatten the gastric folds, leading to overestimation of the length

This document was downloaded for personal use only. Unauthorized distribution is strictly prohibited.

of columnar metaplasia in the esophagus (Figures **19**, **20**). On the other hand, excessive aspiration will result in prolongation of the folds into the distal esophagus, masking a short segment of columnar metaplasia in the esophagus. This is why the end of the "palisade zone" of vessels in the mucosa also proves to be a helpful marker (Figures **22–25**). In the normal situation they are visible from the anatomical junction of the esophagus and stomach, and therefore in a position proximal to the SCJ. Sufficient insufflation is essential to identify these vessels, because the stretching of the mucosa contributes to recognition; however their visibility can be impaired by esophagitis, and they are not visible in approximately 10% of patients.

The presence of a short segment of columnar metaplasia in the distal esophagus is suggested when the palisade vessels are visible in a position distal to the SCJ (Figures **28–30**). Iodine/potassium iodide solution is also of great help in the identification of small residual islands of squamous epithelium, distal to the ascended squamocolumnar epithelial junction (neo-SCJ) in a short segment of columnar metaplasia, which confirms that the segment explored actually belongs to the esophagus (Figures **26**, **27**).

In summary, at the EGJ a careful endoscopic exploration of the sectors proximal and distal to the SCJ requires alternate section and insufflation to assess the position of landmarks such as palisaded vessels or small islands of squamous epithelium distal to the SCJ. Examination with sufficient air inflation is necessary to detect these minute and unremarkable lesions which are concealed by folds. The procedure will determine any macroscopic alteration in color, network of superficial vessels, or irregularity in the surface, that is suggestive of intraepithelial neoplasia.

2 *With Magnification and Image-Processing Techniques*

In the segment proximal to the SCJ, high resolution endoscopy with magnification and image processing (NBI and IHb) improves the analysis of the palisade vessels and of the areas with ectopic esophageal cardiac mucosa, either covered (Figure **33**) or exposed (see Figures **34**, **35**).

In the segment distal to the SCJ, the surface pattern is that of a columnar epithelium (Figures **36–41**, **43**, **44**) with a short segment of cardiac gastric epithelium which can be incomplete and may increase in length when there is gastroesophageal reflux or *H. pylori* infection with carditis. The cardiac gastric mucosa is characterized by regular and contiguous oval crests; in carditis a villous pattern is frequent (Figures **40**, **41**) The oxyntic mucosa distal to this segment displays regular crypts on a smooth surface; its morphology can be altered if there is *H. pylori* infection (Figure **42**). The morphological transition from cardiac to oxyntic is either progressive with a zone of mixed pattern (Figure **38**) or sharp (Figure **39**). In the gastric cardia, intestinal metaplasia is suspected when the epithelial crests are larger, of irregular size, and separated by parallel grooves and a ridged pattern. Guelrud et al. [106], in a study of 195 patients with a SCJ in a normal position, detected intestinal metaplasia in 44% and confirmed the correlation with the ridged pattern seen at endoscopy.

When there is a slightly ascended SCJ, a very short segment of CLE, showing a mucosal pattern similar to the gastric cardiac mucosa, covers the distal esophagus and is located between the misplaced SCJ and the gastric cardiac mucosa lining the proximal part of the anatomic gastric cardia.

In summary, magnifying endoscopy and image processing at the EGJ enhances the visibility of palisaded vessels, and helps in assessment of the position of the SCJ with respect to the end of the esophagus. In the columnar epithelium distal to the SCJ, the technique aims to detect areas with intestinal metaplasia and exclude any pattern suggesting intraepithelial neoplasia.

IV Endoscopic Examination of the Esophagus

1 *Without Magnification*

Under endoscopic vision, the presence of a neo-formed SCJ in the esophagus is a conspicuous marker and the surface of the columnar epithelium is redder and darker than that of the squamous epithelium. Finger-like extensions are often present at the epithelial junction. The length of the segment of CLE between the SCJ and the anatomic junction of the esophagus and stomach, is either short (Figures **57–61**) or long (Figures **63–67**), with persisting small islands of squamous epithelium. The risk of cancer in CLE correlates with the presence of intestinal metaplasia. The surface of the segment with metaplasia should be explored carefully with respect to irregularities or color changes suggesting the presence of intraepithelial neoplasia. The detection and characterization of the specialized epithelium still relies on histology only.

Although any extent of columnar metaplasia may put the patient at risk for malignancy, careful grading of the length may be important when an attempt is made to measure response to medical or surgical therapy, and also to assess the effect of endoscopic ablation therapy. The length can be measured against the scale marked on the sheet of the instrument, while pulling out the tube in order to minimize the curvature against the pharynx. The extent (1 to 10 cm in length) is calculated in centimeters by subtracting the distance from the neo-formed SCJ to the anatomic EGJ marked by the top of the gastric folds. A working group, originating from the International Working Group on Reflux Esophagitis (Los Angeles Classification) has led an effort at standardization: with the Prague C&M criteria, the circumferential and maximal extent of esophageal columnar tissue are graded in centimeters. For example, C3-M5 corresponds to a circumferential segment of columnar metaplasia at 3 cm above the EGJ and a noncircumferential segment or tongue extending up to 5 cm above the junction. C0-M3 corresponds to a single tongue of metaplasia extending 3 cm above the EGJ. Using standardized and high quality video recordings of the three landmarks in the distal esophagus (the EGJ, the diaphragmatic hiatus, and the squamocolumnar epithelial line), the interobserver agreement with the C&M grading system has been evaluated using the kappa value; preliminary results indicate that the reliability coefficient for lengths > 1 cm is high, while grading for segments of columnar metaplasia of less than 1 cm, and using a millimeter scale, is poor.

This document was downloaded for personal use only. Unauthorized distribution is strictly prohibited.

In summary, when the guidelines for upper gastrointestinal endoscopy with a standard instrument are followed, CLE is easily detected when the segment is longer than 1 cm. Good practice now recommends the grading of the longitudinal and circumferential extension of this segment according to the C&M criteria proposed in Prague.

2 With Magnification and Image-Processing Techniques

High resolution endoscopy with magnification and image processing (NBI, IHb) shows the microarchitecture of the columnar epithelium in the esophagus with depressions called pits or grooves, and elevations called crests or ridges. Chromoscopy is of some help in the identification of each type of epithelium present in the segment of columnar metaplasia: acetic acid enhances the relief and methylene blue may selectively stain cells in areas with intestinal metaplasia. The NBI technique proves helpful in the analysis of the surface pattern of the epithelium and of the vascular network (Fig. **82**, **83**). The oxyntic mucosa is characterized by the small round openings of pits, regularly distributed in a even surface, while cardiac mucosa and intestinal metaplasia share a morphology of alternating elongated pits or grooves and elongated epithelial ridges. Variants include linear ridged patterns, curved and branched or gyrus patterns, and villous patterns (Figures **68–81**).

To justify the relevance of exploration using magnification, multiple classifications have recently been proposed: Guelrud et al. [107], using a magnification of ×35 and acetic acid, describe four types; Endo et al. [128], using a magnification of ×80 and methylene blue, identify five types; and Sharma et al. [120], using magnification of up to ×15 and indigo carmine, describe three types (ridged, circular, and irregular). In 2004, Toyoda et al. [123], using magnification of up to ×115 and acetic acid in the exploration of columnar metaplasia in the esophagus and at the EGJ, identified three distinct patterns: type I consists of small round pits (oxyntic mucosa); type II is reticular with horizontally elongated pits (cardiac mucosa); and type III is gyrus, cerebroid, or villous (intestinal metaplasia). In the same year, Guelrud et al. [108] using magnification of ×80 added further divisions to his classification, which now includes eight distinct types.

The main purpose of those classifications in magnifying endoscopy is to identify areas with intestinal metaplasia; however the microarchitecture of the mucosal surface explored with magnification is not yet fully reliable with respect to histological correspondence, even when the NBI technique, which improves the analysis, is used (Tables **9**,**10**) Large ridges, and branched and gyrus patterns have a high yield (over 80%) for intestinal metaplasia [120]. However intestinal metaplasia is also described in 5%–30% of samples with other patterns [123]. The reliability of methylene blue as a specific marker is challenged by a study [128] where staining was positive in only half of the samples with intestinal metaplasia. In another study [115], including 51 patients, intestinal metaplasia was histologically detected in 31. The interobserver variability was tested, for four examiners, in magnification endoscopy with the help of acetic acid or methylene blue; the accuracy of prediction of intestinal metaplasia in endoscopic observation was only 50%.

Table **9** Magnifying endoscopy (conventional or narrow-band imaging (NBI)). Imaging scores* for diagnosis of specific features in the esophagus. Images obtained by NBI are more reliable. (Unpublished data, presented by T. Endo.)

Feature scored	*Method*	*Scored as 3 or 4, n/n (%)*	*P value*
Squamous islands at squamocolumnar junction	Conventional NBI	38/54 (70%) 52/54 (96%)	< 0.001
Capillary vessels	Conventional NBI	11/20 (55%) 8/20 (40%)	= 0.420
Pit pattern in columnar metaplasia	Conventional NBI	18/28 (64%) 28/28 (100%)	< 0.001

* Images of a number of fields in the same area were obtained using both methods. The images were graded as follows: 4, perfect; 3, fairly sharp; 2, just visible; 1, not visible. Images with scores 3 and 4 were judged to be reliable.

Table **10** Magnifying endoscopy (conventional or NBI) in the detection of intestinal metaplasia in columnar-lined esophagus: reliability of endoscopic diagnosis versus histopathology. Endoscopy with indigo carmine chromoscopy is as accurate as NBI. (Unpublished data, presented by T. Endo.)

Technique	*No. of cases*	*Sensitivity*	*Specificity*	*Accuracy*
Conventional	35	24%	67%	46%
NBI	35	56%	95%	77%
Indigo carmine chromoscopy	26	55%	100%	81%

Endoscopic analysis is based on the classification of the pit pattern using five groups [128]. Groups 1, 2, and 3 are classified as negative for intestinal metaplasia; groups 4 and 5 are classified as positive.

In summary, in magnifying endoscopy the surface of the columnar epithelium lining the esophagus can show distinct patterns, as shown in diagram **5**:

- **round pits**, small and evenly distributed in a flat surface
- **long oval crests**, separated by narrow depressions
- **ridges**, that are linear and straight, separated by narrow depressions
- **curved crests,** that are circular or branched in a gyrus pattern
- **villi**, similar to the intestinal epithelium

The histological concordance of a pattern with a type of epithelium, oxyntic, cardiac or specialized epithelium with intestinal metaplasia, is incomplete. Meanwhile there is some consensus for considering that round pits often correspond to oxyntic epithelium, oval crests often correspond to cardiac epithelium, and that gyrus, branched, and villous patterns correspond to intestinal metaplasia. Cerebroid and ridged patterns have a very high predictive value for intestinal metaplasia, justifying selective target biopsies.

This document was downloaded for personal use only. Unauthorized distribution is strictly prohibited.

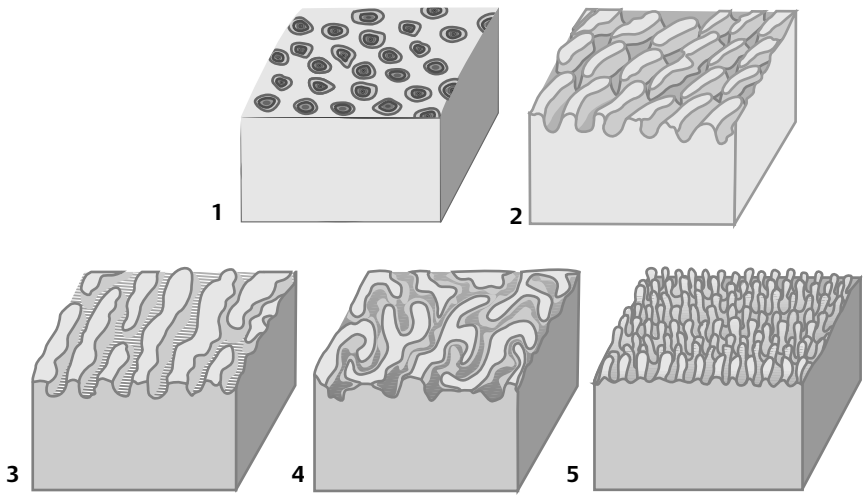

Diagram **5** Microarchitecture of epithelial types in nondysplastic columnar metaplasia (as seen at zoom endoscopy): 1, round pits; 2, long oval crests; 3, linear or ridged crests; 4, curved or gyrus crests; 5, villous type.

V Endoscopic Examination of Neoplastic Lesions

1 Without Magnification

Superficial neoplastic lesions occurring in columnar metaplasia in the esophagus or at the cardia include low grade and high grade intraepithelial neoplasia (Figures **86**, **90**, **97**, **98**) and confirmed adenocarcinoma in the mucosa or in the submucosa (Figures **104 – 119**). Such lesions are detected if the attention is drawn by irregularities in the relief of the mucosal surface, by a spot with color change, or by variations in the network of superficial vessels. The morphology of the suspect area is then characterized by reference to the subtypes of type 0, as in the Paris classification [143]. There are three major categories: type 0 – I for protruding pedunculated or sessile lesions; type 0 – II for nonprotruding lesions, with three subdivisions of 0 – IIa (slightly elevated), 0 – IIb (flat), and 0 – IIc (depressed), and type III for ulcerated lesions.

Pedunculated polypoid lesions (0 – Ip) are rare in the columnar epithelium of the esophagus and the cardia (just as in the distal stomach). Ulcerated (0 – III) neoplastic lesions are uncommon in the esophagus, and suggest peptic complication of reflux, rather than neoplasia. Barrett's ulcer, thought to develop in the columnar epithelium, may also occur in the squamous epithelium with re-epithelization of the peptic ulcer with columnar epithelium. Esophageal ulcers stimulate fibrosis that may result in stricture formation. Target biopsies are required in the surroundings of the ulcer to exclude neoplasia. Depressed 0 – IIc type lesions are much less frequent than in the distal stomach and occur in mixed types, combining sessile nodules, often multiple, and a depressed area.

In summary, most superficial neoplastic lesions occurring in the esophagus or at the EGJ can be categorized as flat (0 – IIb), slightly elevated (0 – IIa), or sessile (0 – Is). Intraepithelial neoplasia often adopts the morphology of flat areas, that are inconspicuous in the standard endoscopic view. Superficial adenocarcinoma often has the morphology of a slightly elevated or sessile lesion, but may also be present in flat areas.

2 With Magnification and Image-Processing Techniques

When the standard endoscopic image in the segment with columnar metaplasia is negative for discrete abnormalities (color or irregular surface), high resolution magnifying endoscopy may detect abnormal microstructure patterns in completely flat zones with low or high grade intraepithelial neoplasia. Those flat areas display an irregular pattern in the size of the epithelial crests (Figures **87**, **88**, **91 – 95**, **99**, **100**) and in the superficial vascular network (Figures **89**, **96**). Features highly suggestive of neoplasia include an abrupt change in the average size of the epithelial crests (from large to small), with an irregular and distorted pattern, and the presence of areas with an amorphous surface. The surface pattern in magnifying endoscopy is similar to that observed in stereomicroscopy in the operative specimen (Figure **103**). Therefore, magnification contributes to the detection of neoplastic lesions which were not accessible to the standard view. In a recent series, magnification with indigo carmine proved fairly reliable in the prediction of high grade intraepithelial neoplasia in areas with a distorted and irregular pattern. On the other hand there is poor reliability for distinguishing between the normal and low grade intraepithelial neoplasia.

In summary, magnifying endoscopy improves the detection and characterization of intraepithelial neoplasia in columnar neoplasia in the esophagus or at the cardia, in the following cases: zones with an amorphous surface or irregular and distorted architecture can confidently be attributed to neoplasia. Meanwhile, more studies with histological verification are required to assess full reliability. This may lead to the replacement of the time-consuming protocol of random biopsies.

VI Histopathological Verification

Histological confirmation of columnar metaplasia is based on biopsy samples obtained in the esophagus and at the EGJ, and on the analysis of resected specimens [144 – 158].

1 Endoscopic Biopsies in the Esophagus

A systematic protocol for randomly obtained biopsies (the Seattle protocol), is recommended as good practice in the exploration of CLE [146,149,155], because the image obtained with a standard endoscope will fail to demonstrate intestinal metaplasia or

This document was downloaded for personal use only. Unauthorized distribution is strictly prohibited.

even intraepithelial neoplasia in the absence of discrete irregularities. The protocol includes four-quadrant biopsies, at each centimeter length in the segment of metaplasia. Unfortunately, this time-consuming and costly procedure is not completely reliable because the samples check only a small fraction of the target area. To complement the multiple random biopsies, samples from specific targets are also required for areas with a suspect surface pattern. The size of the tissue samples has been debated; the claimed superiority of jumbo biopsies has been challenged in the USA, and also in a multicenter German trial aimed at detection of intestinal metaplasia in the distal esophagus. The published American guidelines do not specify a particular technique for endoscopy surveillance biopsy.

Nowadays, magnification with image processing opens a new era in the endoscopic exploration of CLE with intestinal metaplasia. A pending question is whether the guidelines recommending multiple random biopsies will be out of date in the near future.

The multiple samples collected according to the abovementioned biopsy protocol should be placed in containers that allow the topographic identification of the targeted samples and of the different levels of random biopsy samples The stratification of the risk of cancer (from very low to confirmed) is based on the interpretation of tissue samples [144,150,156] which requires, in all litigious situations, a second reading by an experienced pathologist. As a rule, chronic inflammation is present in columnar metaplasia and litigious situations arise regarding the distinction between chronic inflammatory changes and low grade intraepithelial neoplasia. The analysis of the pathologist aims to detect intestinal metaplasia in tissue samples obtained from forceps biopsies (Figure **55**), which should be classified as complete (type I) or incomplete (type II or III) and intraepithelial neoplasia. The revised version of the Vienna classification [145] includes five categories: 1, negative for intraepithelial neoplasia; 2, indefinite for intraepithelial neoplasia; 3, low grade intraepithelial neoplasia (equivalent to adenoma or dysplasia): 4, high grade (noninvasive or invasive) intramucosal neoplasia (Figures **84**, **85**); and 5, submucosal carcinoma. Category 4 is subdivided into four groups: 4 – 1, adenoma or dysplasia; 4 – 2, noninvasive carcinoma; 4 – 3, suspicious for invasive carcinoma; and 4 – 4, intramucosal carcinoma. Multiple foci of neoplasia in the Barrett's esophagus are frequent and the extent of high grade noninvasive neoplasia does not predict the presence of unsuspected adenocarcinoma at another site in the esophagus.

2 *Endoscopic Biopsies at the EGJ*

At the EGJ, increased attention should be given to histological verification when the SCJ is slightly misplaced. Short columnar tongues extending into the proximal esophagus should always be biopsied. Similarly the cardiac mucosa should be biopsied when small abnormalities of the surface suggest early neoplastic changes. Errors in the precise site of the target biopsy result in erroneous interpretations.

In the gastric cardia, the presence of intestinal metaplasia in biopsies targeted just distal to the SCJ, has a very low relevance to a risk of cancer. On the other hand, visible palisade vessels distal to the SCJ suggest that there is a very short segment of CLE. The presence of intestinal metaplasia at this site has a higher relevance to the risk of cancer.

3 *Analysis of Mucosectomy Specimens with Neoplasia*

After endoscopic mucosectomy, the specimens should be oriented, pinned and stretched on cardboard in the endoscopy unit. For lesions located at the EGJ, particularly if there was a sliding hiatal hernia, the distinction between adenocarcinoma developed in the distal esophagus from a very short segment of columnar metaplasia or developed in the gastric cardia from the gastric mucosa is often uncertain. When the neoplastic area is totally surrounded by incomplete intestinal metaplasia, the esophageal origin is confirmed.

The depth of invasion into the mucosa is evaluated in a single layer ("m") because the lamina propria is an integral component of the mucosa, mixed with the epithelial component. Assessment of invasion into the submucosa ("sm") which is not resected completely as far as the muscularis propria is difficult, but critical for estimation of the risk of nodal metastases. In the absence of qualitative indices of poor prognosis (tumor grade, images of vascular invasion, tumor budding), a micrometric measure in microns of the depth of invasion from the lower limit of the muscularis mucosae is the most precise method. The empirical cutoff limit of invasion, accepted by Japanese pathologists for the safety of local treatment in the stomach, is 500 microns. The same figure is acceptable for adenocarcinoma in the esophagus. After pathological examination, mucosectomy specimens with superficial neoplasia are classified as pT1 m or pT1sm.

4 *Analysis of Surgically Resected Specimens with Neoplasia*

In surgically resected specimens, the depth of invasion in the submucosa is classified either qualitatively (mild or massive submucosal invasion) or by the micrometric measurement, using the cutoff limit of 500 microns proposed by Japanese pathologists. Residual areas with intestinal metaplasia can be found in the tumor (Figure **101**).

In specimens that have been surgically resected at the EGJ, the digestive wall is available in full thickness and the anatomic junction of the esophagus can be determined on the basis of the position of esophageal proper glands. Based on the position of the center of the tumor with respect to the EGJ, the tumor can be placed into one of the three categories proposed by Siewert [96].

5 *The Role of Biomarkers*

Molecular biomarkers (cyclins, P53, K 67, ploidy, etc) have been proposed to predict the outcome in patients who do not yet have any cancer. The problem is whether they reliably predict the risk of cancer; overall they are still considered to be less useful than the interpretation of conventional slides by a trained pathologist [148,151,153,157,158]. The mutation of the *TP53* gene predicts the outcome only if the mutation is analyzed by DNA sequencing. Flow cytometry has a limited usefulness in selecting, from patients who do not have high grade noninvasive neoplasia, the subset of patients who have an increased risk of progression to cancer. Variations of the cytokeratin phenotypes have been analyzed in the progression of neoplasia. Carcinogenesis is associated with the increased expression of phenotypes CK

This document was downloaded for personal use only. Unauthorized distribution is strictly prohibited.

4,10,13,14,17 in squamous carcinoma and with the increased expression of phenotypes CK 8,18,19 in adenocarcinomas. In tumors arising from a sector with the bi-directional phenotype, both types of cytokeratins may persist: adenocarcinoma in CLE with intestinal metaplasia gains the cytokeratins of columnar cells while retaining those of the squamous epithelium. A similar situation has been described in adenocarcinomas in the epithelial line of the junction of the cervix in women.

VII Screening

1 Screening for Esophageal Adenocarcinoma

There is no proven benefit for the endoscopic screening of asymptomatic persons in the population to detect high grade invasive or early noninvasive intramucosal neoplasia; the incidence of adenocarcinoma in the esophagus is too low. This might change in the future if the trend for increasing incidence is sustained. Preliminary results from small series raise the possibility of screening of individuals at increased risk of developing columnar metaplasia and adenocarcinoma based on inherited genes.

2 Screening for Columnar Metaplasia in the Esophagus

A significant proportion of persons with CLE are asymptomatic [159–162]. The overall benefit of screening for the presence of intestinal metaplasia in the esophagus would be small, because there is no established effective prevention of the risk of cancer. The pharmacological (acid inhibition) or mechanical (surgical) control of acid secretion has not been shown to decrease this risk, nor the endoscopic destruction of the segment with metaplasia. There is some experimental evidence that anti-inflammatory medication (aspirin and COX-2 inhibitors) may prevent deterioration to cancer; however the side effects of treatment may overcome the benefit in prevention.

Patient identification, or case finding, refers to performance of endoscopy in order to detect columnar metaplasia in the esophagus of selected patients over the age of 40, with symptoms of gastroesophageal reflux disease (GERD), or with other risk factors. It is clear that a program restricted to symptomatic patients would detect less than half of the high risk patients. There is limited evidence on unsedated transnasal endoscopy and capsule endoscopy as possible modalities for screening in the future.

VIII Surveillance

Surveillance refers to endoscopy scheduled at regular intervals, independently of symptoms in those patients who do not have cancer, with the aim of detecting high grade intraepithelial neoplasia or cancer with improved prognosis [163–168]. Procedures in surveillance protocols, should be performed with the same standard of care as those in the index endoscopy, using high resolution video endoscopes. While endoscopic screening relates to the prevalence of adenocarcinoma, surveillance relates to the incidence of cancer in the premalignant condition.

Surveillance is justified in patients with a increased risk of developing a cancer. This applies to columnar metaplasia with intestinal metaplasia in the esophagus which is a premalignant condition. There is still debate about whether a short segment of columnar metaplasia without intestinal metaplasia at the EGJ warrants surveillance. Finally, intestinal metaplasia in the gastric cardiac mucosa is not classified as a premalignant condition because the risk is too low, and surveillance is not justified. Surveillance is required in patients in whom a premalignant lesion (low grade or high grade intraepithelial neoplasia) has been detected previously, either in the esophagus or at the EGJ.

1 Surveillance in Patients without Intraepithelial Dysplasia

The overall burden of esophageal adenocarcinoma in the population with CLE with intestinal metaplasia is not high, and consideration should be given regarding the allocation of resources for screening. As stated in the proceedings of the AGA Chicago Workshop, there is no evidence in the literature to support the benefit of generalized surveillance protocols in patients having CLE with intestinal metaplasia [4]. Examinations performed at 3- to 5-year intervals in persons with an average risk have been proposed to be cost-effective. However there are no good prospective studies, similar, for instance, to the American National Polyp Study for colonic surveillance, that assess the validity of surveillance intervals. Surveillance protocols after the index endoscopy, should rely on assessment and stratification of the risk. The current risks for cancer are based on the patient's age, gender, race, clinical symptoms and health status, smoking habits, and length of the metaplastic segment [165]. Biomarkers in tissue samples are not ready for clinical use to predict outcome. A recent study conducted in the Netherlands attempted to select the patients who would benefit from a surveillance protocol [165]: no benefit could be expected for 85% of the 335 patients included in a 5-year follow-up study. The reasons were either a poor health status (advanced age or severe concurrent disease) or a prediction of low risk (young age, female sex).

The following guidelines can be recommended for general application:

- Factors justifying a surveillance protocol are male sex; a prolonged symptomatic history of GERD; continuous smoking; and presence of a peptic stricture or a ulcer at endoscopy.
- As yet there is no proof of the benefit of surveillance protocols in persons at low risk; however the case-by-case situation of clinical practice may lead to different attitudes, taking in account the psychology of the individuals concerned.

2 Surveillance in Patients with Intraepithelial Neoplasia

Indefinite or low grade intraepithelial neoplasia. Patients with indefinite or low grade intraepithelial neoplasia at the index endoscopy have medical therapy with a proton pump inhibitor for a period of 3 months before repeat endoscopy. It may be necessary to increase therapy to ensure that there is optimal reflux control. Further management is dependent on histological improvement. It is important that at least two consecutive examinations reveal no dysplastic change. Surveillance can then be decreased to 2-year intervals and the patient should continue treatment with a proton pump inhibitor. If low grade intraepithelial neoplasia persists, continued intensive control of reflux is necessary and should be confirmed with appropriate investigations. Endoscopic and biopsy surveillance should continue at 1-year intervals.

High grade intraepithelial neoplasia. Initially the diagnosis of high grade intraepithelial neoplasia should be confirmed by further biopsies and the opinion of a second expert pathologist. The diagnosis may have profound management implications. If any

This document was downloaded for personal use only. Unauthorized distribution is strictly prohibited.

doubt remains, then the endoscopy is repeated immediately and the biopsy protocol must be rigorous, with 1-cm, four-quadrant sampling [155]. Adequate time for obtaining large and multiple specimens must be given. The areas with neoplasia must be documented to determine their extent and distribution. Full staging investigations include computed tomography (CT) scan of the chest and abdomen and endoluminal ultrasound. Patients will fall into one of several categories with implicit management recommendations.

For patients having a focal area of high grade intraepithelial neoplasia, the alternatives are as follows:

- If they have a low operative risk, a long life expectancy, and other risk factors for the development of an adenocarcinoma in the esophagus (male sex, continuous smoking, etc), they should be considered for esophagectomy.
- If they have a high operative risk, they should be treated with endoscopic mucosal resection (EMR), allowing full histological verification and continued surveillance, with further mucosal resection if necessary. The complete area can be treated with endoscopic mucosal ablation with thermal, photodynamic, or ultrasonic methods.
- Then, all of these patients require full reflux control with permanent proton pump inhibitor therapy, and continuing endoscopic surveillance at 6-monthly intervals during the first years.

For patients having persistent, multiple focal neoplasia, with a focal area of high grade intraepithelial neoplasia, the alternatives are as follows:

- If they have a low operative risk and a long life expectancy, then surgical resection should be considered. The surgical approach may be transthoracic or transhiatal. The latter approach may be very suitable for patients with disease that is only mucosal. It is important that all columnar-lined esophagus is resected. Extensive lymphadenectomy is not necessary since there is no invasive cancer. The mortality of the procedure must be less than 5%.
- If the operative mortality and morbidity is expected to be prohibitive, they should receive endoscopic mucosal ablation, removing all the neoplastic and metaplastic epithelium. These patients then require permanent proton pump inhibitor therapy with confirmation of acid reflux control, and lifelong endoscopic surveillance with comprehensive biopsy protocols.

Acknowledgments

The following experts provided endoscopic and histopathologic images from their own series for this work: J.J. Bergman (Amsterdam), M.I. Canto (Baltimore), T. Endo (Sapporo), R. H. Hawes (Charleston), G. Herrmann (Ludwigsburg) Y. Hoshihara (Tokyo), H. Inoue (Yokoyama), E. Jaramillo (Stockholm), M. Jung (Mainz), T. Kouzu (Chiba), C.J. Lightdale (New York), H. Makuuchi (Kanagawa), J.F. Rey (St Laurent du Var), R. Riddell (Toronto), R.E. Sampliner (Tucson), P. Sharma (Kansas City), K. Takubo (Tokyo), H. Tajiri (Tokyo), G. and H. Watanabe (Niigata).

This collaborative study was supported by an unrestricted Educational Grant from the Olympus Medical Systems Corporation. The study is based on a Workshop held in Paris on December 11 – 12, 2004 and a Workshop held during a meeting of the Japan Gastroenterological Endoscopy Society in Tokyo in May 2005, and was endorsed and supported by OMGE and OMED.

References

1 Falk GW. Barrett's esophagus. Gastroenterology 2002; 122: 1569 – 1591
2 Shaheen NJ. Advances in Barrett's esophagus and esophageal adenocarcinoma. Gastroenterology 2005; 128: 1554 – 1566
3 Jankowski JA, Harrison RF, Perry I et al. Barrett's metaplasia. Lancet 2000; 356: 2079 – 2085
4 Sharma P, McQuaid K, Dent J et al. A critical review of the diagnosis and management of Barrett's esophagus: the AGA Chicago Workshop. Gastroenterology 2004; 127: 310 – 330
5 Aoki T. Kawaura Y, Kouzu T, et al. Report of the Research Committee on the Definition of Barrett's Esophagus (Epithelium) [in Japanese]. In: Sugimachi K, editor. Reports of the research committees of The Japanese Society for Esophageal Diseases. Chiba: Japanese Society of Esophageal Diseases ; 2000: 20 – 23
6 Axon A, Lambert R, Robaszkiewicz et al. The Second European Endoscopy Forum (Sintra, Portugal 17 – 18 June 1999): twenty questions on the esophagogastric junction. Endoscopy 2000; 32: 411 – 418
7 Bombeck CT, Dillard DH, Nyhus LM. Muscular anatomy of the gastroesophageal junction and role of phrenoesophageal ligament: autopsy study of sphincter mechanism. Ann Surg 1966; 164: 643 – 654
8 de Carvalho CA. Studies on the microscopic anatomy of the veins in the esophagogastric transition zone in man. Rev Hosp Clin Fac Med Sao Paulo 1966; 21: 113 – 128
9 de Carvalho CA. Sur l'angio-architecture veineuse de la zone de transition esophago-gastrique et son interprétation fonctionnelle. Acta Anat 1966; 64: 126 – 162
10 Makuuchi H. Knack and pitfalls of esophageal surgery [in Japanese]. Tokyo: Bunkodo, 2003
11 Chandrasoma PT, Der R, Ma Y et al. Histology of the gastroesophageal junction: an autopsy study. Am J Surg Pathol 2000; 24: 402 – 409
12 Hoshihara Y, Kogure T, Fukuchi S et al. Endoscopic observation of longitudinal vessels at the lower esophagus and its clinical significance [in Japanese]. Gastroenterol Endosc 1986; 28: 941 – 946
13 Kilgore SP, Ormsby AH, Gramlich TL et al. The gastric cardia: fact or fiction? Am J Gastroenterol 2000; 95: 921 – 924
14 Sarbia M, Donner A, Gabbert HE. Histopathology of the gastroesophageal junction: a study on 36 operation specimens. Am J Surg Pathol 2002; 26: 1207 – 1212
15 Takubo K, Arai T, Sawabe M et al. Structures of the normal esophagus and Barrett's esophagus. Esophagus 2003; 1: 37 – 47
16 Takubo K, Vieth M, Honma N et al. Ciliated surface in the esophagogastric junction zone: a precursor of Barrett's mucosa or ciliated pseudostratified metaplasia? Am J Surg Pathol 2005; 29: 211 – 217
17 Watanabe H, Komukai S, Ochiai A. Histopathological features of Barrett's esophagus. Stomach Intestine 1999; 34: 123 – 132
18 Wallner B, Sylvan A, Janunger KG. Endoscopic assessment of the "Z-line" (squamocolumnar junction) appearance: reproducibility of the ZAP classification among endoscopists. Gastrointest Endosc 2002; 55: 65 – 69
19 Offerhaus GJ, Correa P, van Eeden S et al. Report of an Amsterdam working group on Barrett esophagus. Virchows Arch 2003; 443: 602 – 608
20 Sharma P, Morales TG, Sampliner RE. Short segment Barrett's esophagus – the need for standardization of the definition and of endoscopic criteria. Am J Gastroenterol 1998; 93: 1033 – 1036
21 Jones TF, Sharma P, Daaboul B et al. Yield of intestinal metaplasia in patients with suspected short-segment Barrett's esophagus (SSBE) on repeat endoscopy. Dig Dis Sci 2002; 47: 2108 – 2111
22 Sharma P. Short segment Barrett esophagus and specialized columnar mucosa at the gastroesophageal junction. Mayo Clin Proc 2001; 76: 331 – 334

This document was downloaded for personal use only. Unauthorized distribution is strictly prohibited.

[23] Spechler SJ. The role of gastric carditis in metaplasia and neoplasia at the gastroesophageal junction. Gastroenterology 1999; 117: 218 – 228
[24] Takubo K, Nixon JM, Jass JR. Ducts of esophageal glands proper and Paneth cells in Barrett's esophagus: frequency in biopsy specimens. Pathology 1995; 27: 315 – 317
[25] Takubo K, Vieth M, Aryal G et al. Islands of squamous epithelium and their surrounding mucosa in columnar lined esophagus: a pathognomonic feature of Barrett's esophagus. Hum Pathol 2005; 36: 269 – 274
[26] Takubo K. Pathology of the esophagus. Tokyo: Educa, 2000
[27] Long JD, Orlando RC. Esophageal submucosal glands: structure and function. Am J Gastroenterol 1999; 94: 2818 – 2824
[28] Azuma N, Endo T, Arimura Y et al. Prevalence of Barrett's esophagus and expression of mucin antigens detected by a panel of monoclonal antibodies in Barrett's esophagus and esophageal adenocarcinoma in Japan. J Gastroenterol 2000; 35: 583 – 592
[29] Cameron AJ, Zinsmeister AR, Ballard DJ et al. Prevalence of columnar lined Barrett's esophagus. Comparison of population based clinical and autopsy findings. Gastroenterology 1990; 99: 918 – 922
[30] Chak A, Lee T, Kinnard MF et al. Familial aggregation of Barrett's oesophagus, oesophageal adenocarcinoma, and oesophagogastric junctional adenocarcinoma in Caucasian adults. Gut 2002; 51: 323 – 328
[31] Conio M, Cameron AJ, Romero Y et al. Secular trends in the epidemiology and outcome of Barrett's oesophagus in Olmsted County, Minnesota. Gut 2001; 48: 304 – 309
[32] Connor MJ, Weston AP, Mayo MS et al. The prevalence of Barrett's esophagus and erosive esophagitis in patients undergoing upper endoscopy for dyspepsia in a VA population. Dig Dis Sci 2004; 49: 920 – 924
[33] Gerson LB, Shetler K, Triadafilopoulos G. Prevalence of Barrett's esophagus in asymptomatic individuals. Gastroenterology 2002; 123: 461 – 467
[34] Hongo M, Shoji T. Epidemiology of reflux disease and CLE in East Asia. J Gastroenterol 2003; 38 Suppl 15: 25 – 30
[35] Lee JI, Park H, Jung HY et al. Prevalence of Barrett's esophagus in an urban Korean population: a multicenter study. J Gastroenterol 2003; 38: 23 – 27
[36] Locke GRIII, Talley NJ, Fett SL et al. Prevalence and clinical spectrum of gastroesophageal reflux: a population based study in Olmsted County, Minnesota. Gastroenterology 1997; 112: 1448 – 1456
[37] Rex DK, Cummings OW, Shaw M et al. Screening for Barrett's esophagus in colonoscopy patients with and without heartburn. Gastroenterology 2003; 125: 1670 – 1677
[38] Toruner M, Soykan I, Ensari A et al. Barrett's esophagus: prevalence and its relationship with dyspeptic symptoms. J Gastroenterol Hepatol 2004; 19: 535 – 540
[39] Cheng KK, Sharp l, McKinney PA et al. A case/control study of oesophageal adenocarcinoma in women: a preventable disease. Br J Cancer 2000; 83: 127 – 132
[40] Chaves P, Pereira AD, Cruz C et al. Recurrent columnar-lined esophageal segments-study of the phenotypic characteristics using intestinal markers. Dis Esophagus 2002; 15: 282 – 286
[41] Corey KE, Schmitz SM, Shaheen NJ. Does a surgical antireflux procedure decrease the incidence of esophageal adenocarcinoma in Barrett's esophagus? A meta-analysis. Am J Gastroenterol 2003; 98: 2390 – 2394
[42] Fletcher J, Wirz A, Henry E et al. Studies of acid exposure immediately above the gastro-oesophageal squamocolumnar junction: evidence of short segment reflux. Gut 2004; 53: 168 – 173
[43] Fletcher J, Wirz A, Young J et al. Unbuffered highly acidic gastric juice exists at the gastroesophageal junction after a meal. Gastroenterology 2001; 121: 775 – 783
[44] Gammon MD, Schoenberg JB, Ahsan H et al. Tobacco, alcohol, and socioeconomic status and adenocarcinomas of the esophagus and gastric cardia. J Natl Cancer Inst 1997; 89: 1277 – 1284
[45] Kumagai H, Mukaisho K, Sugihara H et al. Cell kinetic study on histogenesis of Barrett's esophagus using rat reflux model. Scand J Gastroenterol 2003; 38: 687 – 692
[46] Lagergren J, Bergstrom R, Nyren O. Association between body mass and adenocarcinoma of the esophagus and gastric cardia. Ann Intern Med 1999; 130: 883 – 890
[47] Lagergren J, Bergstrom R, Adami HO et al. Association between medications that relax the lower esophageal sphincter and risk for esophageal adenocarcinoma. Ann Intern Med 2000; 133: 165 – 175
[48] Lagergren J, Bergstrom R, Lindgren A et al. Symptomatic gastroesophageal reflux as a risk factor for esophageal adenocarcinoma. N Engl J Med 1999; 340: 825 – 831
[49] Peitz U, Vieth M, Pross M et al. Cardiac-type metaplasia arising in the remnant esophagus after cardia resection. Gastrointest Endosc 2004; 59: 810 – 817
[50] Zhang ZF, Kurtz C, Marshall JR. Cigarette smoking and esophageal and gastric cardia adenocarcinoma. J Natl Cancer Inst 1997; 89: 1247 – 1249
[51] Boch JA, Shields HM, Antonioli DA et al. Distribution of cytokeratin markers in Barrett's specialized columnar epithelium. Gastroenterology 1997; 112: 760 – 765
[52] Brittan M, Wright NA. Gastrointestinal stem cells. J Pathol 2002; 197: 492 – 509
[53] Chen YY, Wang HH, Antonioli DA et al. Significance of acid-mucin-positive nongoblet columnar cells in the distal esophagus and gastroesophageal junction. Hum Pathol 1999; 30: 1488 – 1495
[54] Couvelard A, Cauvin JM, Goldfain D et al. Cytokeratin immunoreactivity of intestinal metaplasia at normal oesophagogastric junction indicates its aetiology. Gut 2001; 49: 761 – 766
[55] El-Zimaity HM, Ramchatesingh J, Saeed MA et al. Gastric intestinal metaplasia: subtypes and natural history. J Clin Pathol 2001; 54: 679 – 683
[56] El-Zimaity HM, Graham DY. Cytokeratin subsets for distinguishing Barrett's esophagus from intestinal metaplasia in the cardia using endoscopic biopsy specimens. Am J Gastroenterol 2001; 96: 1378 – 1382
[57] Glickman JN, Chen YY, Wang HH et al. Phenotypic characteristics of a distinctive multilayered epithelium suggests that it is a precursor in the development of Barrett's esophagus. Am J Surg Pathol 2001; 25: 569 – 578
[58] Glickman JN, Shahsafaei A, Odze RD. Mucin core peptide expression can help differentiate Barrett's esophagus from intestinal metaplasia of the stomach. Am J Surg Pathol 2003; 27: 1357 – 1365
[59] Hirota WK, Loughney TM, Lazas DJ et al. Specialized intestinal metaplasia, dysplasia and cancer of the esophagus and esophagogastric junction: prevalence and clinical data. Gastroenterology 1999; 116: 227 – 285
[60] Lambert R, Hainaut P, Parkin DM. Premalignant lesions of the esophagogastric mucosa. Semin Oncol 2004; 31: 489 – 512
[61] Latchford A, Eksteen B, Jankowski J. The continuing tale of cytokeratins in Barrett's mucosa: as you like it. Gut 2001; 49: 746 – 747
[62] Mohammed IA, Streutker CJ, Riddell RH. Utilization of cytokeratins 7 and 20 does not differentiate between Barrett's esophagus and gastric cardiac intestinal metaplasia. Mod Pathol 2002; 15: 611 – 616
[63] Ormsby AH, Goldblum JR, Rice TW et al. Cytokeratin subsets can reliably distinguish Barrett's esophagus from intestinal metaplasia of the stomach. Hum Pathol 1999; 30: 288 – 294
[64] Salo JA, Kivilaakso EO, Kiviluoto TA et al. Cytokeratin profile suggests metaplastic epithelial transformation in Barrett's oesophagus. Ann Med 1996; 28: 305 – 309
[65] Takubo K, Honma N, Arai T. Multilayered epithelium in Barrett's esophagus. Am J Surg Pathol 2001; 25: 1460 – 1461
[66] Trudgill NJ, Suvarna SK, Kapur KC et al. Intestinal metaplasia at the squamocolumnar junction in patients attending for diagnostic gastroscopy. Gut 1997; 41: 585 – 589
[67] Wallner B, Sylvan A, Stenling R et al. The Z-line appearance and prevalence of intestinal metaplasia among patients without symptoms or endoscopical signs indicating gastroesophageal reflux. Surg Endosc 2001; 15: 886 – 889
[68] Wallner B, Sylvan A, Janunger KG et al. Immunohistochemical markers for Barrett's esophagus and associations to esophageal Z-line appearance. Scand J Gastroenterol 2001; 36: 910 – 915
[69] Auvinen MI, Sihvo EI, Ruohtula T et al. Incipient angiogenesis in Barrett's epithelium and lymphangiogenesis in Barrett's adenocarcinoma. J Clin Oncol 2002; 20: 2971 – 2979
[70] Buskens CJ, Sivula A, van Rees BP et al. Comparison of cyclooxygenase 2 expression in adenocarcinomas of the gastric cardia and distal oesophagus. Gut 2003; 52: 1678 – 1683
[71] Eksteen JA, Scott PA, Perry I et al. Inflammation promotes Barrett's metaplasia and cancer: a unique role for TNFalpha. Eur J Cancer Prev 2001; 10: 163 – 166
[72] Fennerty MB, Triadafilopoulos G. Barrett's-related esophageal adenocarcinoma: is chemoprevention a potential option? Am J Gastroenterol 2001; 96: 2302 – 2305

This document was downloaded for personal use only. Unauthorized distribution is strictly prohibited.

[73] Jenkins GJ, Doak SH, Griffiths AP et al. Early p53 mutations in nondysplastic Barrett's tissue detected by the restriction site mutation (RSM) methodology. Br J Cancer 2003; 88: 1271 – 1276
[74] Kumagai Y, Toi M, Inoue H. Dynamism of tumour vasculature in the early phase of cancer progression: outcomes from oesophageal cancer research. Lancet Oncol 2002; 3: 604 – 610
[75] Moriya A, Grant J, Mowat C et al. In vitro studies indicate that acid catalysed generation of N-nitrosocompounds from dietary nitrate will be maximal at the gastro-oesophageal junction and cardia. Scand J Gastroenterol 2002; 37: 253 – 261
[76] Sonnenberg A, Fennerty MB. Medical decision analysis of chemoprevention against esophageal adenocarcinoma. Gastroenterology 2003; 124: 1758 – 1766
[77] Wilson KT, Fu S, Ramanujam KS et al. Increased expression of inducible nitric oxide synthase and cyclooxygenase-2 in Barrett's esophagus and associated adenocarcinomas. Cancer Res 1998; 58: 2929 – 2934
[78] Wilson KT. Angiogenic markers, neovascularization and malignant deformation of Barrett's esophagus. Dis Esophagus 2002; 15: 16 – 21
[79] Pohl H, Welch HG. The role of overdiagnosis and reclassification in the marked increase of esophageal adenocarcinoma incidence. J Natl Cancer Inst 2005; 97: 142 – 146
[80] Botterweck AAM, Shouten LJ, Volovics A et al. Trends in incidence of adenocarcinoma of the oesophagus and gastric cardia in ten European countries. Internat J Epidemiol 2000; 29: 645 – 654
[81] Brown LM, Devesa SS. Epidemiologic trends in esophageal and gastric cancer in the United States. Surg Oncol Clin N Am 2002; 11: 235 – 256
[82] Bytzer P, Christensen PB, Damkier P et al. Adenocarcinoma of the esophagus and Barrett's esophagus: a population-based study. Am J Gastroenterol 1999; 94: 86 – 91
[83] Parkin DM, Whelan SL, Ferlay J et al. Cancer incidence in five continents. IARC publ. no. 155. Lyon: IARC press, 2002. [Distributed by Oxford University Press]
[84] SEER. Incidence Public US Database 1973 – 1995. National Cancer Institute. Bethesda, Maryland, USA: National Institutes of Health, 1998
[85] Vizcaino AP, Moreno V, Lambert R et al. Time trends incidence of both major histologic types of esophageal carcinomas in selected countries 1973 – 1995. Int J Cancer 2002; 99: 860 – 888
[86] Ye W, Chow WH, Lagergren J et al. Risk of adenocarcinomas of the esophagus and gastric cardia in patients with gastroesophageal reflux diseases and after antireflux surgery. Gastroenterology 2001; 121: 1286 – 1293
[87] Zheng T, Mayne ST, Holford TR et al. Time trend and age-period-cohort effects on incidence of esophageal cancer in Connecticut 1935 – 89. Cancer Causes Control 1992; 3: 481 – 492
[88] Cameron AJ, Souto EO, Smyrk TC. Small adenocarcinomas of the esophagogastric junction: association with intestinal metaplasia and dysplasia. Am J Gastroenterol 2002; 97: 1375 – 1380
[89] El-Serag HB, Mason AC, Petersen N et al. Epidemiological differences between adenocarcinoma of the oesophagus and adenocarcinoma of the gastric cardia in the USA. Gut 2002; 50: 368 – 372
[90] Ekstrom AM, Signorello MB, Hansson LE et al. Evaluating gastric cancer misclassification: a potential explanation for the rise in cardia cancer incidence. J Natl Cancer Inst 1999; 91: 786 – 790
[91] Ichikura T, Ogawa T, Kawabata T et al. Is adenocarcinoma of the gastric cardia a distinct entity independent of subcardial carcinoma? World J Surg 2003; 27: 334 – 338
[92] Nakamura T, Ide H, Eguchi R et al. Adenocarcinoma of the esophagogastric junction: a summary of responses to a questionnaire on adenocarcinoma of the esophagus and the esophagogastric junction in Japan. Dis Esophagus 2002; 15: 219 – 225
[93] Okabayashi T, Gotoda T, Kondo H. Early carcinoma of the gastric cardia in Japan: is it different from that in the West? Cancer 2000; 89: 2555 – 2559
[94] Ormsby AH, Goldblum JR, Rice TW et al. The utility of cytokeratin subsets in distinguishing Barrett's-related oesophageal adenocarcinoma from gastric adenocarcinoma. Histopathology 2001; 38: 307 – 311
[95] Sharma P, Weston AP, Morales T et al. Relative risk of dysplasia for patients with intestinal metaplasia in the distal oesophagus and in the gastric cardia. Gut 2000; 46: 9 – 13
[96] Stein HJ, Feith M, Siewert JR. Cancer of the esophagogastric junction. Surg Oncol 2000; 9: 35 – 41
[97] Taniere P, Borghi-Scoazec G, Saurin JC et al. Cytokeratin expression in adenocarcinomas of the esophagogastric junction: a comparative study of adenocarcinomas of the distal esophagus and of the proximal stomach. Am J Surg Pathol 2002; 26: 1213 – 1221
[98] Taniere P, Martel-Planche G, Maurici D et al. Molecular and clinical differences between adenocarcinomas of the esophagus and of the gastric cardia. Am J Pathol 2001; 158: 33 – 40
[99] Watanabe H, Tanabe T, Yagi K et al. Comparison of carcinoma of the esophagogastric junction with Barrett's esophageal cancer from the aspect of structural development [in Japanese]. Stomach Intestine 2001; 36: 634 – 650
[100] Anderson LA, Murray LJ, Murphy SJ et al. Mortality in Barrett's oesophagus: results from a population based study. Gut 2003; 52: 1081 – 1084
[101] Drewitz DJ, Sampliner RE, Garewal HS. The incidence of adenocarcinoma in Barrett's esophagus: a prospective study of 170 patients followed 4.8 years. Am J Gastroenterol 1997; 92: 212 – 215
[102] Eckardt VF, Kanzler G, Bernhard G. Life expectancy and cancer risk in patients with Barrett's esophagus: a prospective controlled investigation. Am J Med 2001; 111: 33 – 37
[103] Rudolph RE, Vaughan TL, Storer BE et al. Effect of segment length on risk for neoplastic progression in patients with Barrett esophagus. Ann Intern Med 2000; 132: 612 – 620
[104] Shaheen NJ, Crosby MA, Bozymski EM et al. Is there publication bias in the reporting of cancer risk in Barrett's esophagus? Gastroenterology 2000; 119: 333 – 338
[105] van der Burgh A, Dees J, Hop WCJ et al. Oesophageal cancer is an uncommon cause of death in patients with Barrett's esophagus. Gut 1996; 39: 5 – 8
[106] Guelrud M, Herrera I, Essenfeld H et al. Intestinal metaplasia of the gastric cardia: a prospective study with enhanced magnification endoscopy. Am J Gastroenterol 2002; 97: 584 – 589
[107] Guelrud M, Herrera I, Essenfeld H et al. Enhanced magnification endoscopy: a new technique to identify specialized intestinal metaplasia in Barrett's esophagus. Gastrointest Endosc 2001; 53: 559 – 565
[108] Guelrud M, Ehrlich EE. Endoscopic classification of Barrett's esophagus. Gastrointest Endosc 2004; 59: 58 – 65
[109] Hamamoto Y, Endo T, Nosho K et al. Usefulness of narrow-band imaging endoscopy for diagnosis of Barrett's esophagus. J Gastroenterol 2004; 39: 14 – 20
[110] Hurlstone DP. Barrett's esophagus: a role for high-resolution magnification chromoendoscopy? J Gastroenterol Hepatol 2002; 17: 633 – 635
[111] Inoue H, Kumagai Y, Yoshida T et al. High magnification endoscopic diagnosis of the superficial esophageal cancer. Dig Endosc 2000; 12 (Suppl): S32 – S35
[112] Kiesslich R, Hahn M, Herrmann G et al. Screening for specialized columnar epithelium with methylene blue: chromoendoscopy in patients with Barrett's esophagus and a normal control group. Gastrointest Endosc 2001; 53: 47 – 52
[113] Kumagai Y, Inoue H, Nagai K et al. Magnifying endoscopy, stereoscopic microscopy, and the microvascular architecture of superficial esophageal carcinoma. Endoscopy 2002; 34: 369 – 375
[114] Lambert R, Rey JF, Sankaranarayanan R. Magnification and chromoscopy with the acetic acid test. Endoscopy 2003; 35: 437 – 445
[115] Meining A, Ott R, Becker I et al. The Munich Barrett follow up study: suspicion of Barrett's oesophagus based on either endoscopy or histology only – what is the clinical significance? Gut 2004; 53: 1402 – 1407
[116] Meining A, Rosch T, Kiesslich R et al. Inter- and intra-observer variability of magnification chromoendoscopy for detecting specialized intestinal metaplasia at the gastroesophageal junction. Endoscopy 2004; 36: 160 – 164
[117] Mokhashi MS, Wildi SM, Glenn TF et al. A prospective, blinded study of diagnostic esophagoscopy with a superthin, stand-alone, battery-powered esophagoscope. Am J Gastroenterol 2003; 98: 2383 – 2389
[118] Ragunath K, Krasner N, Raman VS et al. A randomized, prospective cross-over trial comparing methylene blue-directed biopsy and conventional random biopsy for detecting intestinal metaplasia and dysplasia in Barrett's esophagus. Endoscopy 2003; 35: 998 – 1003
[119] Saeian K, Staff DM, Vasilopoulios S et al. Unsedated transnasal endoscopy accurately detects Barrett's metaplasia and dysplasia. Gastrointest Endosc 2002; 56: 472 – 478
[120] Sharma P, Weston AP, Topalovski M et al. Magnification chromoendoscopy for the detection of intestinal metaplasia and dysplasia in Barrett's oesophagus. Gut 2003; 52: 24 – 27

This document was downloaded for personal use only. Unauthorized distribution is strictly prohibited.

[121] Shibuya K, Hoshino H, Chiyo M et al. High magnification bronchovideoscopy combined with narrow band imaging could detect capillary loops of angiogenic squamous dysplasia in heavy smokers at high risk for lung cancer. Thorax 2003; 58: 989 – 995
[122] Sorbi D, Gostout CJ, Henry J et al. Unsedated small-caliber esophagogastroduodenoscopy (EGD) versus conventional EGD: a comparative study. Gastroenterology 1999; 117: 1301 – 1307
[123] Toyoda H, Rubio C, Befrits R et al. Detection of intestinal metaplasia in distal esophagus and esophagogastric junction by enhanced-magnification endoscopy. Gastrointest Endosc 2004; 59: 15 – 21
[124] Yao K, Oishi T. Microgastroscopic findings of mucosal microvascular architecture as visualized by magnifying endoscopy. Dig Endosc 2001; 13 (Suppl): S27 – S33
[125] Yasuda K. Clinical use of high resolution and high magnification endoscopy for upper gastrointestinal lesions. Dig Endosc 2001; 13 (Suppl): S36 – S39
[126] Yoshida T, Inoue H, Usui S et al. Narrow-band imaging system with magnifying endoscopy for superficial esophageal lesions. Gastrointest Endosc 2004; 59: 288 – 295
[127] Canto MI, Setrakian S, Willis JE et al. Methylene blue staining of dysplastic and nondysplastic Barrett's esophagus: an in vivo and ex vivo study. Endoscopy 2001; 33: 391 – 400
[128] Endo T, Awakawa T, Takahashi H et al. Classification of Barrett's epithelium by magnifying endoscopy. Gastrointest Endosc 2002; 55: 641 – 647
[129] Gono K, Obi T, Yamaguchi M et al. Appearance of enhanced tissue features in narrow-band endoscopic imaging. J Biomed Optics 2004; 9: 568 – 577
[130] Muto M, Katada C, Sano Y et al. Narrow band imaging: a new diagnostic approach to visualize angiogenesis in superficial neoplasia. Clin Gastroenerol Hepatol 2005; 3: S16 – S20
[131] Connor MJ, Sharma P. Chromoendoscopy and magnification endoscopy for diagnosing esophageal cancer and dysplasia. Thorac Surg Clin 2004; 14: 87 – 94
[132] Brand S, Wang TD, Schomacker KT et al. Detection of high-grade dysplasia in Barrett's esophagus by spectroscopy measurement of 5-aminolevulinic acid-induced protoporphyrin IX fluorescence. Gastrointest Endosc 2002; 56: 479 – 487
[133] Endlicher E, Knuechel R, Hauser T et al. Endoscopic fluorescence detection of low and high grade dysplasia in Barrett's oesophagus using systemic or local 5-aminolaevulinic acid sensitisation. Gut 2001; 48: 314 – 319
[134] Georgakoudi I, Jacobson BC, van Dam J et al. Fluorescence, reflectance, and light-scattering spectroscopy for evaluating dysplasia in patients with Barrett's esophagus. Gastroenterology 2001; 120: 1620 – 1629
[135] Kara MA, Peters FP, ten Kate FJW et al. Endoscopic video autofluorescence imaging may improve the detection of early neoplasia in patients with Barrett's esophagus. Gastrointest Endosc 2005; 61: 679 – 685
[136] Wallace MB, Perelman LT, Backman V et al. Endoscopic detection of dysplasia in patients with Barrett's esophagus using light-scattering spectroscopy. Gastroenterology 2000; 119: 677 – 682
[137] Buskens CJ, Westerterp M, Lagarde SM. Prediction of appropriateness of local endoscopic treatment for high-grade dysplasia and early adenocarcinoma by EUS and histopathologic features. Gastrointest Endosc 2004; 60: 703 – 710
[138] Murata Y, Napoleon B, Odegaard S. High-frequency endoscopic ultrasonography in the evaluation of superficial esophageal cancer. Endoscopy 2003; 35: 429 – 435
[139] Owens MM, Kimmey MB. The role of endoscopic ultrasound in the diagnosis and management of Barrett's esophagus. Gastrointest Endosc Clin N Am 2003; 13: 325 – 334
[140] Scotiniotis IA, Kochman ML, Lewis JD et al. Accuracy of EUS in the evaluation of Barrett's esophagus and high-grade dysplasia or intramucosal carcinoma. Gastrointest Endosc 2001; 54: 689 – 696
[141] Brand S, Poneros JM, Bouma BE et al. Optical coherence tomography in the gastrointestinal tract. Endoscopy 2000; 32: 796 – 803
[142] Cilesiz I, Fockens P, Kerindongo R et al. Comparative optical coherence tomography imaging of human esophagus: how accurate is localization of the muscularis mucosae? Gastrointest Endosc 2002; 56: 852 – 857
[143] The Paris endoscopic classification of superficial neoplastic lesions. Esophagus, stomach, and colon. Gastrointest Endosc 2003; 58 (Suppl 6): S3 – S43
[144] Alikhan M, Rex D, Khan A et al. The variable pathologic interpretation of columnar-lined esophagus by general pathologists in community practice. Gastrointest Endosc 1999; 50: 23 – 26
[145] Dixon MF. Gastrointestinal epithelial neoplasia: Vienna revisited. Gut 2002; 51: 130 – 131
[146] Haggitt RC. Barrett's esophagus, dysplasia, and adenocarcinoma. Hum Pathol 1994; 25: 982 – 993
[147] Japanese Society for Esophageal Diseases. Guidelines for the clinical and pathologic studies on carcinoma of the esophagus. 9th edn. Tokyo: Kanehara, 1999
[148] Jankowski JA, Wright NA, Meltzer SJ et al. Molecular evolution of the metaplasia – dysplasia – adenocarcinoma sequence in the esophagus. Am J Pathol 1999; 54: 965 – 973
[149] Levine DS, Blount PL, Rudolph RE et al. Safety of a systematic endoscopic biopsy protocol in patients with Barrett's esophagus. Am J Gastroenterol 2000; 95: 1152 – 1157
[150] Morales CP, Souza RF, Spechler SJ. Hallmarks of cancer progression in Barrett's oesophagus. Lancet 2002; 360: 1587 – 1589
[151] Ozawa S, Ando N, Kitagawa Y et al. Molecular alterations in Barrett's esophagus and adenocarcinoma [in Japanese]. Nippon Geka Gakkai Zasshi 1999; 100: 235 – 239
[152] Reid BJ, Blount PL, Rabinovitch PS. Biomarkers in Barrett's esophagus. Gastrointest Endosc Clin N Am 2003; 13: 369 – 397
[153] Reid BJ, Levine DS, Longton G et al. Predictors of progression to cancer in Barrett's esophagus: baseline histology and flow cytometry identify low- and high-risk patient subsets. Am J Gastroenterol 2000; 95: 1669 – 1676
[154] Reid BJ, Prevo LJ, Galipeau PC et al. Predictors of progression in Barrett's esophagus II: baseline 17p (p53) loss of heterozygosity identifies a patient subset at increased risk for neoplastic progression. Am J Gastroenterol 2001; 96: 2839 – 2848
[155] Reid BJ, Blount PL, Feng Z et al. Optimizing endoscopic biopsy detection of early cancers in Barrett's high-grade dysplasia. Am J Gastroenterol 2000; 95: 3089 – 3096
[156] Robert ME. Defining dysplasia in Barrett esophagus. J Clin Gastroenterol 2003; 36 (Suppl): S19 – S25
[157] Rudolph RE, Vaughan TL, Kristal AR et al. Serum selenium levels in relation to markers of neoplastic progression among persons with Barrett's esophagus. J Natl Cancer Inst 2003; 95: 750 – 757
[158] van der Woude CJ, Jansen PL, Tiebosch AT et al. Expression of apoptosis-related proteins in Barrett's metaplasia – dysplasia – carcinoma sequence: a switch to a more resistant phenotype. Hum Pathol 2002; 33: 686 – 692
[159] Inadomi JM, Sampliner R, Lagergren J et al. Screening and surveillance for Barrett esophagus in high-risk groups: a cost/utility analysis. Ann Intern Med 2003; 138: 176 – 186
[160] Shaheen NJ, Provenzale D, Sandler RS. Upper endoscopy as a screening and surveillance tool in esophageal adenocarcinoma: a review of the evidence. Am J Gastroenterol 2002; 97: 1319 – 1327
[161] Spechler SJ, Barr H. Review article: screening and surveillance of Barrett's oesophagus: what is a cost-effective framework? Aliment Pharmacol Ther 2004; 19 (Suppl 1): 49 – 53
[162] Corley DA, Levin TR, Habel LA et al. Surveillance and survival in Barrett's adenocarcinomas: a population-based study. Gastroenterology 2002; 122: 633 – 640
[163] Fennerty MB. Endoscopic diagnosis and surveillance of Barrett's esophagus. Gastrointest Endosc Clin N Am 2003; 13: 257 – 267
[164] Fountoulakis A, Zafirellis KD, Dolan K. Effect of surveillance of Barrett's oesophagus on the clinical outcome of oesophageal cancer. Br J Surg 2004; 91: 997 – 1003
[165] Gudlaugsdottir S, Blankenstein MV, Dees J et al. A majority of patients with Barrett oesophagus are unlikely to benefit from endoscopic cancer surveillance. Eur J Gastroenterol Hepatol 2001; 13: 639 – 645
[166] Jones TF, Sharma P, Daaboul B et al. Yield of intestinal metaplasia in patients with suspected short-segment Barrett's esophagus (SSBE) on repeat endoscopy. Dig Dis Sci 2002; 47: 2108 – 2111
[167] Sampliner RE. Practice Parameters Committee of the American College of Gastroenterology. Updated guidelines for the diagnosis, surveillance, and therapy of Barrett's esophagus. Am J Gastroenterol 2002; 97: 1888 – 1895
[168] Sonnenberg A, Soni A, Sampliner RE. Medical decision analysis of endoscopic surveillance of Barrett's oesophagus to prevent oesophageal adenocarcinoma. Aliment Pharmacol Ther 2002; 16: 41 – 50

This document was downloaded for personal use only. Unauthorized distribution is strictly prohibited.



Figure **1** Surgical specimen, esophagogastric region. At the squamocolumnar junction (SCJ) the squamous epithelium is strongly stained by the iodine/potassium iodide solution. The two types of epithelium overlap.

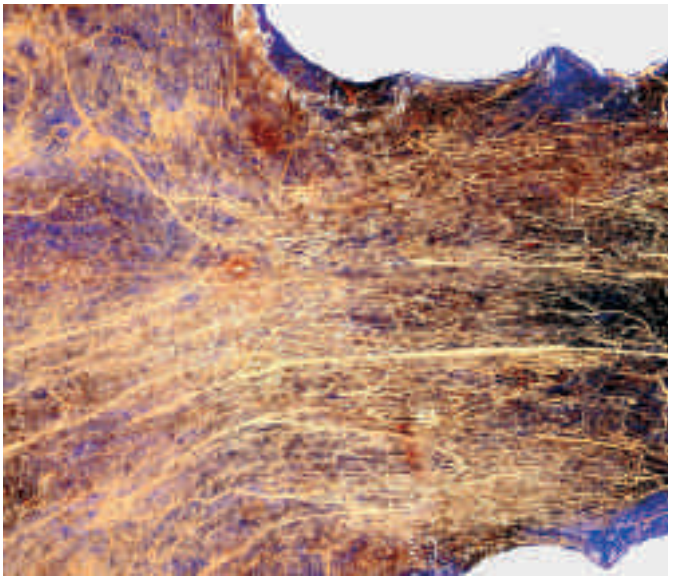

Figure **3** Surgical specimen, esophagogastric region. Palisaded longitudinal veins are seen in the mucosa of distal esophagus injected with Microfil (opaque silicone compound).

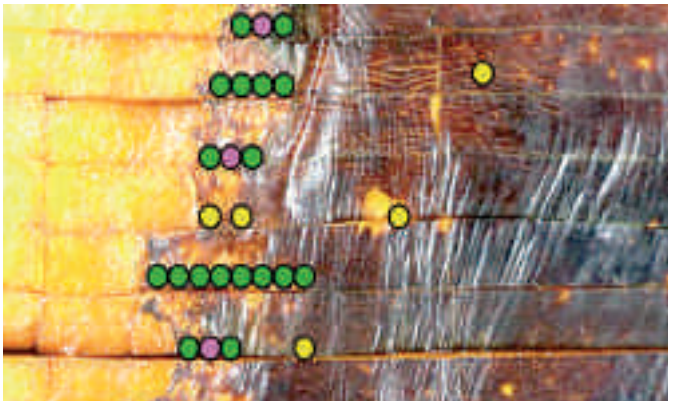

Figure **2** Surgical specimen, esophagogastric region, squamous epithelium stained by iodine/potassium iodide solution. Islands of esophageal cardiac mucosa are marked by dots: yellow, not exposed to the surface; green, hypertrophic; pink, exposed.

Figure **4** Surgical specimen, hematoxylin & eosin (H&E) stain, section of esophagogastric region. The gastric cardiac mucosa extends below the squamous epithelium. 1, the segment with overlap; 2, muscularis mucosae

This document was downloaded for personal use only. Unauthorized distribution is strictly prohibited.

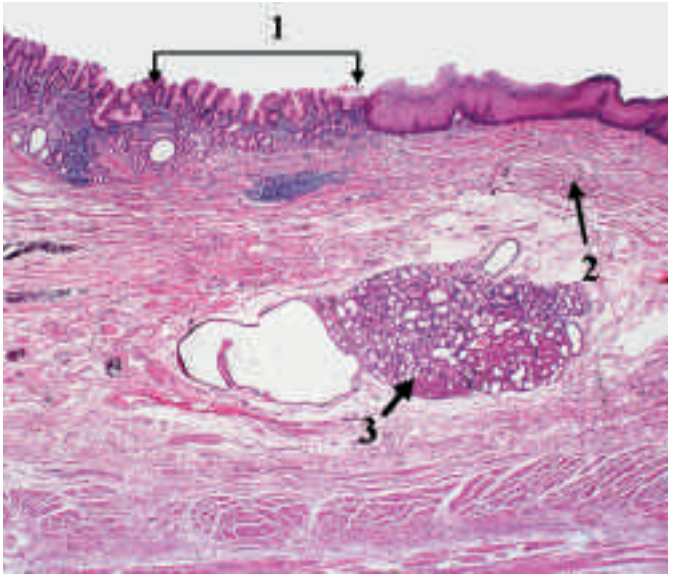

Figure **5** Surgical specimen, H&E stain, section of esophagogastric region. 1, short segment of gastric cardiac mucosa; 2, subsquamous muscularis mucosae; 3, esophageal proper gland in the submucosa, below the muscularis mucosae.

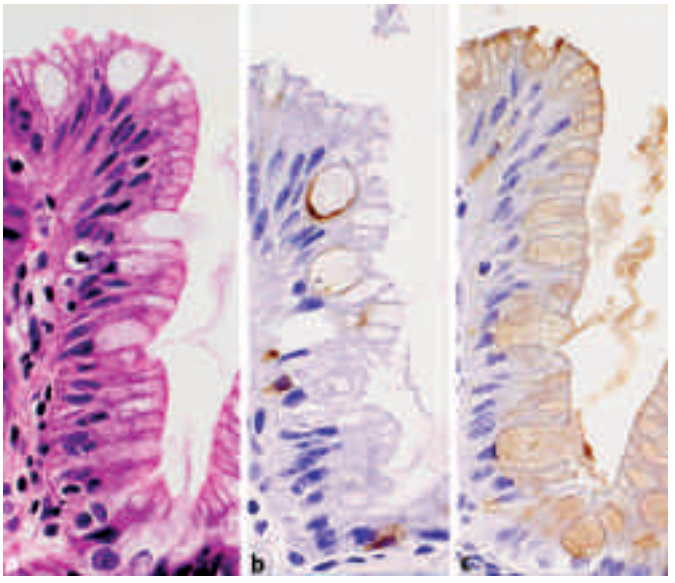

Figure **7** Histology. Intestinal metaplasia, complete, in gastric cardiac mucosa: **a** H&E stain; **b** mucin MUC 2 (goblet cells); **c** HGM (human gastric mucin) stain.

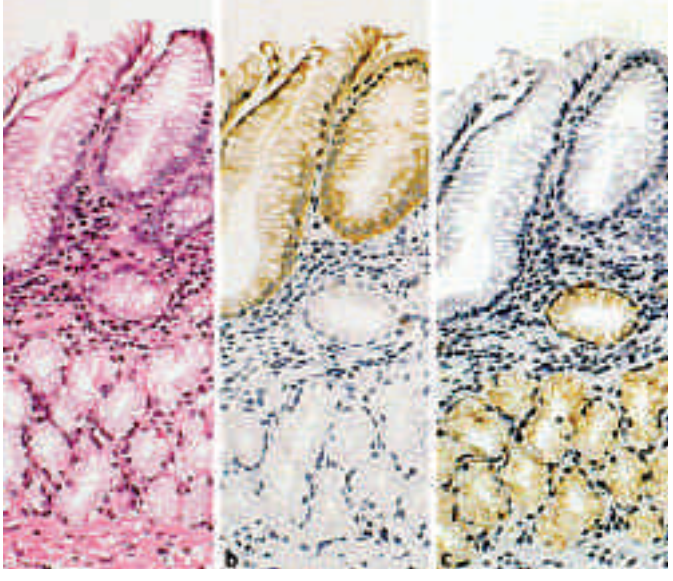

Figure **6** Histology. Gastric cardiac mucosa with foveolae and glands: **a** H&E stain; **b** mucin MUC 5AC; **c** mucin MUC 6.

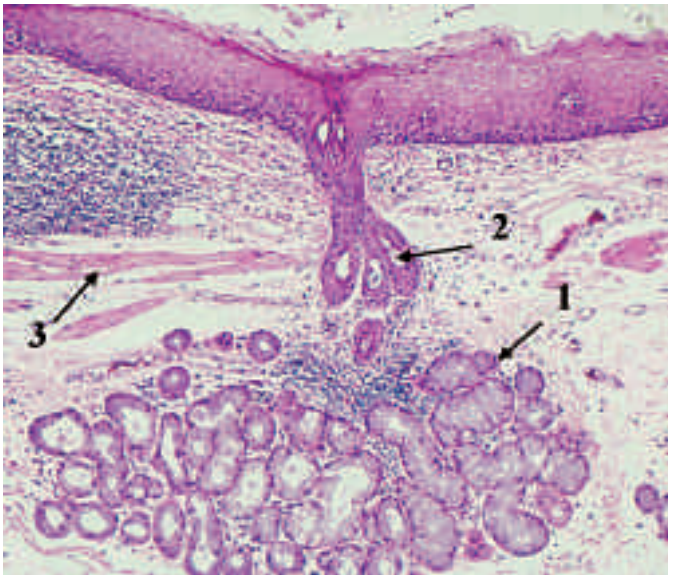

Figure **8** Surgical specimen, H&E stain. 1, esophageal gland proper, in the submucosa; 2, lumen of the excretory duct opening at the surface; 3, muscularis mucosae.

This document was downloaded for personal use only. Unauthorized distribution is strictly prohibited.

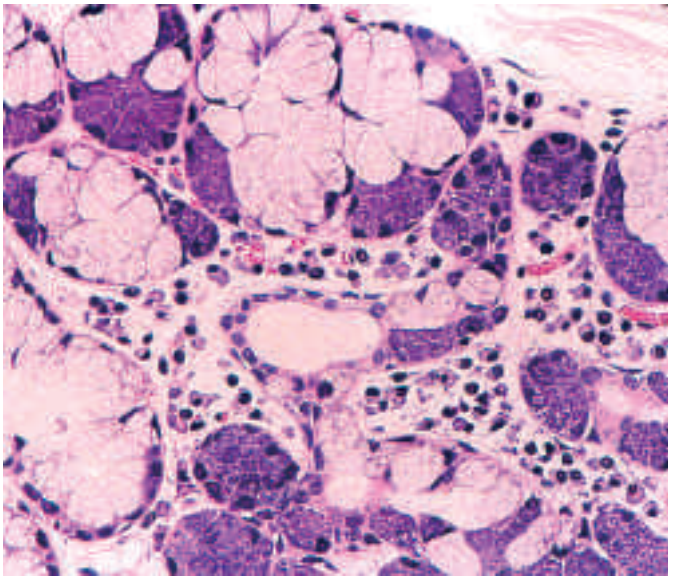

Figure **9** Histology, H&E stain. Heterogeneity of esophageal glands proper in the submucosa is seen, with serous cells being darkly stained and mucous cells unstained.

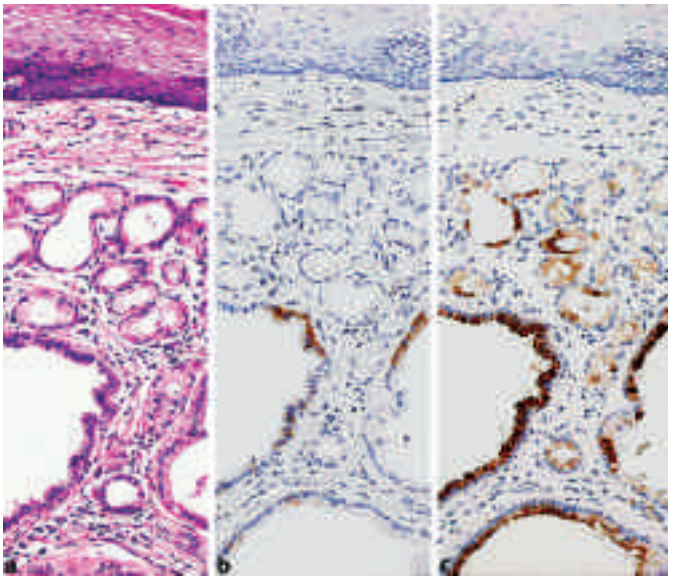

Figure **11** Histology, distal esophagus, nonexposed esophageal cardiac mucosa: **a** H&E stain; **b** mucin MUC 5AC; **c** HGM stain.

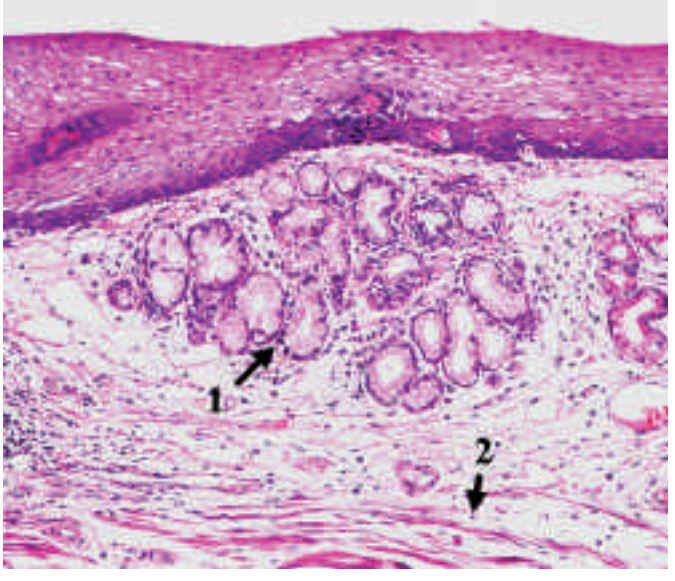

Figure **10** Surgical specimen, H&E stain, distal esophagus. 1, ectopic intramucosal and subsquamous esophageal cardiac mucosa, nonexposed in the lumen; 2, muscularis mucosae.

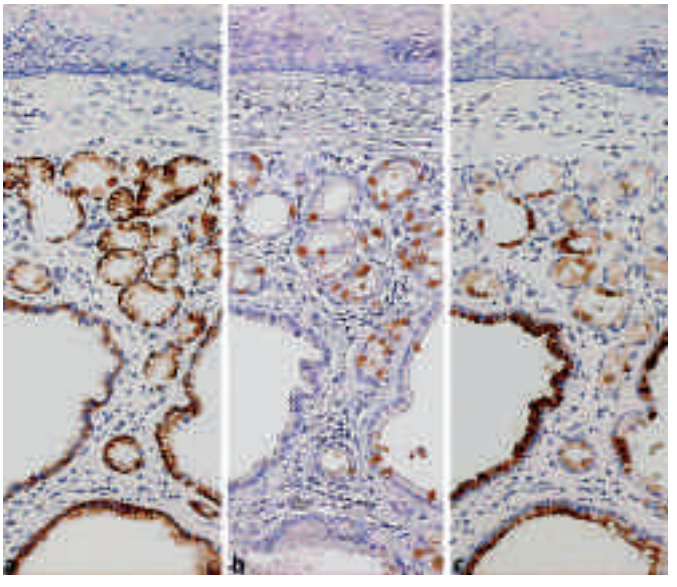

Figure **12** Histology, distal esophagus, nonexposed esophageal cardiac mucosa: **a** mucin MUC 6; **b** adenosine triphosphatase (ATPase) for oxyntic cells; **c** pepsinogen I.

This document was downloaded for personal use only. Unauthorized distribution is strictly prohibited.

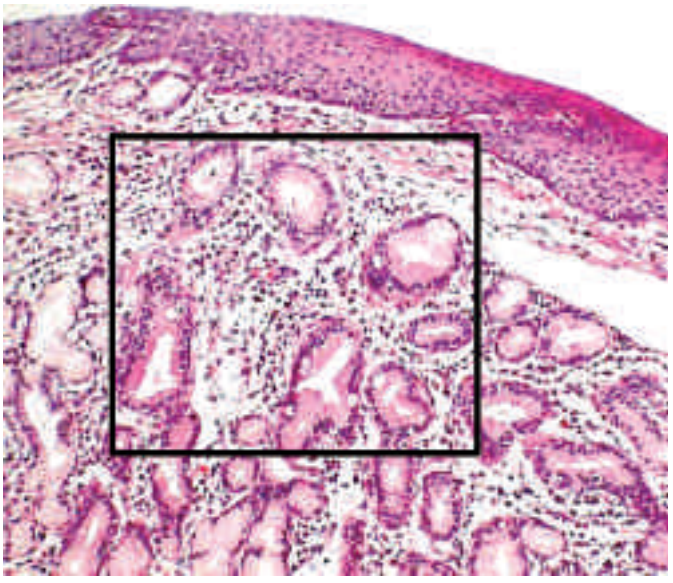

Figure **13** Surgical specimen, H&E stain. Ectopic intramucosal and subsquamous esophageal cardiac mucosa, nonexposed in the lumen.

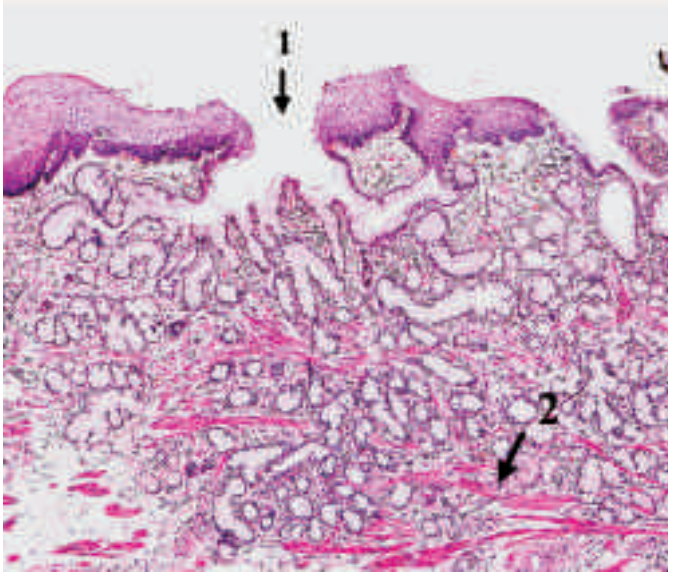

Figure **15** Surgical specimen, H&E stain, distal esophagus. Subsquamous esophageal cardiac mucosa: 1, formation of foveolae in the area exposed in the lumen; 2, muscularis mucosae.

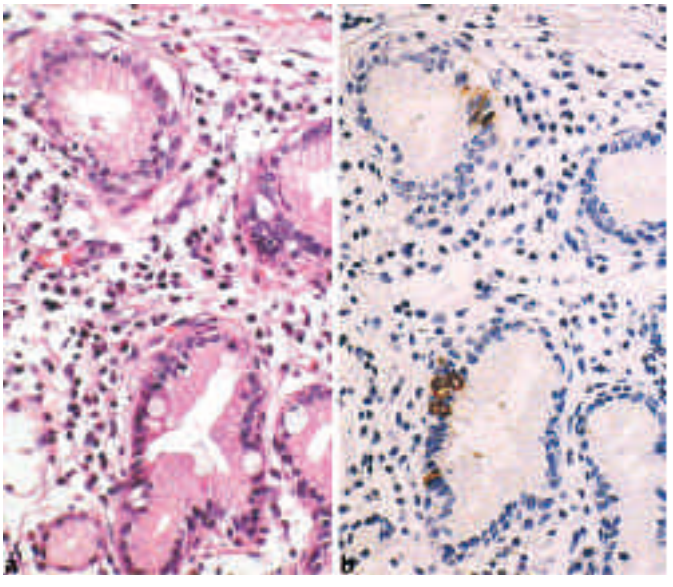

Figure **14** Surgical specimen, H&E stain. Enlarged view of the mucous glands framed in Figure **13**: **a** with H&E stain, scarce goblet cells are visible; **b** with mucin MUC-2, there is some positive stain for goblet cells.

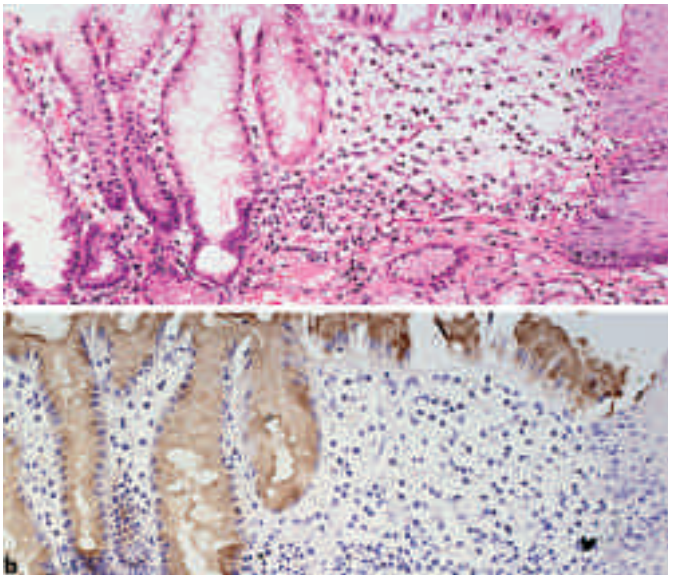

Figure **16** Surgical specimen, distal esophagus. Esophageal cardiac mucosa with foveolae, exposed in the lumen: **a** H&E stain; **b** HGM stain.

This document was downloaded for personal use only. Unauthorized distribution is strictly prohibited.

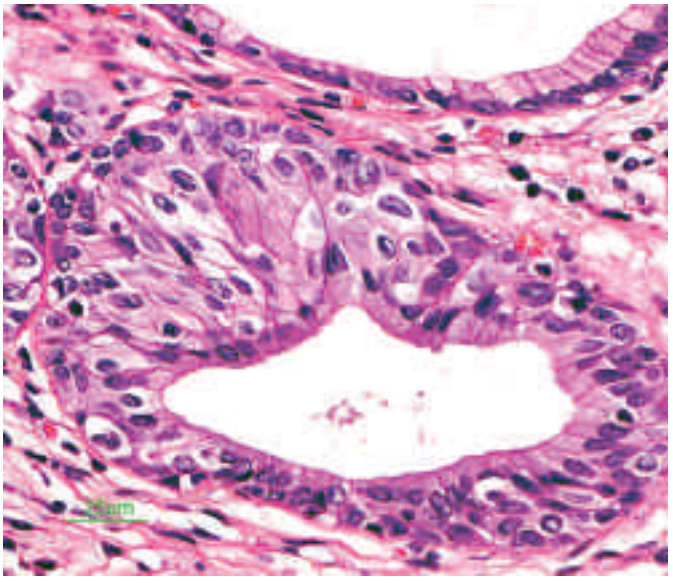

Figure **17** Surgical specimen, H&E stain, distal esophagus. An area of multilayered or metaplastic pseudostratified epithelium in an intramucosal gland.

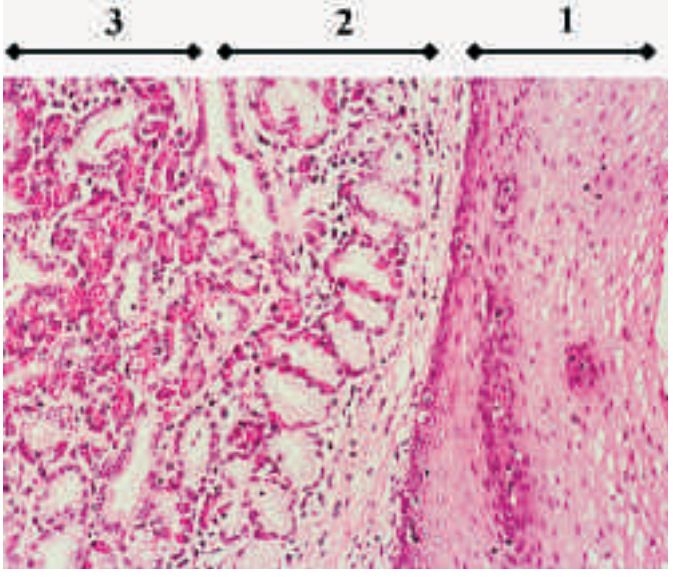

Figure **18** Surgical specimen, H&E stain, distal esophagus. Subsquamous esophageal cardiac mucosa (non exposed) with pancreatic metaplasia. 1, squamous epithelium; 2, mucous cells; 3, pancreatic metaplasia.

Figure **19** Endoscopy with a hood, without insufflation, standard technique. The proximal pole of the gastric folds (1) is visible above the hiatal pinch (2). There is a slight proximal slippage of the esophagogastric junction (EGJ).

Figure **20** Endoscopy with a hood, with insufflation, standard technique, same patient as in Figure **19**. The proximal pole of the gastric folds is not visible above the hiatal pinch (1).

Figure **21** Endoscopy, standard technique. The normal squamocolumnar junction (SCJ), without insufflation.

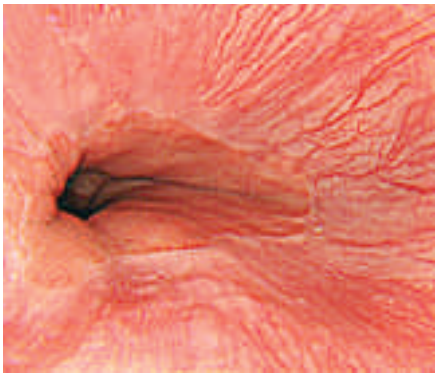

Figure **22** Endoscopy, standard technique. The visible path of intramucosal palisaded vessels at the EGJ begins in alignment with the SCJ.

This document was downloaded for personal use only. Unauthorized distribution is strictly prohibited.

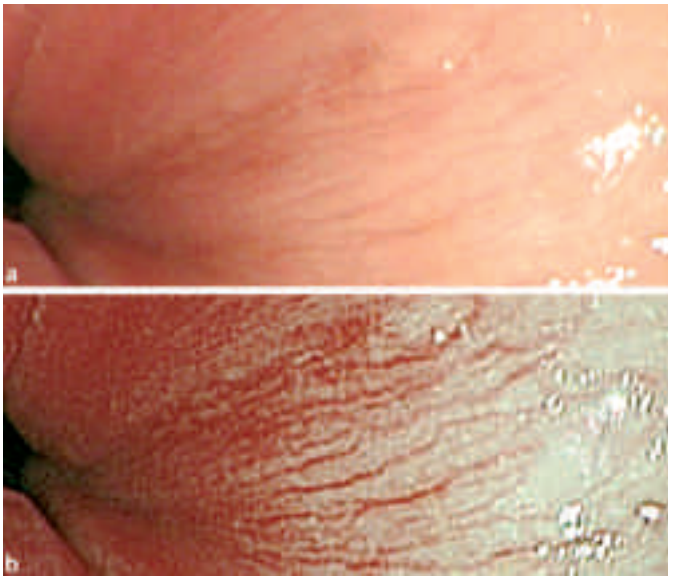

Figure **23** Endoscopy. Intramucosal palisaded vessels at the EGJ: **a** with the standard imaging technique, the vessels are slightly visible; **b** using the index of hemoglobin (IHb) technique, the vessels are sharply delineated.

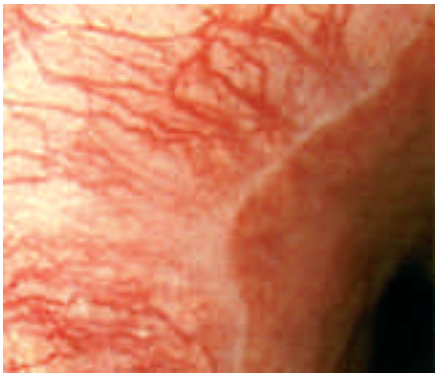

Figure **24** Endoscopy, IHb technique. There is enhanced contrast of intramucosal palisaded vessels at the EGJ.

Figure **25** Endoscopy with a hood, narrow-band imaging (NBI) technique. There is enhanced contrast of intramucosal palisaded vessels at the EGJ.

Figure **26** Endoscopy, with iodine–potassium iodide chromoscopy. At the EGJ, the SCJ is slightly ascended, with a scar suggesting healing from esophagitis.

Figure **27** Enlarged view of Figure **26**. The green line shows a segment with columnar metaplasia in the distal esophagus. The two rings show tiny islands of stained squamous epithelium corresponding to excretory ducts of esophageal glands proper.

Figure **28** Endoscopy, standard method. Intramucosal palisaded vessels are seen distal to the SCJ, suggesting that there is a very short segment of columnar metaplasia in the distal esophagus.

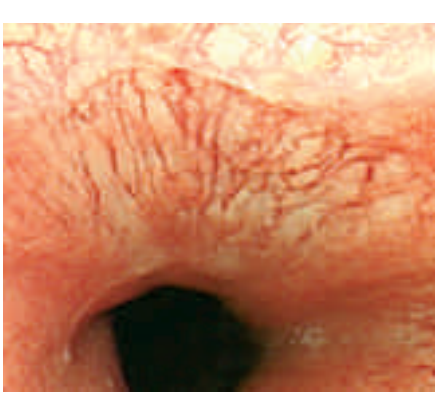

Figure **29** Endoscopy, IHb technique. Intramucosal palisaded vessels distal to the SCJ are seen.

This document was downloaded for personal use only. Unauthorized distribution is strictly prohibited.

Figure **30** Zoom endoscopy with hood, NBI technique. Intramucosal palisaded vessels distal to the SCJ are seen.

Figure **31** Endoscopy, standard technique. Intramucosal palisaded vessels can be seen at the upper esophageal sphincter of the esophagus.

Figure **32** Endoscopy, NBI technique. Intramucosal palisaded vessels are shown at the upper esophageal sphincter of the esophagus.

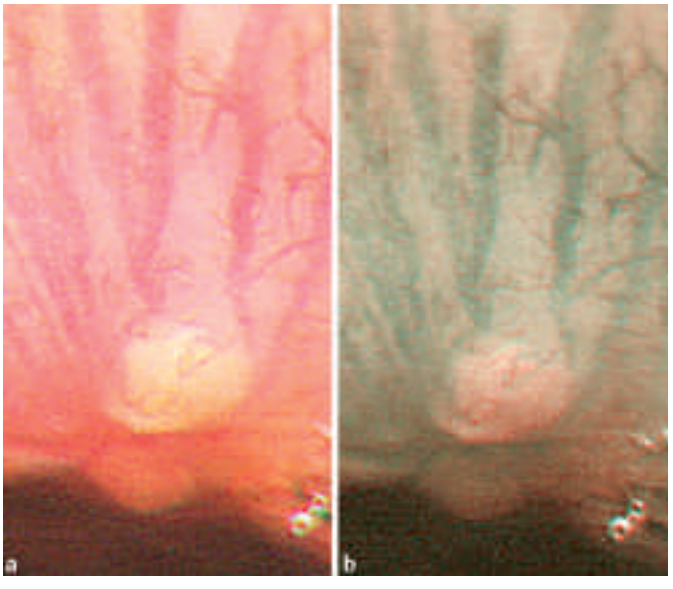

Figure **33** Zoom endoscopy. A hypertrophic subsquamous island of esophageal cardiac mucosa, proximal to the SCJ, seen with: **a** standard technique; **b** NBI technique.

Figure **34** Endoscopy with a hood, NBI technique. An island of exposed esophageal cardiac mucosa proximal to the SCJ (arrow), seen with: **a** no magnification; **b** zoom endoscopy. Similar patterns of oval crests are observed in the gastric and esophageal cardiac epithelium.

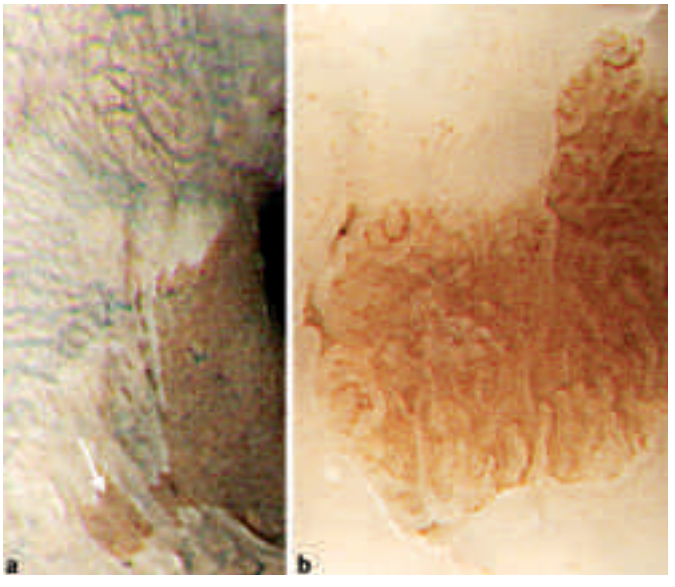

Figure **35** Endoscopy with hood, NBI technique. An island of exposed esophageal cardiac mucosa (arrow) proximal to the SCJ, seen with: **a** no magnification; **b** zoom endoscopy. Small dots in the squamous epithelium correspond to intrapapillary capillary loops.

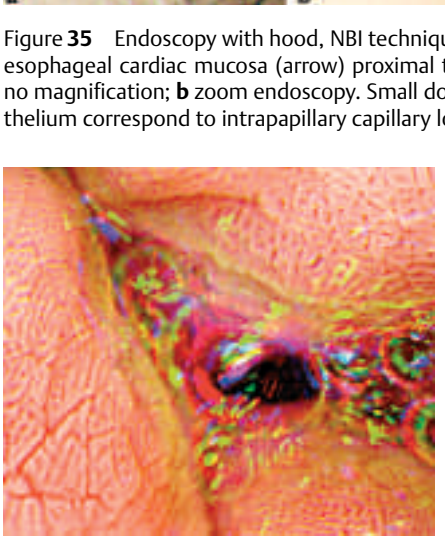

Figure **36** Zoom endoscopy, acetic acid chromoscopy. Gastric mucosa distal to the SCJ, with a pattern of pits and oval crests.

This document was downloaded for personal use only. Unauthorized distribution is strictly prohibited.

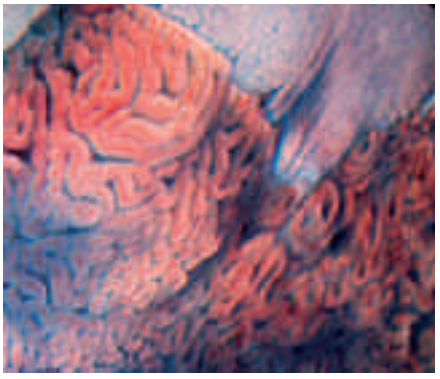

Figure **37** Zoom endoscopy, indigo carmine chromoscopy. Gastric mucosa distal to the SCJ, with a pattern of oval crests.

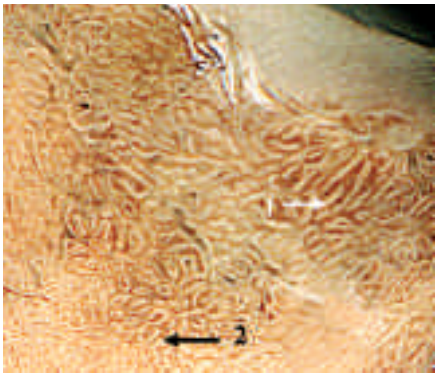

Figure **38** Zoom endoscopy, NBI technique. Gastric mucosa distal to the SCJ, with a pattern of oval crests. There is a progressive transition from cardiac type (1) to oxyntic type (2). The small dots in the squamous epithelium correspond to intrapapillary capillary loops.

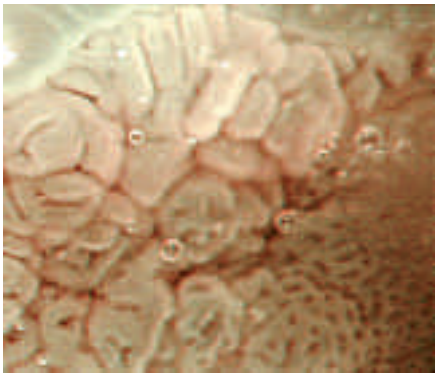

Figure **39** Zoom endoscopy, NBI technique. Gastric mucosa distal to the SCJ, with a pattern of oval crests. There is a sharp transition from the cardiac to the oxyntic type.

Figure **40** Zoom endoscopy, NBI technique. Carditis distal to the SCJ is seen, with the villous pattern of the gastric epithelium.

Figure **41** Zoom endoscopy, NBI technique: Carditis distal to SCJ, with a villous pattern. Histologically there is foveolar hyperplasia.

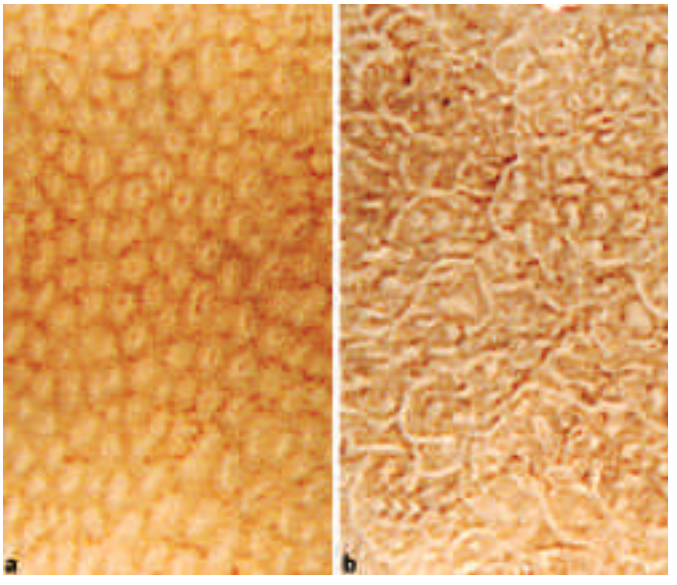

Figure **42** Zoom endoscopy, NBI technique. Oxyntic mucosa distal to the cardiac mucosa at the SCJ is shown: **a** a normal honeycomb pit pattern; **b** swollen, enlarged pits in *Helicobacter pylori* infection.

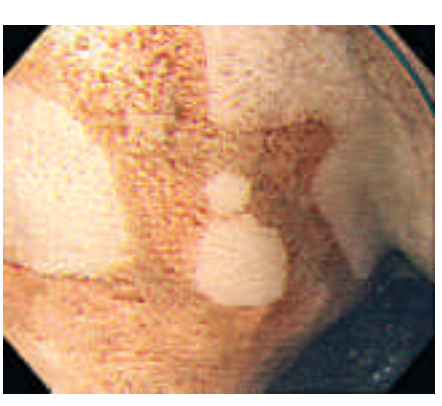

Figure **43** Zoom endoscopy with hood, NBI technique. Gastric mucosa distal to the SCJ shows a pattern of round pits surrounding an island of squamous epithelium. Small dots in the squamous epithelium correspond to intrapapillary capillary loops.

This document was downloaded for personal use only. Unauthorized distribution is strictly prohibited.

Figure **44** Zoom endoscopy with hood, NBI technique. Gastric mucosa distal to the SCJ shows a pattern of long oval crests.

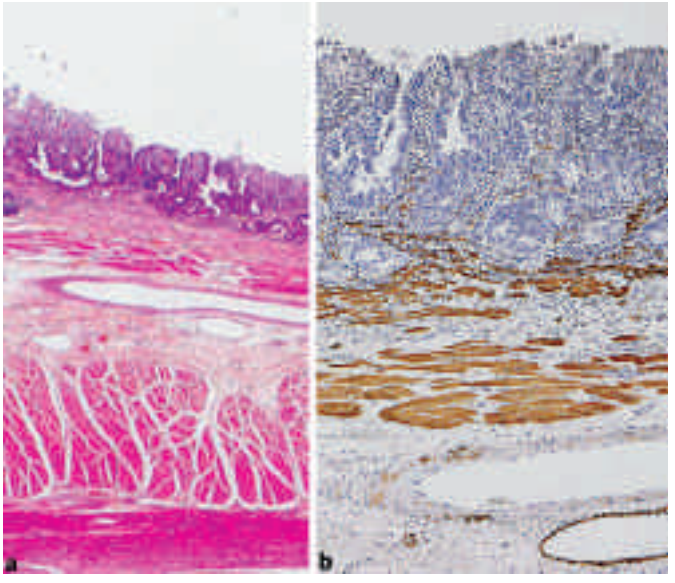

Figure **45** Surgical specimen. Adenocarcinoma in the esophagus: **a** H&E stain, full thickness of the esophageal wall; **b** smooth muscle antigen (SMA) stain of mucosa and submucosa, with a double-layered muscularis mucosae stained in brown.

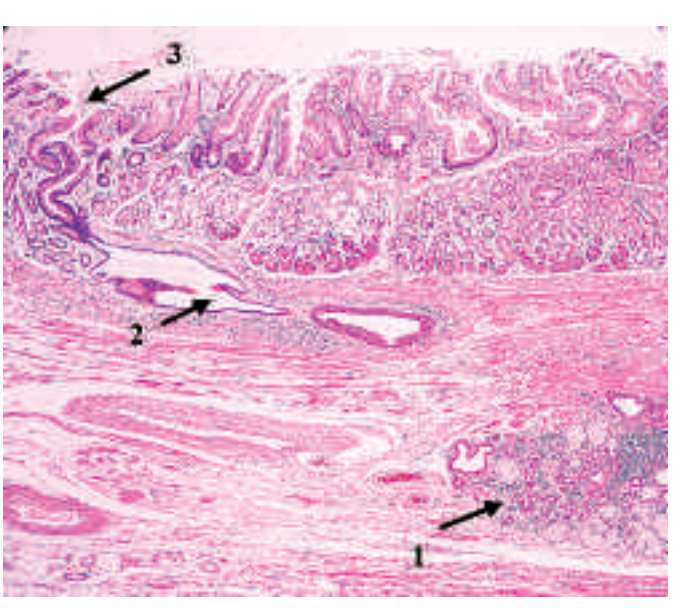

Figure **46** Surgical specimen, H&E stain. Distal esophagus with columnar metaplasia: 1, esophageal gland proper below the muscularis mucosae; 2, sections of the excretory duct; 3, luminal opening of excretory duct in a tiny island of squamous epithelium.

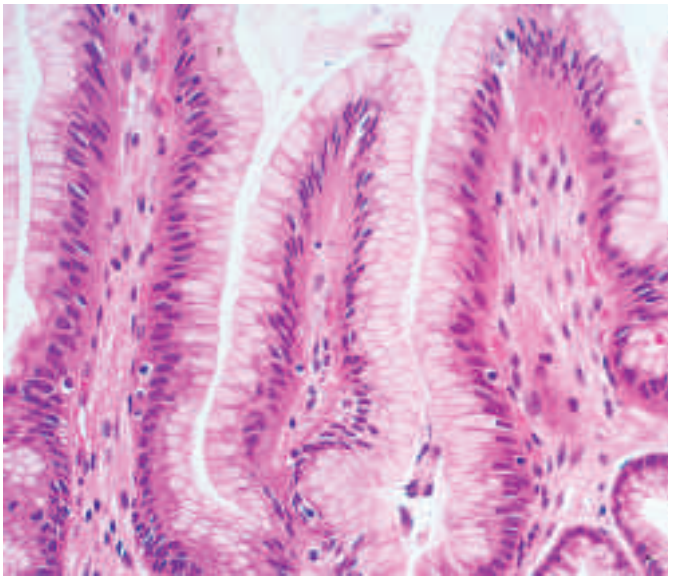

Figure **47** Histology, H&E stain. Columnar metaplasia in the esophagus: cardiac-type epithelium with foveolae.

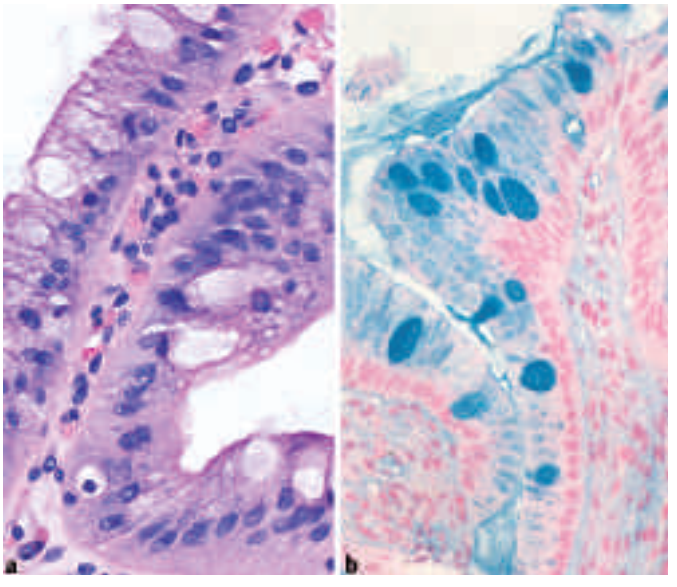

Figure **48** Histology. Columnar metaplasia in esophagus; intestinal metaplasia with goblet cells: **a** H&E stain; **b** alcian blue at pH 2.5, staining acid glycoproteins.

This document was downloaded for personal use only. Unauthorized distribution is strictly prohibited.

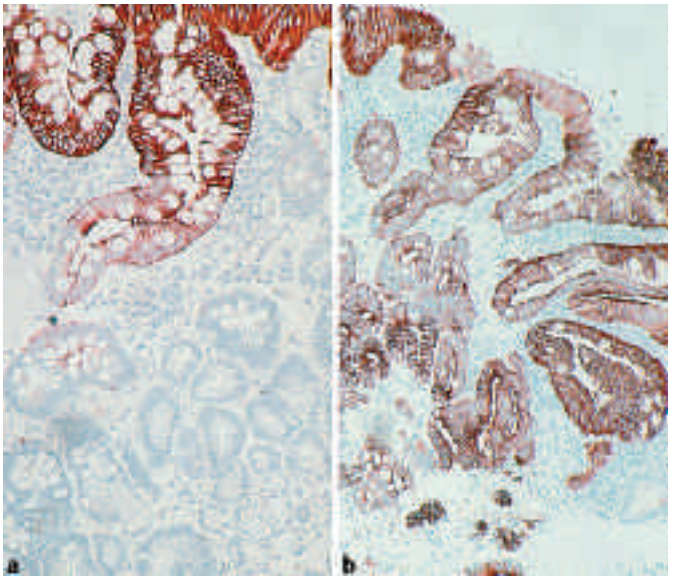

Figure **49** Histology. Columnar metaplasia in esophagus with pattern of cytokeratin (CK) immunostaining: **a** CK 20 antigen-positive only in the foveola; **b** CK 7 antigen-positive at the surface and in the glands.

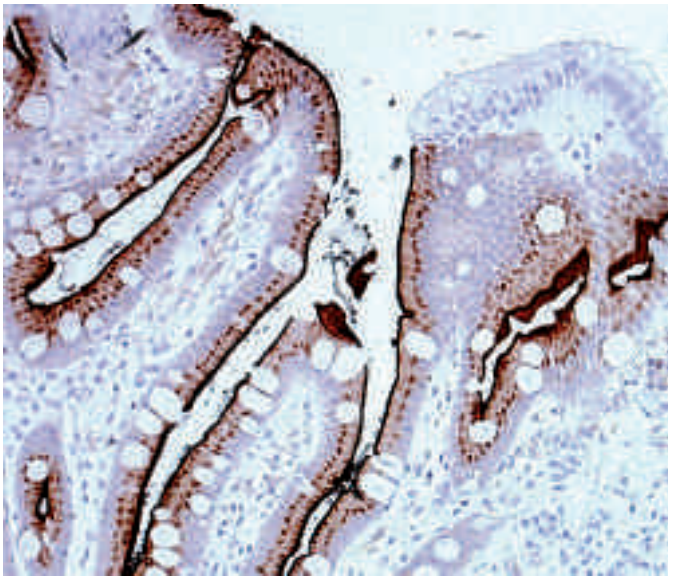

Figure **51** Histology. Columnar metaplasia in esophagus; complete intestinal metaplasia: CD10 membrane immunostaining of cells with intestinal differentiation.

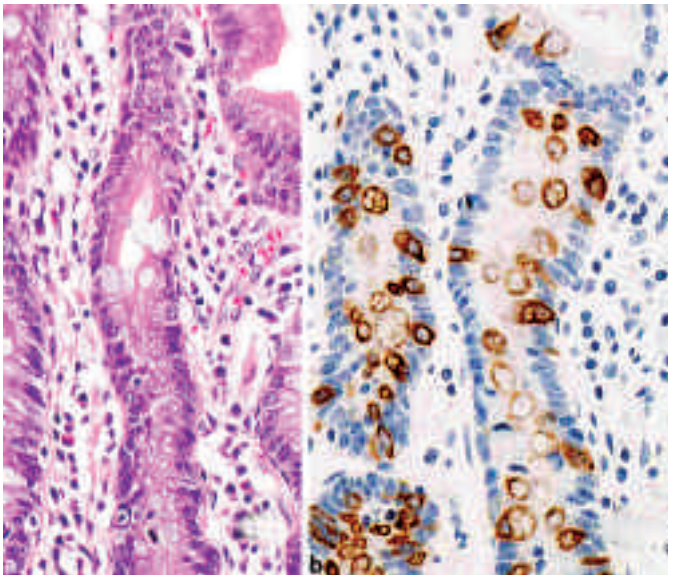

Figure **50** Histology. Columnar metaplasia in esophagus; complete intestinal metaplasia: **a** H & E stain; **b** mucin MUC 2 for goblet cells.

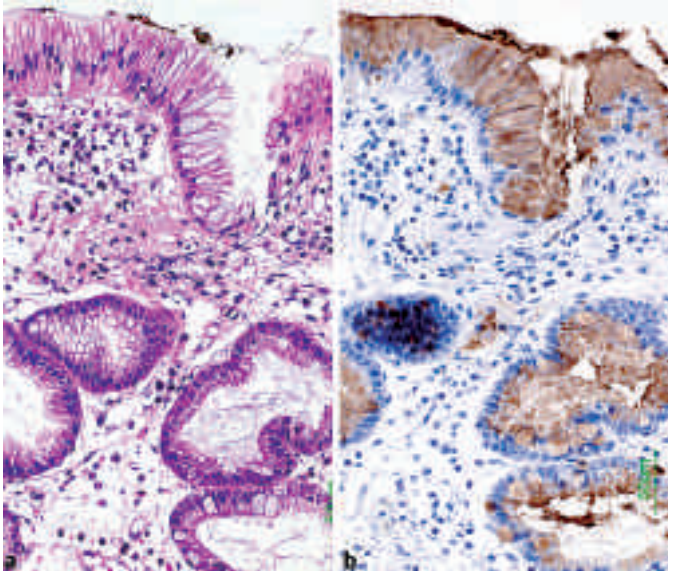

Figure **52** Histology. Columnar metaplasia in esophagus; incomplete intestinal metaplasia: **a** H & E stain; **b** HGM stain.

This document was downloaded for personal use only. Unauthorized distribution is strictly prohibited.

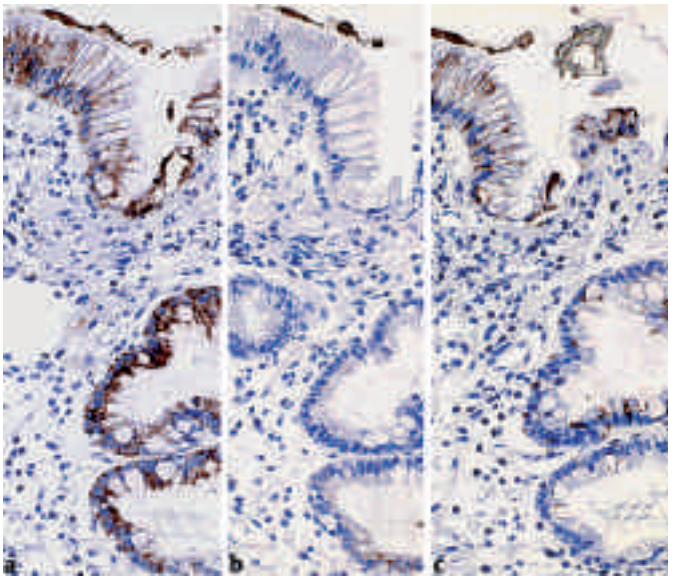

Figure **53** Histology. Columnar metaplasia in the esophagus; incomplete intestinal metaplasia: **a** positive for mucin MUC 5AC; **b** negative for mucin MUC 6; **c** very faint stain for mucin MUC 2 for goblet cells.

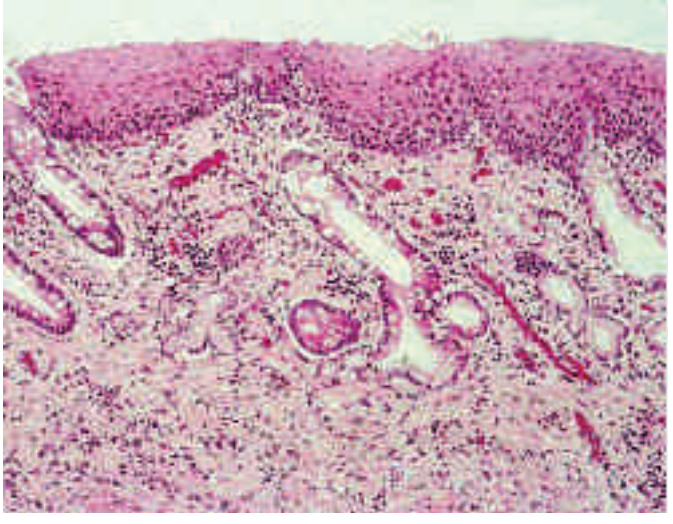

Figure **54** Surgical specimen. Pseudo-regression of columnar metaplasia in esophagus: specialized epithelium is covered with neo-formed squamous epithelium.

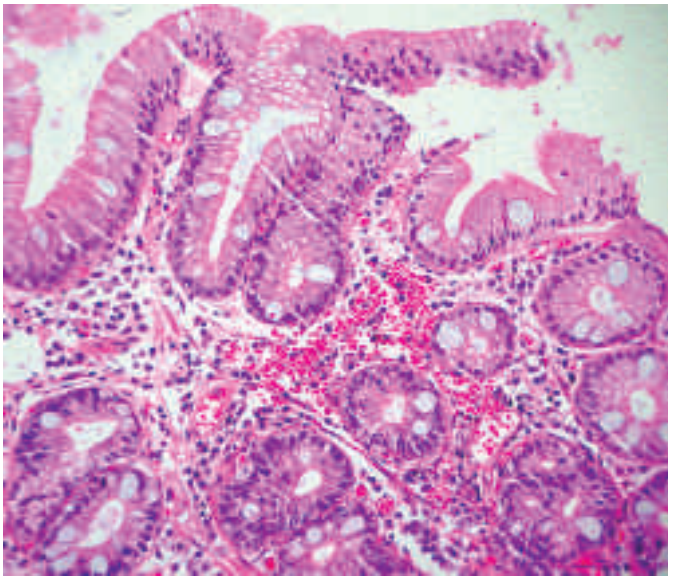

Figure **55** Forceps biopsy at endoscopy, H&E stain. Columnar metaplasia in esophagus; presence of intestinal metaplasia.

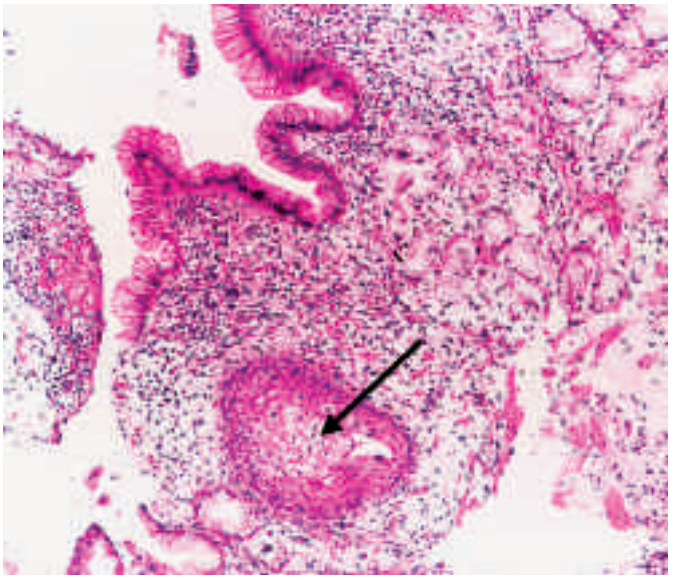

Figure **56** Forceps biopsy at endoscopy, H&E stain. Columnar metaplasia: transverse section (arrow) of an excretory duct of esophageal gland proper. This confirms the esophageal location.

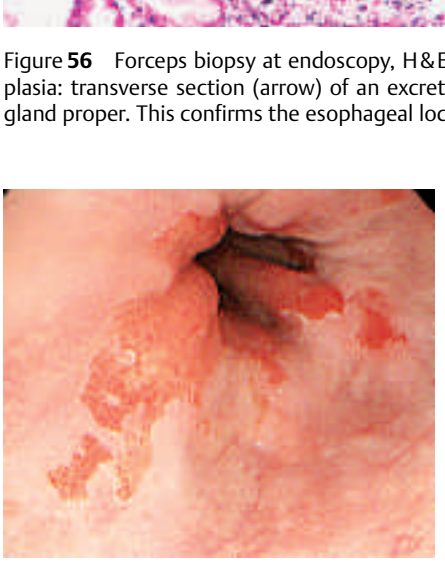

Figure **57** Endoscopy, standard technique: Short segment of columnar metaplasia in esophagus with finger-like extension.

This document was downloaded for personal use only. Unauthorized distribution is strictly prohibited.

Figure **58** Endoscopy, standard technique. A short segment of columnar metaplasia is seen in the esophagus, with a large finger-like extension.

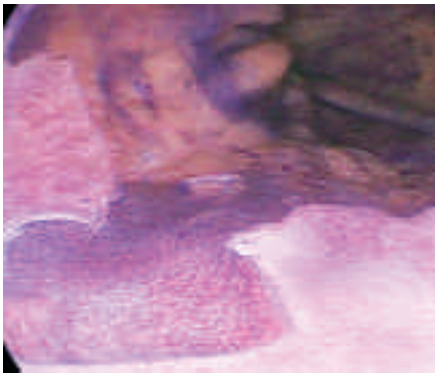

Figure **59** Endoscopy, cresyl violet chromoscopy. In the same patient as in Figure **58**; the stained area shows intestinal metaplasia.

Figure **60** Endoscopy, acetic acid chromoscopy. A short segment of columnar metaplasia, with whitish discoloration, is shown in the esophagus.

Figure **61** Endoscopy, iodine/potassium iodide chromoscopy. A short segment of unstained columnar metaplasia is seen in the esophagus, with small squamous islands.

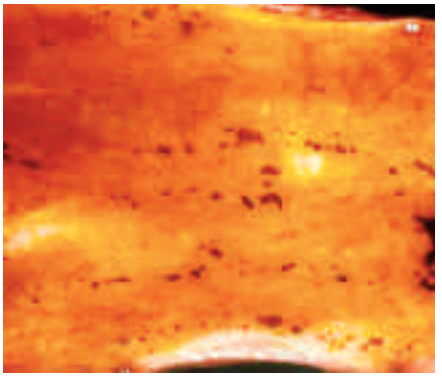

Figure **62** Surgical specimen of esophagus with columnar metaplasia stained with iodine/potassium iodide. The multiple tiny stained squamous islands may correspond to the ducts of esophageal glands proper.

Figure **63** Endoscopy, standard technique. A long segment of columnar metaplasia in the esophagus, with small squamous islands.

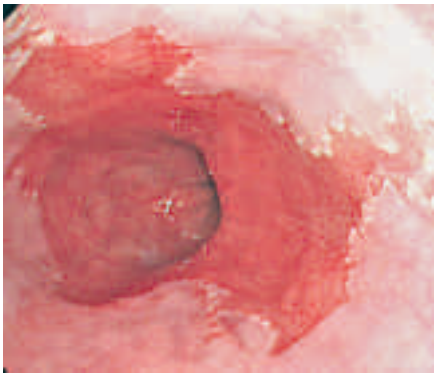

Figure **64** Endoscopy, acetic acid chromoscopy. A long segment of columnar metaplasia in esophagus; contrast-enhanced at the junction of the two types of epithelium.

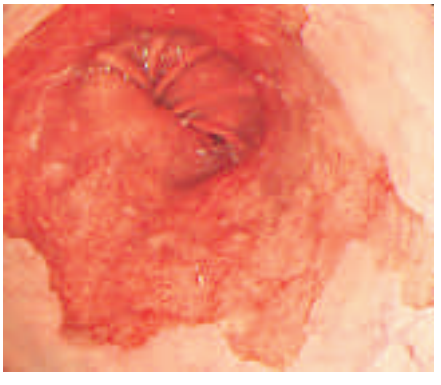

Figure **65** Endoscopy, standard technique. A long segment of columnar metaplasia is seen in the esophagus.

This document was downloaded for personal use only. Unauthorized distribution is strictly prohibited.

Figure **66** Endoscopy, standard technique. A long segment of columnar metaplasia is seen in the esophagus, with finger-like extensions and squamous islands.

Figure **67** Endoscopy, NBI. A long segment of columnar metaplasia is seen in the esophagus.

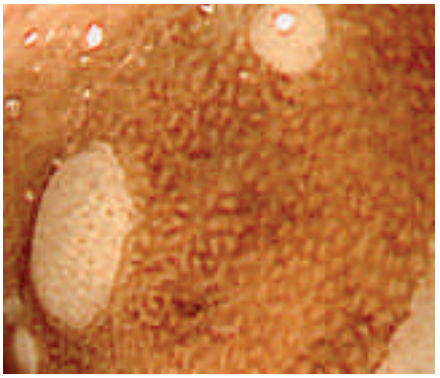

Figure **68** Zoom endoscopy, NBI. Columnar metaplasia of the esophagus has a pattern of round pits surrounding two small squamous islands. It is negative for intestinal metaplasia. Small dots in the squamous epithelium correspond to intrapapillary capillary loops.

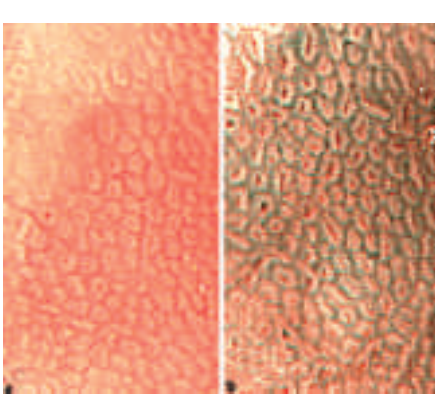

Figure **69** Zoom endoscopy. Columnar metaplasia in esophagus with a pattern of round pits, seen by: **a** standard method; **b** NBI.

Figure **70** Zoom endoscopy, NBI. A pattern of oval crests in a finger-like extension of columnar metaplasia in the esophagus is shown.

Figure **71** Zoom endoscopy, indigo carmine chromoscopy. Columnar metaplasia in the esophagus shows a pattern of long oval crests surrounding a squamous island.

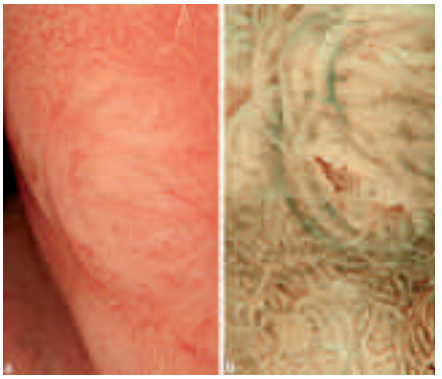

Figure **72** Zoom endoscopy. Columnar metaplasia in esophagus, with whitish, long oval crests corresponding to foveolar hyperplasia of cardiac-type epithelium: **a** standard technique; **b** NBI.

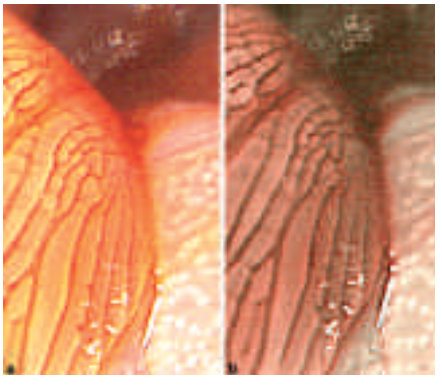

Figure **73** Zoom endoscopy. A finger-like extension of columnar metaplasia in esophagus has a linear surface pattern: **a** acetic acid chromoscopy; **b** NBI.

This document was downloaded for personal use only. Unauthorized distribution is strictly prohibited.

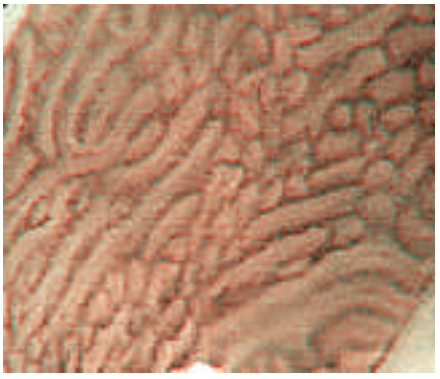

Figure **74** Zoom endoscopy, NBI. Finger-like extension of columnar epithelium in esophagus shows a pattern of linear crests with some villi.

Figure **75** Zoom endoscopy with acetic acid chromoscopy. Columnar epithelium in esophagus has a gyrus-like pattern with some oval crests.

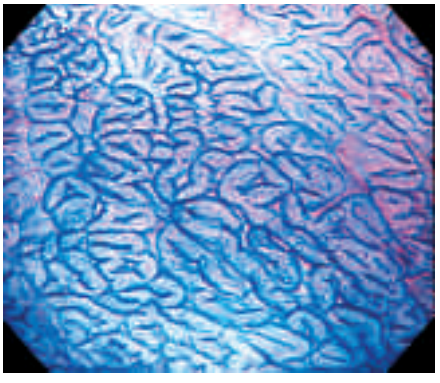

Figure **76** Zoom endoscopy, methylene blue chromoscopy. Columnar metaplasia in esophagus, showing a gyrus-like pattern of the stained crests.

Figure **77** Zoom endoscopy, methylene blue chromoscopy. Columnar metaplasia in esophagus, showing a gyrus-like pattern of the stained crests; positive for intestinal metaplasia.

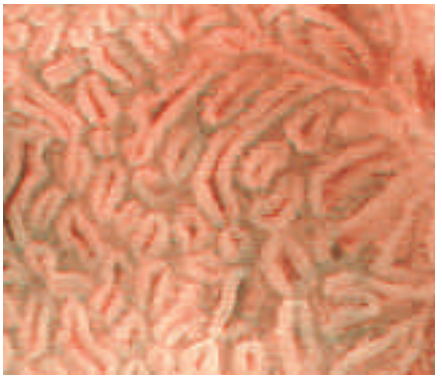

Figure **78** Zoom endoscopy, NBI. Columnar metaplasia in esophagus, showing a gyrus pattern of the epithelial crests; positive for intestinal metaplasia.

Figure **79** Zoom endoscopy, NBI. Finger-like extension of columnar metaplasia in esophagus, with a gyrus pattern of the crests; positive for intestinal metaplasia. Small dots in the squamous epithelium correspond to intrapapillary capillary loops.

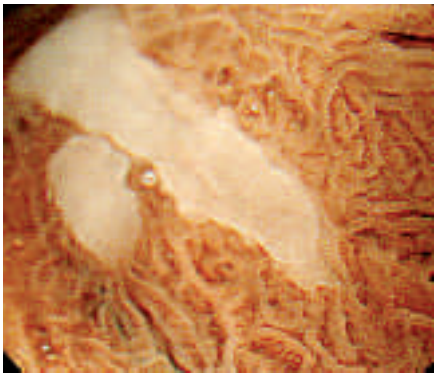

Figure **80** Zoom endoscopy, NBI. Columnar metaplasia in esophagus, with a gyrus pattern of epithelial crests surrounding two squamous islands.

Figure **81** Zoom endoscopy, NBI. Columnar metaplasia with villous pattern; positive for intestinal metaplasia.

This document was downloaded for personal use only. Unauthorized distribution is strictly prohibited.

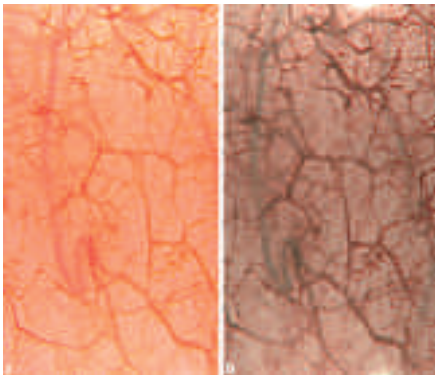

Figure **82** Zoom endoscopy. Columnar metaplasia in the esophagus, showing the network of small linear branching vessels: **a** with the standard technique; **b** with NBI.

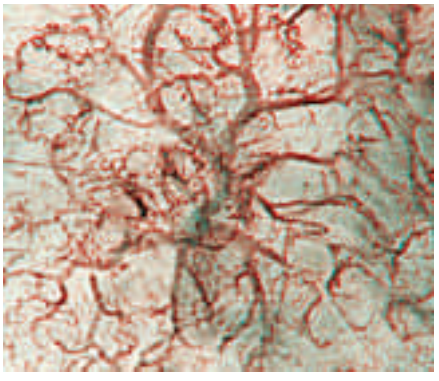

Figure **83** Zoom endoscopy, NBI. Columnar metaplasia in esophagus, showing an arborescent vascular network with the collecting vein.

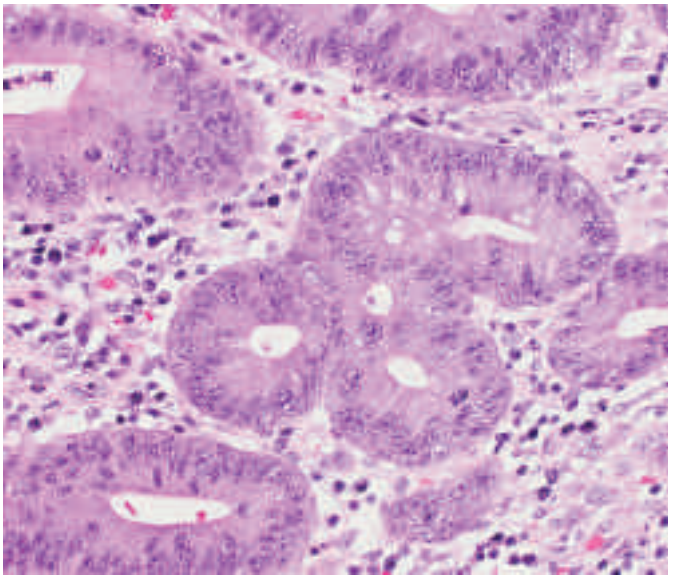

Figure **84** Histology. Columnar metaplasia in esophagus: low grade intraepithelial neoplasia. Nuclei do not reach the apical pole of cells.

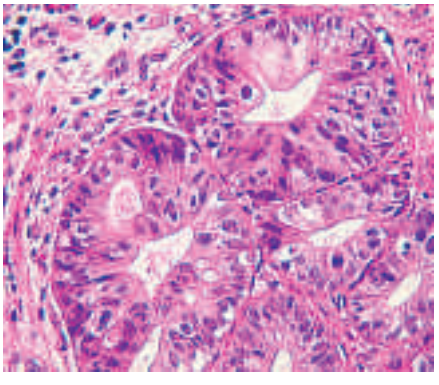

Figure **85** Histology: Columnar metaplasia in esophagus: high grade intraepithelial neoplasia. Nuclei reach the apical pole of cells.

Figure **86** Endoscopy with a hood, standard technique. Columnar metaplasia in esophagus; there is flat mucosa with small irregular vessels (arrow). Positive for low grade intraepithelial neoplasia.

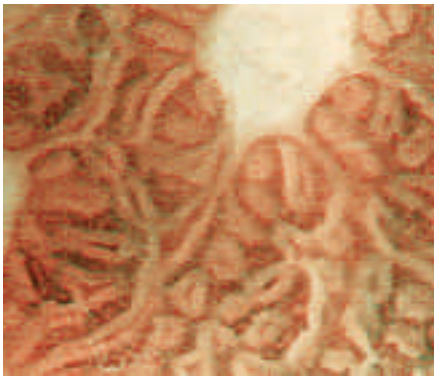

Figure **87** Zoom endoscopy, NBI. Columnar metaplasia in esophagus, with gyrus pattern, close to a squamous island. Positive for low grade intraepithelial neoplasia.

Figure **88** Zoom endoscopy, NBI, acetic acid chromoscopy. Columnar metaplasia in esophagus with large linear grooves and irregular crests. Positive for low grade intraepithelial neoplasia.

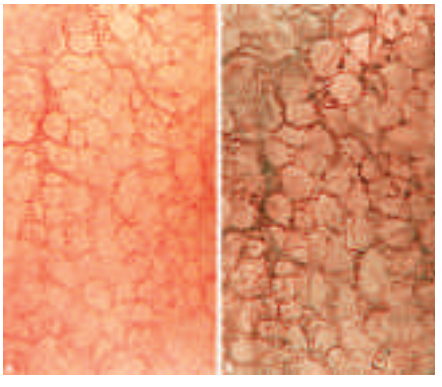

Figure **89** Zoom endoscopy. Columnar metaplasia in esophagus, showing irregular vessels organized in a circular pattern in a flat mucosa, with some corkscrew vessels. Positive for low grade intraepithelial neoplasia. **a** Standard technique; **b** NBI.

This document was downloaded for personal use only. Unauthorized distribution is strictly prohibited.

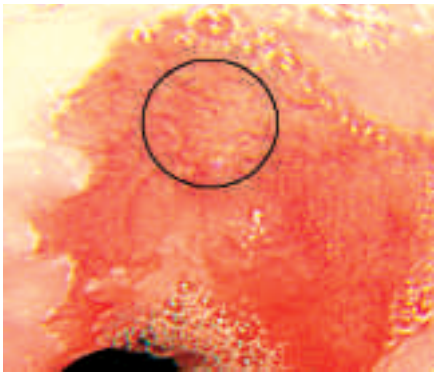

Figure **90** Endoscopy, standard technique. Columnar metaplasia in esophagus. Flat mucosa is seen with irregular vessels (in the circle) near the ascended squamocolumnar epithelial junction (neo-SCJ). Positive for high grade intraepithelial neoplasia.

Figure **91** Zoom endoscopy, NBI technique. Columnar metaplasia in esophagus with enlarged epithelial crests, irregular vessels and large collecting veins. Positive for high grade intraepithelial neoplasia.

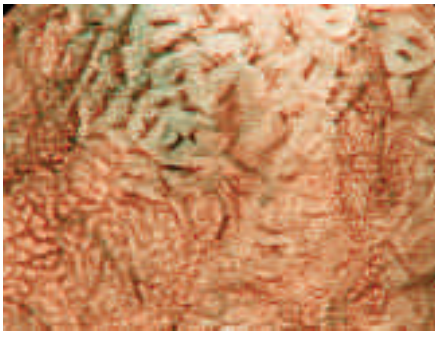

Figure **92** Zoom endoscopy, NBI technique. Columnar metaplasia in esophagus with enlarged crests (upper part of image) contrasting with small round pits (lower left quadrant). Irregular vessels are seen. Positive for high grade intraepithelial neoplasia.

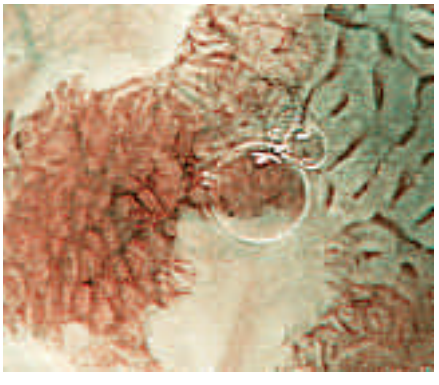

Figure **93** Zoom endoscopy, NBI technique, acetic acid chromoscopy. Columnar metaplasia in esophagus near the neo-SCJ with large crests (at right) contrasting with small round pits (at left.) Positive for high grade intraepithelial neoplasia.

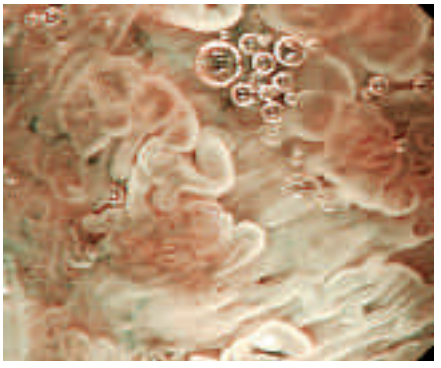

Figure **94** Zoom endoscopy, NBI technique, acetic acid chromoscopy. Columnar metaplasia in esophagus with a villous pattern. Positive for high grade intraepithelial neoplasia.

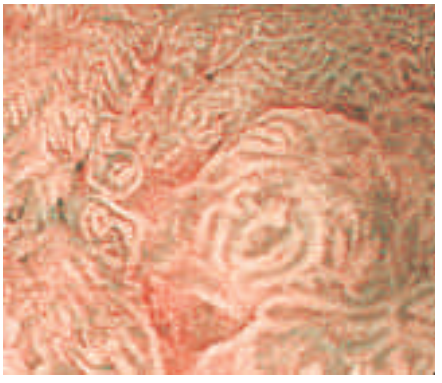

Figure **95** Zoom endoscopy, NBI technique. Columnar metaplasia in esophagus with gyrus-like pattern. Positive for high grade intraepithelial neoplasia.

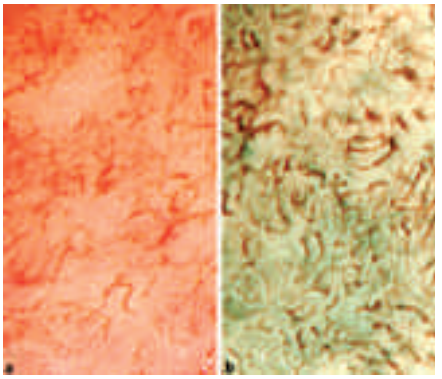

Figure **96** Zoom endoscopy. Columnar metaplasia in esophagus; vascular pattern in high grade intraepithelial neoplasia, many corkscrew vessels. **a** Standard technique **b** NBI technique.

Figure **97** Zoom endoscopy, acetic acid chromoscopy. Columnar metaplasia in esophagus. A small ulcer is seen in a fold. Positive for high grade intraepithelial neoplasia.

This document was downloaded for personal use only. Unauthorized distribution is strictly prohibited.

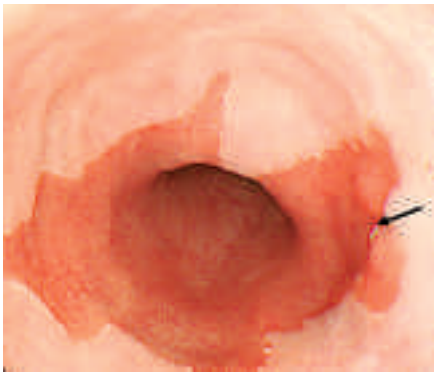

Figure **98** Endoscopy, standard technique. Columnar neoplasia in esophagus. There are two small elevations (0–IIa) at the border of the SCJ (arrow). Positive for high grade intraepithelial neoplasia.

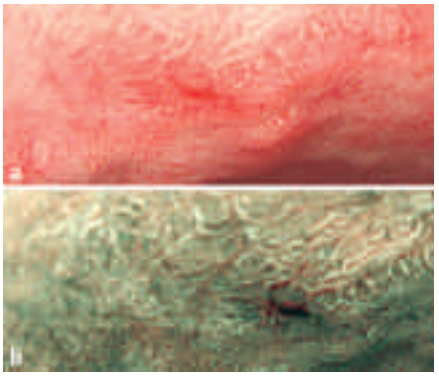

Figure **99** Zoom endoscopy. Columnar neoplasia in esophagus. A slightly elevated area (0–IIa) with irregular crests is seen: **a** standard technique **b** NBI image. Positive for high grade intraepithelial neoplasia.

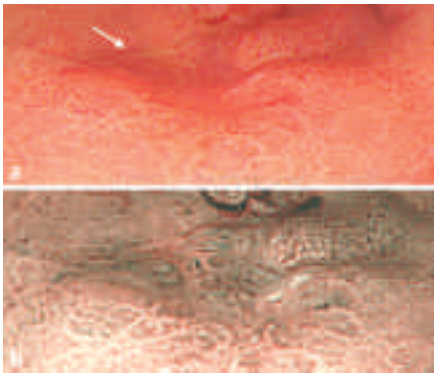

Figure **100** Zoom endoscopy. Columnar neoplasia in esophagus. There is an area that is slightly depressed and elevated at the periphery (0–IIc + IIa) with irregular crests: **a** standard technique **b** NBI technique. Positive for high grade intraepithelial neoplasia.

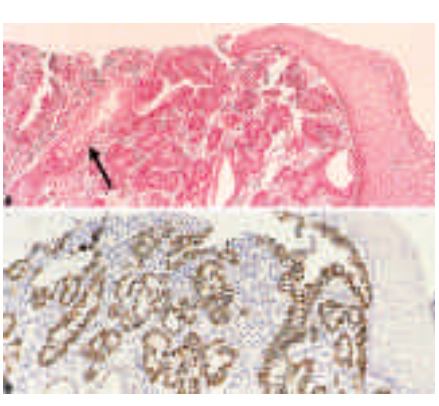

Figure **101** Surgical specimen. Adenocarcinoma (T1, sm) in columnar metaplasia of the esophagus distal to squamous epithelium. **a** H&E stain shows a zone with intestinal metaplasia included in the neoplastic tissue (arrow). **b** Immunostaining of p53.

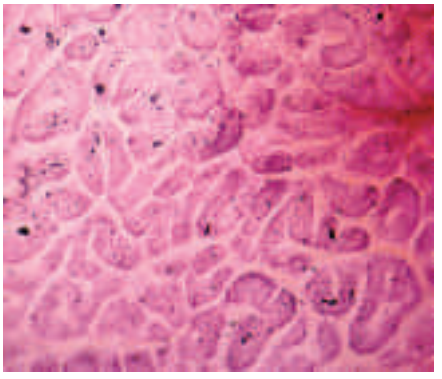

Figure **102** Surgical specimen. Columnar metaplasia in esophagus with specialized epithelium. A stereomicroscopic study of the surface stained with cresyl violet, showing a homogeneous gyrus pattern.

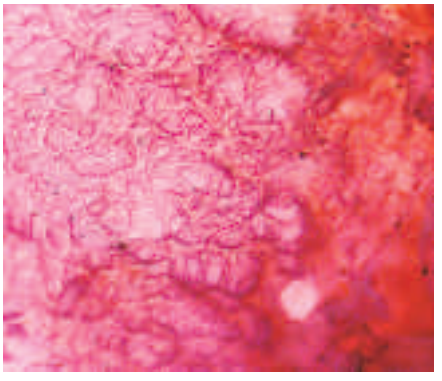

Figure **103** Surgical specimen. Adenocarcinoma in esophagus. A stereomicroscopic study of the surface stained with cresyl violet shows an irregular pattern with alternating areas of irregular budding and flatness.

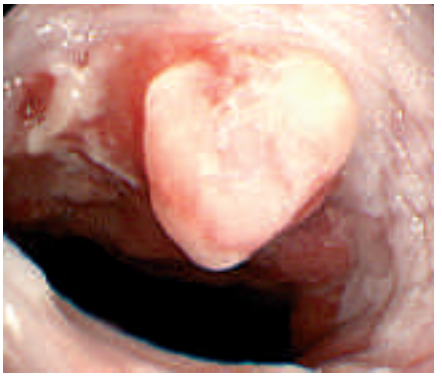

Figure **104** Endoscopy, standard technique. Polypoid adenocarcinoma type 0–Is at EGJ, adjacent to squamous epithelium; gastric or esophageal origin uncertain.

Figure **105** Endoscopy, standard technique. Adenocarcinoma type 0–Is + IIc at EGJ, adjacent to squamous epithelium; gastric or esophageal origin uncertain.

This document was downloaded for personal use only. Unauthorized distribution is strictly prohibited.

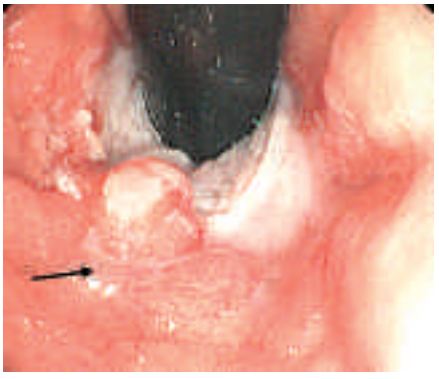

Figure **106** Endoscopy with a U-turn, standard technique. Adenocarcinoma type 0 – Is + IIc at EGJ (arrow in depressed area), adjacent to squamous epithelium (arrow in depressed area); gastric or esophageal origin uncertain.

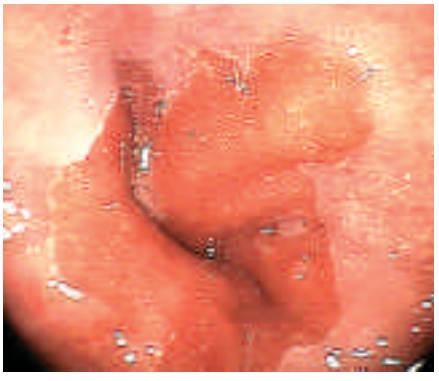

Figure **107** Endoscopy, standard technique. Adenocarcinoma type 0 – IIa at EGJ, adjacent to squamous epithelium; gastric or esophageal origin uncertain.

Figure **108** Endoscopy with a U-turn in stomach, standard technique. Adenocarcinoma type 0 – Is at EGJ; gastric or esophageal origin uncertain.

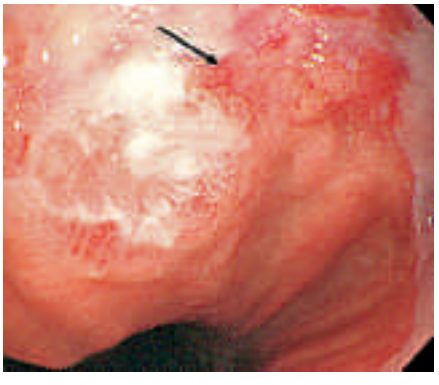

Figure **109** Endoscopy, standard technique. Adenocarcinoma type 0 – IIa + II c at EGJ (arrow in depressed area); gastric or esophageal origin uncertain.

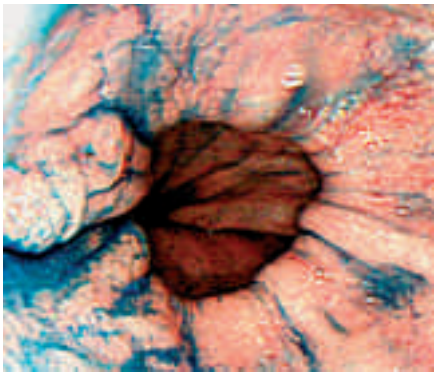

Figure **110** Endoscopy, indigo carmine chromoscopy. Multinodular adenocarcinoma type 0 – IIa in esophagus, in a long segment of columnar neoplasia.

Figure **111** Endoscopy, standard technique. Small adenocarcinoma in esophagus type 0 – Is, in a long segment of columnar neoplasia.

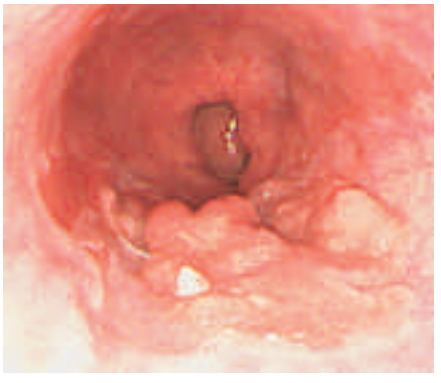

Figure **112** Endoscopy, standard technique. Multinodular adenocarcinoma type 0 – IIa in esophagus, in a long segment of columnar neoplasia.

Figure **113** Endoscopy, standard technique. Multinodular adenocarcinoma type 0 – IIa + IIc in esophagus, in a long segment of columnar neoplasia (arrow in depressed area).

This document was downloaded for personal use only. Unauthorized distribution is strictly prohibited.

Figure **114** Endoscopy, standard technique. Adenocarcinoma type 0 – IIa + IIc in esophagus, in a long segment of columnar neoplasia, adjacent to squamous epithelium.

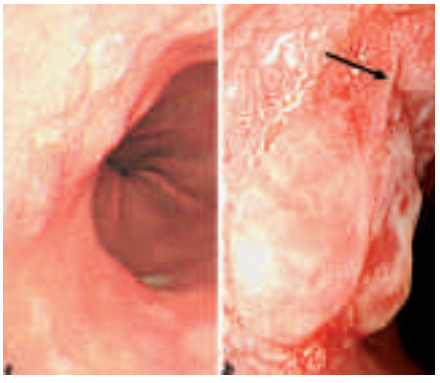

Figure **115** Endoscopy, standard technique. Adenocarcinoma type 0 – IIa + IIc in esophagus in a long segment of columnar neoplasia: **a** distant view; **b** close view (arrow in depressed area).

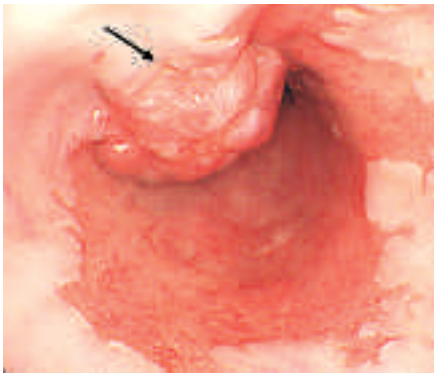

Figure **116** Endoscopy, standard technique. Adenocarcinoma type 0 – Is + IIc in esophagus, in a long segment of columnar neoplasia, adjacent to squamous epithelium (arrow in depressed area).

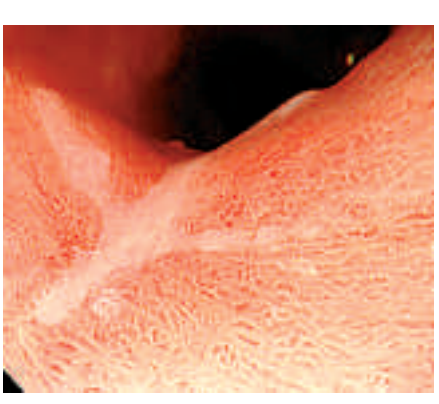

Figure **117** Endoscopy, standard technique. Depressed adenocarcinoma type 0 – IIc in esophagus, in a long segment of columnar neoplasia.

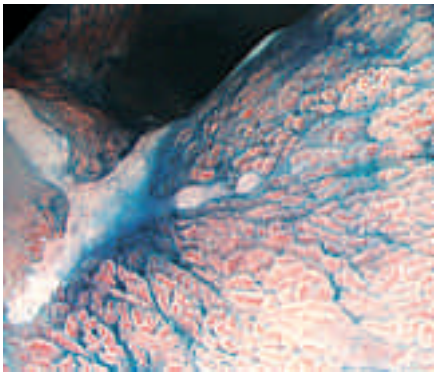

Figure **118** Endoscopy, indigo carmine chromoscopy. Same lesion as in Figure **117**.

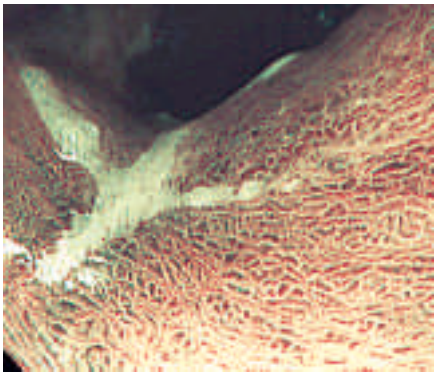

Figure **119** Endoscopy, NBI technique. Same lesion as in Figure **117**.

This document was downloaded for personal use only. Unauthorized distribution is strictly prohibited.