

# Hepatic Perforation: A Complication of Proximal Biliary Stent Migration

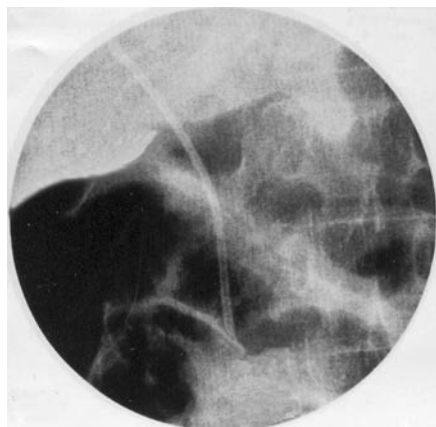


Figure 1 Radiograph of the right upper abdomen showing a migrated stent with dilated loops of intestine.

**O. J. Shah<sup>1</sup>, F. A. Khan<sup>1</sup>, I. Robanni<sup>2</sup>,  
N. A. Wani<sup>1</sup>**

<sup>1</sup> Department of Surgery, Sher-I-Kashmir  
Institute of Medical Sciences, Srinagar,  
Kashmir, India

<sup>2</sup> Department of Radiodiagnosis, Sher-I-  
Kashmir Institute of Medical Sciences,  
Srinagar, Kashmir, India

## Corresponding Author

**O. J. Shah, M. D.**

Kral-Sangri  
Brain, Nishat  
Srinagar  
Kashmir  
India  
Fax: +91-194-2403470  
E-mail: omarjshah@yahoo.com

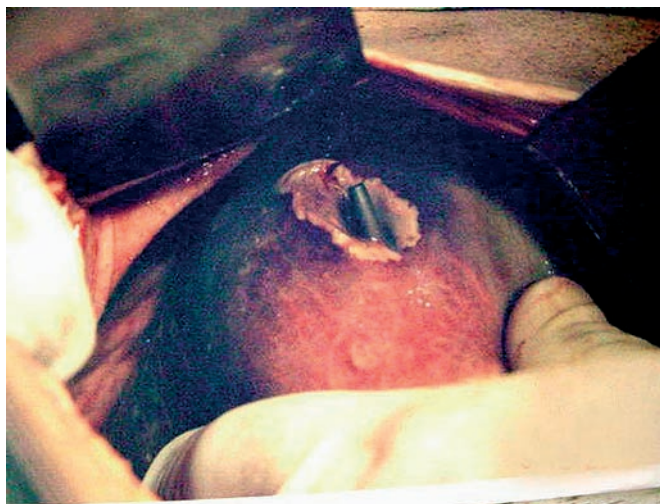

Figure 2 Peroperative photograph showing the hepatic perforation in the anterosuperior part of the right lobe of the liver caused by the migrated stent.

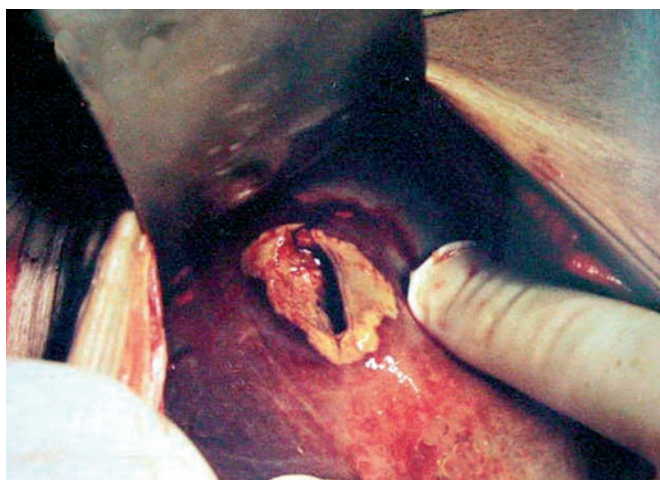


Figure 3 Close-up peroperative view of the hepatic perforation seen in Figure 2. Note the size of the perforation.