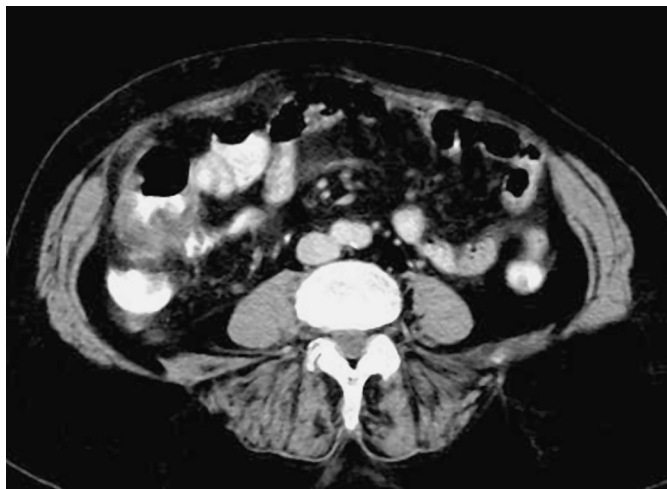

## Cecal Diverticulitis: An Unusual Endoscopic Finding

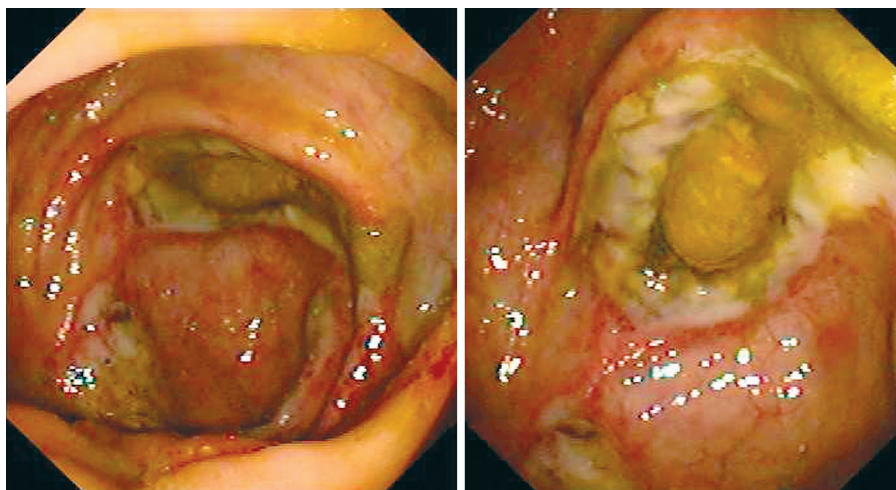


**Figure 1** Colonoscopy must be avoided whenever colonic diverticulitis is suspected. However, some patients are diagnosed endoscopically, most of them with left-sided diverticulitis. A 74 year-old woman presented with lower right abdominal pain. Her physical examination did not show any evidence of an abdominal mass or any peritoneal signs. Complementary studies showed a neutrophil count of 10 950/ml and cecal wall thickening, with distortion of the surrounding fatty tissue on abdominal computed tomography, suggesting a colonic tumor.

**F. J. Fernández-Pérez, C. De Sola, N. Fernández-Moreno, R. Rivera-Irigoin, E. Ubiña-Aznar, G. García-Fernández, J. M. Navarro-Jarabo, P. Moreno-Mejías, A. Ibañez-Pinto, A. Sanchez-Cantos**  
Dept. of Gastroenterology, Costa del Sol Hospital, Marbella, Spain

### Corresponding Author

**F. J. Fernández-Pérez, M. D.**  
Dept. of Gastroenterology  
Costa del Sol Hospital  
Ctra. Nacional 340, Km 187  
Marbella 29600, Malaga  
Spain  
Fax: +34-952-823219  
E-mail: ffernandezp@meditex.es



**Figure 2** Colonoscopy revealed fecal impaction inside a diverticular orifice close to the appendix, with severe mucosal inflammation surrounding it. There was no evidence of neoplasm. Diverticulectomy and appendectomy were carried out, with no postoperative complications: clinical practice, right-sided colonic diverticulitis is a rare finding, and a colonoscopic diagnosis is exceptional.