

Common Variable Immunodeficiency: Endoscopic and Pathological Findings

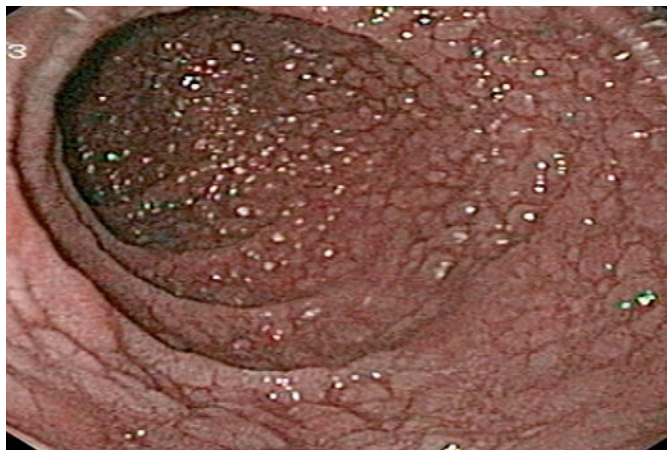

Figure 1 A 24-year-old man presented with chronic diarrhea. Mild splenomegaly was observed during the physical examination. Upper gastrointestinal endoscopy revealed numerous polypoid lesions in the duodenum.

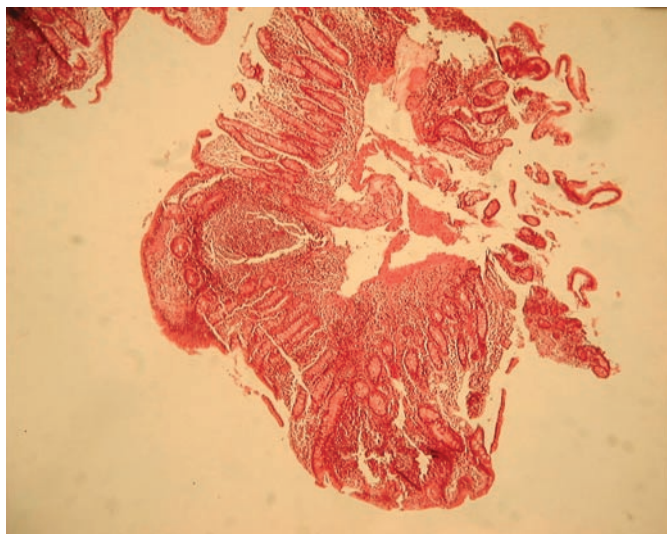


Figure 2 Mucosal biopsies were taken from the lesions. Histologically, there was a severe malabsorption pattern consisting of villous atrophy, crypt hyperplasia, lamina propria mononuclear cell infiltration, and absence of plasma cells, together with marked lymphoid nodular hyperplasia. Serum protein electrophoresis revealed hypogammaglobulinemia. Quantitative measurement of immunoglobulins revealed low serum levels of IgG, IgA, and IgM. A diagnosis of common variable immunodeficiency was made.

**F. Sadr, M. Mohamadnejad,
R. Malekzadeh, M. Sotoudeh**
Digestive Disease Research Center,
Shariati Hospital, Tehran University of
Medical Sciences, Tehran, Iran

Corresponding Author

R. Malekzadeh, M.D.
Digestive Disease Research Center
Shariati Hospital
N. Kargar St.
Tehran 14114
Iran
Fax: +98-212253635
E-mail: malek@ams.ac.ir