

K. Ocran, M. Ortner, W. Voderholzer
Division of Gastroenterology/Hepatology,
Department of Medicine, Humboldt
University Charité, Berlin, Germany

Corresponding Author

K. Ocran, M. D.

Universitätsklinikum Charité,
Med. Klinik m.S. Gastroenterologie,
Hepatology und Endokrinologie
Schumannstr. 20/21
10707 Berlin
Germany
Fax: +49-30-450514939
E-mail: ocran@charite.de

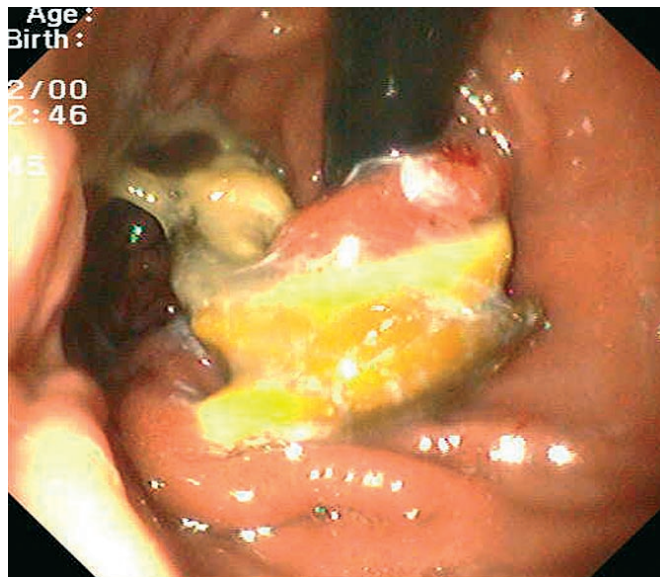

Figure 1 A 48-year-old woman had undergone gastric banding for extreme obesity (body mass index of 47) 3 years earlier. She subsequently complained of diffuse, persistent upper abdominal pain. Upper endoscopy revealed gastritis. No amelioration occurred under treatment with proton pump inhibitor (PPI). Control endoscopy eventually showed intragastric migration of the white gastric band.

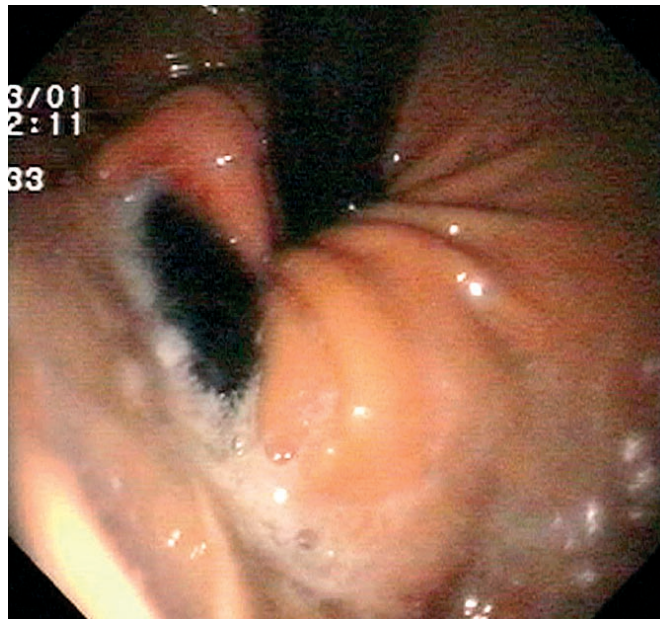


Figure 2 At a routine check-up, a 43-year-old woman was found to have anemia. She had also previously undergone gastric banding for extreme obesity. The subsequent work-up included gastroscopy, which demonstrated normal gastric mucosa. Inversion of the endoscope, however, revealed a perforation of the gastric corpus due to a penetrating gastric band. (Continuous exposure to acid had turned the band black.)