

Diffuse Colonic Polyposis Detected at Screening Colonoscopy: Mantle-Cell Lymphoma

H. C. Wolfsen, S. R. Achem

Division of Gastroenterology and Hepatology, Mayo Clinic, Jacksonville, Florida, USA

Corresponding Author

H. C. Wolfsen, M.D.

Division of Gastroenterology and Hepatology
Mayo Clinic
4500 San Pablo Road
Jacksonville, FL 32224
USA

Fax: + 1-904-953-7260

E-mail: pdt@mayo.edu

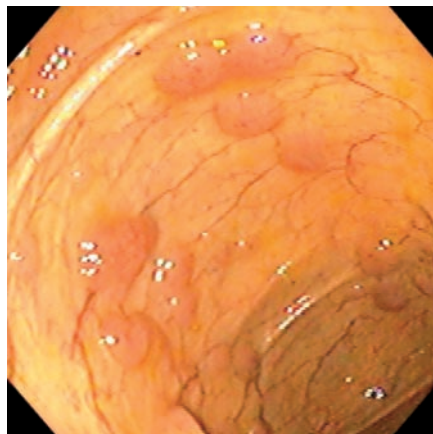


Figure 1 A 63-year-old asymptomatic white man was referred for screening colonoscopy, which detected diffuse polyposis throughout the colon and terminal ileum. Subsequently, similar lesions in the duodenum were found on upper endoscopy. Diffuse abdominal lymphadenopathy and thickened mucosa in the terminal ileum were identified on computed tomography.

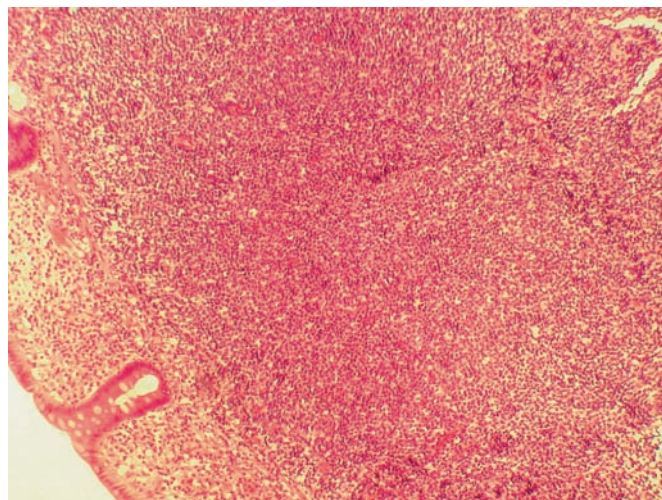


Figure 2 Immunohistopathological studies confirmed mantle-cell lymphoma, with a predominance of B cells confirmed with positive CD20, CD5 and cyclin D1 immunostains. Treatment with combination chemotherapy, including rituximab, was initiated.