# Percutaneous Endoscopic Gastrostomy Site Metastasis in a Patient with Esophageal Cancer

Figure **1** An abdominal wall tumor with a diameter of 3 cm (Figure **1**) had formed at the site of a percutaneous endoscopic gastrostomy (PEG). The PEG had been inserted 10 months earlier using the pull-through technique in a 63-year-old patient with locally advanced squamous-cell carcinoma of the upper esophagus. The primary tumor had been treated with palliative chemoradiotherapy, which resulted in complete remission.

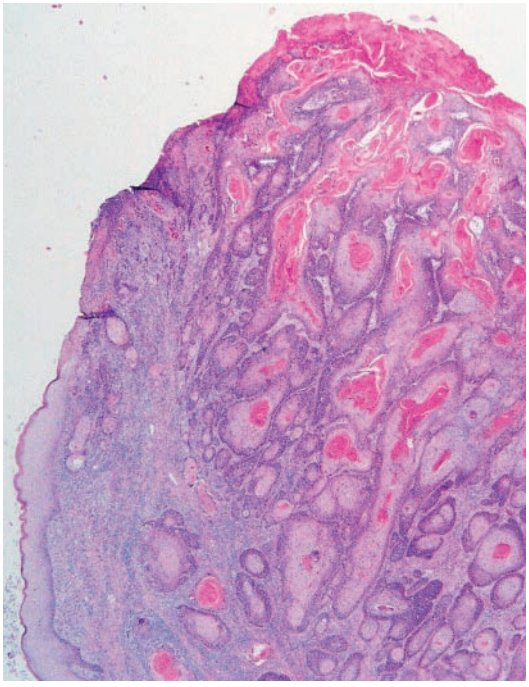

Figure **2** The PEG-associated tumor was histologically identical to the original malignancy (Figure **2**, hematoxylin/eosin stain) and was treated by resection of the affected abdominal wall and subtotal gastrectomy. This case illustrates the fact that malignant cells from a stenotic esophageal cancer can be sheared off when a PEG plate is being pulled through and that they remain capable of forming metastases even after chemoradiotherapy.

**W. Wacke[1], U. Hecker[1], C. Woenckhaus[2], M. M. Lerch[1]**

[1] Division of Gastroenterology and Endocrinology, Ernst Moritz Arndt University, Greifswald, Germany

[2] Institute of Pathology, Ernst Moritz Arndt University, Greifswald, Germany

**Corresponding Author**

**W. Wacke, M. D.**

Division of Gastroenterology and Endocrinology
Ernst-Moritz-Arndt-Universität Greifswald
Friedrich-Loeffler-Straße 23 a
17487 Greifswald
Germany
Fax: +49-3834-866605
E-mail: wacke@uni-greifswald.de





This document was downloaded for personal use only. Unauthorized distribution is strictly prohibited.