

# Endoscopic Closure of Iatrogenic Duodenal Perforation during Endoscopic Ultrasound

# UCTN

Although oesophageal perforation is a well-recognized complication during endoscopic ultrasonography [1], perforation of the duodenum during the procedure has not previously been reported.

A 66-year-old woman underwent endoscopic ultrasound for staging of a mid-oesophageal tumor. During the procedure, free air became apparent in the retroperitoneum. A straight-viewing standard endoscopy was performed immediately, and a 10-mm perforation was identified in the posterior wall of the duodenal bulb. The tear in the duodenal wall was immediately closed using an Olympus endoclipping device (HX-5LR-1); complete apposition was achieved at the margins of the defect using four Endoclips (Figure 1). Computed tomography confirmed that there was free air in peritoneal cavity (Figure 2). The patient was placed on a nil per os regimen with continuous nasogastric tube drainage, intravenous fluids and electrolytes, broad-spectrum antibiotics, and peripheral parenteral nutrition. A Gastrografin meal confirmed successful closure of the defect, with no leakage of contrast into the peritoneal cavity (Figure 3). The patient resumed a normal diet on day 7, and still had no adverse sequelae of the perforation 2 months later.

Most cases of iatrogenic duodenal perforation at endoscopy are reported after endoscopic sphincterotomy [2]. The standard treatment for duodenal perforation is surgical closure. Unlike the more common spontaneous perforation resulting from peptic ulcer disease, iatrogenic perforations have a relatively lower chance of bacterial contamination in a fasting patient, and there is therefore sometimes an opportunity to manage these patients by nonsurgical means.

There have been isolated reports of the use of an endoscopic clipping device for closure of iatrogenic perforations in the oesophagus [3], stomach [4], and duodenum [5]. In the present patient, nonsurgical closure was considered appropriate in

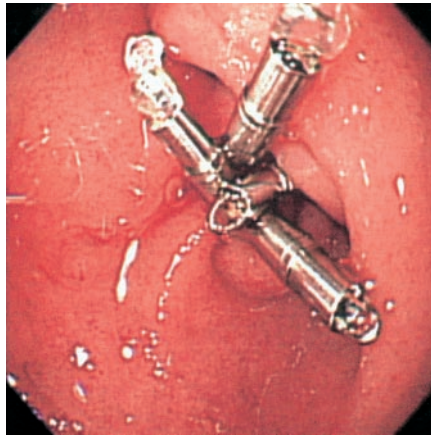


Figure 1 Endoscopic view, with clips in place after closure of the perforation.

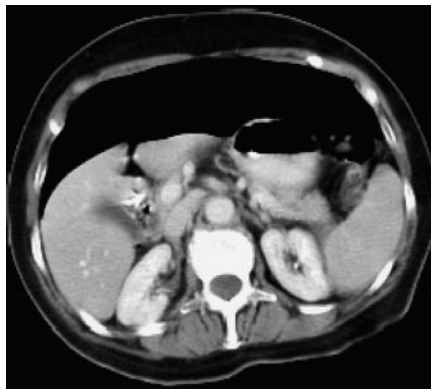


Figure 2 Abdominal computed tomogram taken soon after closure of the perforation, showing free air in the peritoneum and the clips in place.

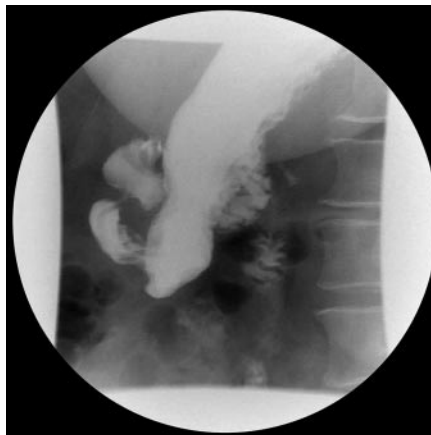

Figure 3 Gastrografin meal, showing no leakage of dye into the peritoneal cavity and confirming complete closure of the duodenal tear.

the context of the patient's coexistent malignant disease. The present report, along with others, suggests that endoscopic clipping is a useful technique for closure of iatrogenic upper gastrointestinal perforations.

**S. Sebastian<sup>1</sup>, A. T. Byrne<sup>2</sup>,  
W. C. Torreggiani<sup>2</sup>, M. Buckley<sup>1</sup>**

<sup>1</sup> Dept. of Gastroenterology, Adelaide and Meath Hospital, Tallaght, Dublin, Republic of Ireland

<sup>2</sup> Dept. of Radiology, Adelaide and Meath Hospital, Tallaght, Dublin, Republic of Ireland

## References

- 1 Chandrashekar MV, Richardson DL, Preston S et al. Perforation of a nonobstructing gastro-oesophageal carcinoma by oblique-viewing endoscopic ultrasound videoscope: a need for a safe technique. *Endoscopy* 2002; 34: 934
- 2 Freeman ML, Nelson DB, Sherman S et al. Complications of endoscopic biliary sphincterotomy. *N Engl J Med* 1996; 335: 909–918
- 3 Binmoeller KF, Grimm H, Soehendra N. Endoscopic closure of a perforation using metallic clips after snare excision of a gastric leiomyoma. *Gastrointest Endosc* 1993; 39: 172–174
- 4 Kaneko T, Akamatsu T, Shimodaira K et al. Non-surgical treatment of duodenal perforation by endoscopic repair using a clipping device. *Gastrointest Endosc* 1999; 50: 410–414
- 5 Wewalka FW, Clodi PH, Hardinger D. Endoscopic clipping of esophageal perforation after pneumatic dilatation for achalasia. *Endoscopy* 1995; 27: 608–611

## Corresponding Author

**M. Buckley, M.D.**

Dept. of Gastroenterology  
Adelaide and Meath Hospital, Tallaght  
Dublin 24, Ireland

Fax: +353-1-4143850

E-mail: martin.buckley@amnch.ie