Solid Pseudopapillary Tumor of the Pancreas: Diagnosis by EUS-Guided Fine-Needle Aspiration

A partially calcified cystic lesion in the area of the pancreatic tail was incidentally detected when a 57-year-old woman underwent chest computed tomography (CT) for evaluation of chronic cough (Figure **1a**). She had no history of pancreatitis, but reported severe abdominal trauma approximately 20 years earlier. A thrombosed pseudoaneurysm was therefore considered in the differential diagnosis. Endoscopic ultrasound (EUS) showed a calcified lesion 3.5 × 2.3 cm in size in the pancreatic tail, with an obvious hypoechoic solid component as well as cystic areas (Figure **1b**). Fine-needle aspiration (FNA) revealed cells arranged in distinct papillary-like structures. Immunohistochemistry was negative for synaptophysin and positive for low-molecular-weight cytokeratin and vimentin. The patient underwent distal pancreatectomy. Histological examination of the resected specimen confirmed a solid pseudopapillary tumor (SPT) (Figure **2**).

SPTs of the pancreas, first described by Frantz in 1959 [1], are uncommon tumors of low malignant potential that most frequently affect young women and are often found incidentally. In a recent review [2] of 24 patients (20 women, mean age 39 years), the median tumor size was 8 cm – considerably larger than in the patient described here. A total of 22 patients underwent resection, four of whom had coexistent liver metastases. Resection was not possible in two patients due to involvement of mesenteric vessels. However, the unresectable patients had a long-term survival (up to 13 years), emphasizing the often indolent nature of this tumor. Expression of vimentin, α1-antitrypsin, neuron-specific enolase, and progesterone receptors is typical for SPTs [3]. Recent reports suggest that SPTs are genetically distinct from pancreatic ductal adenocarcinomas and typically harbor mutations in the APC/beta-catenin pathway [4,5].

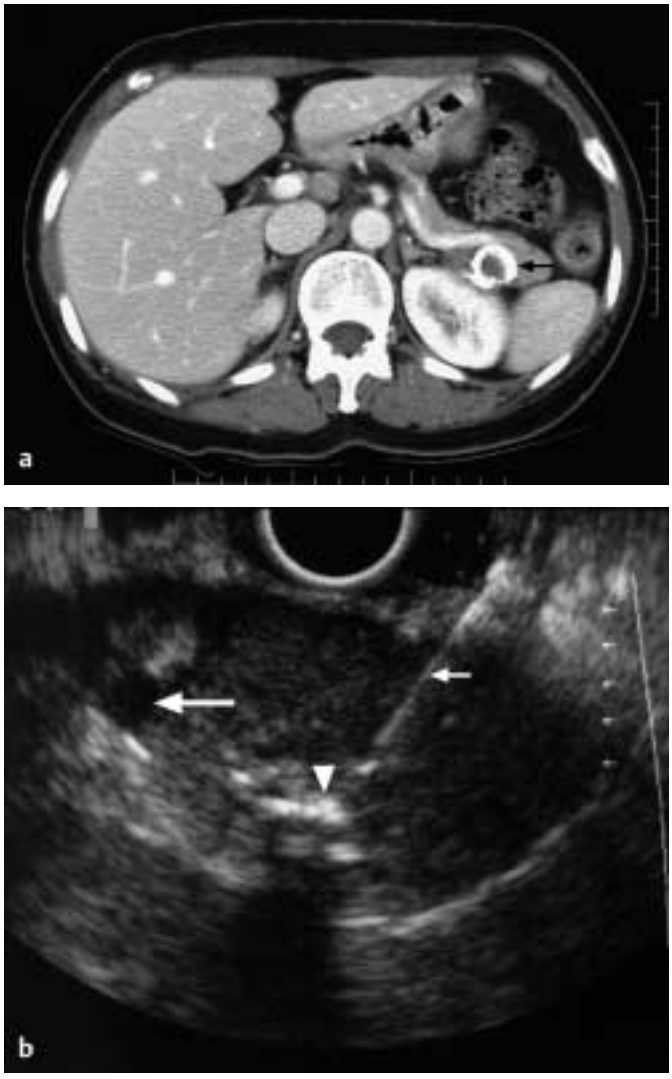

Figure **1** Computed tomogram, showing a partially calcified mass in the area of the pancreatic tail. **b** Endoscopic ultrasonography using a linear-array echo endoscope reveals a solid hypoechoic tumor with cystic areas (large arrow) and calcifications (arrowhead). Fine-needle aspiration is being carried out (the small arrow indicates the 22-gauge needle).

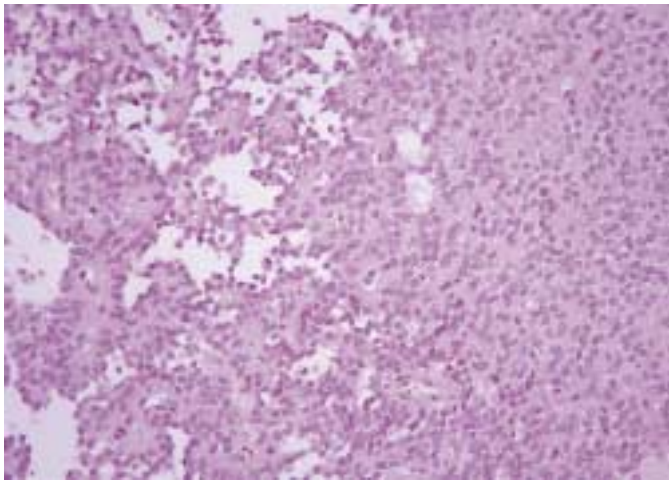

Figure **2** Histology showing a solid monomorphic proliferation of uniform cells often separated by fibrous stroma. Note the low mitotic rate. Similar cells surrounding fibrovascular stalks give the tumor a pseudopapillary architecture (hematoxylin–eosin, original magnification × 40).

This document was downloaded for personal use only. Unauthorized distribution is strictly prohibited.

EUS made it possible to delineate several typical SPT features, including the mixture of cystic and solid components in a well-demarcated tumor, as well as partial calcification. FNA provided the definitive diagnosis. This case underscores the value of EUS/FNA in the evaluation of patients with pancreatic lesions of unclear etiology.

K. Mergener, S. E. Detweiler, L. W. Traverso
Virginia Mason Medical Center, Seattle, Washington, USA.

References

1 Frantz VK. Tumors of the pancreas. In: Frantz VK (ed). Atlas of tumor pathology.Washington, DC: Armed Forces Institute of Pathology 1959: 32 – 33
2 Martin RC, Klimstra DS, Brennan MF, Conlon KC. Solid-pseudopapillary tumor of the pancreas: a surgical enigma? Ann Surg Oncol 2002; 9: 35 – 40
3 Washington K. Solid-pseudopapillary tumor of the pancreas: challenges presented by an unusual pancreatic neoplasm. Ann Surg Oncol 2002; 9: 3 – 4
4 Tanaka Y, Kato K, Notohara K et al. Frequent beta-catenin mutation and cytoplasmic/nuclear accumulation in pancreatic solid-pseudopapillary neoplasm. Cancer Res 2001; 61: 8401 – 8404
5 Abraham SC, Klimstra DS, Wilentz RE et al. Solid-pseudopapillary tumors of the pancreas are genetically distinct from pancreatic ductal adenocarcinomas and almost always harbor beta-catenin mutations. Am J Pathol 2002; 160: 1361 – 1369

Corresponding Author

K. Mergener, M.D., F.A.C.P., F.A.C.G.
Digestive Health Specialists
1901 South Union Street, B-4006
Tacoma, WA 98405
USA
Fax: +1-253-572-8204
E-mail: Klausmergener@aol.com

This document was downloaded for personal use only. Unauthorized distribution is strictly prohibited.