Ectopic Drainage of the Common Bile Duct into the Duodenal Bulb: Report of Two Cases

UCTN

During endoscopic retrograde cholangiopancreatography (ERCP) in a 52-year-old man with acute cholangitis, the major papilla could not be found, but a slit-like bile-stained orifice was present at the anterior part of the deformed bulb. Dilatation of the biliary tree was seen and a 7-Fr plastic stent was introduced to drain the biliary system (Figure **1**). Clinical resolution was obtained within a few days, and the patient remained asymptomatic at 5 months after the procedure.

In a 38-year-old woman with acute cholangitis, ERCP was successful via cannulation of an orifice 5 mm in diameter located at the anterior surface of the deformed bulb. Dilatation of the biliary ducts was seen on cholangiography. The distal part of the common bile duct appeared hook-like and tapered (Figure **2**). Some sludge was removed using a balloon catheter. After cleansing of the common bile duct, the patient's condition improved in the following days and did not recur over a 2-year follow-up.

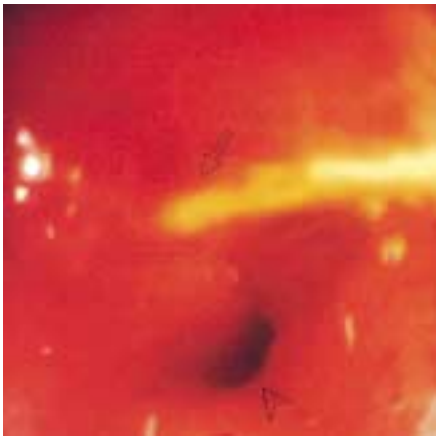

Figure 1 Endoscopic view showing the location of the ectopic orifice on the bulb (arrow), and a plastic biliary stent draining through it. The duodenal lumen is narrow (arrowhead).

There have been a few reported cases in which the common bile duct has been found to empty into the duodenal bulb [1–3]. Such cases usually presented with cholangitis, however like ours, most of the patients described have had a history of duodenal ulcer. In our opinion, the constant exposure to bile acid in the duodenal bulb leads to the peptic ulcer. This may explain the occurrence of cholangitis at later stage, when the duodenal bulb is severely deformed because of the repeated attacks.

The ectopic opening is usually a small or slit-like orifice, while a normal papilla is rarely seen. On cholangiography, the dilated common bile duct shows a tapered narrowing and a hook-shaped distal end in 75% of cases [2–5]. The primary therapy should be ERCP-related measures, such as balloon catheterization or stenting [3]. Endoscopic sphincterotomy should be avoided because of the risk of perforation.

Figure 2 Endoscopic retrograde cholangiopancreatography (ERCP) shows the diffuse dilatation of the biliary tree and the hook-like ending of the common bile duct (arrowhead).

E. Özaslan [1], Ü. Sarıtaş [1], G. Tatar [2], H. Şimşek [2]

[1] Department of Gastroenterology, Numune Education and Training Hospital, Ankara, Turkey

[2] Department of Gastroenterology, Hacettepe University Faculty of Medicine, Ankara, Turkey

References

[1] Adkins RB, Chapman WC, Reddy VS. Embryology, anatomy, and surgical applications of the extrahepatic biliary system. Surg Clin N Am 2000; 80: 363–379

[2] Lee HJ, Ha HK, Kim MH et al. ERCP and CT findings of ectopic drainage of the common bile duct into the duodenal bulb. Am J Roentgenol 1997; 169: 517–520

[3] Altıparmak E, Kosar Y, Gurkaynak G et al. Biliary opening anomalies (ectopic drainage): a report of seven cases. Turk J Gastroenterol 2001; 12: 228–232

[4] Yamamoto S, Iguchi Y, Ohmoto K et al. Abnormal openings of the common bile duct into the duodenum. Am J Gastroenterol 1994; 89: 1124–1125

[5] Kubota T, Fujioka T, Honda S et al. The papilla of Vater emptying into duodenal bulb. Jpn J Med 1988; 27: 79–82

Corresponding Author

E. Özaslan, M.D.

Department of Gastroenterology
Numune Education and
Training Hospital
Ileri Mah. Mektep Sok. No: 7/10
Kurtulus
06660 Ankara
Turkey
Fax: +90-312-3103460
E-mail: er72@hotmail.com

This document was downloaded for personal use only. Unauthorized distribution is strictly prohibited.