

**W. Bohle, W. G. Zoller**

Department of Gastroenterology,  
Katharinenhospital Stuttgart, Stuttgart,  
Germany

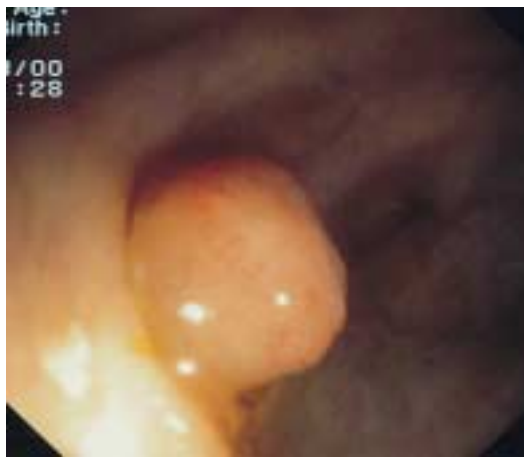## Corresponding Author

**W. Bohle, M.D.**

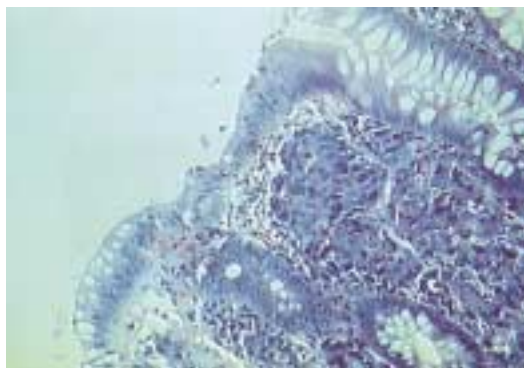
Department of Gastroenterology  
Katharinenhospital Stuttgart  
Kriegsbergstrasse 60  
70174 Stuttgart  
Germany

Fax: +49-711-2785401

E-mail: W.Bohle@katharinenhospital.de



**Figure 1** An 81-year-old man presenting with general weakness and anemia, underwent colonoscopy because of a positive hemocult test. During the examination, several small, sometimes centrally eroded polyps, measuring 6–8 mm in diameter, were found.



**Figure 2** Histological analysis revealed submucosal metastatic spread of an adenocarcinoma, incompletely covered by normal mucosa. Gastroscopy revealed an adeno-squamous carcinoma of the esophagogastric junction to be the primary tumor. The patient refused further treatment and died several weeks later.