Use of an Endoscopic Clipping Device to Repair a Duodenal Perforation

A frank perforation of the upper gastrointestinal tract is usually repaired surgically. With the advent of endoscopic clipping devices, patients with gastric [1], duodenal [2], and colonic [3,4] perforations have been treated endoscopically. We report the successful use of an endoscopic clipping device to treat a duodenal perforation that occurred during an endoscopic ultrasound examination.

A 78-year-old white woman with weight loss, abdominal pain, and an enlarged pancreatic head on computerized axial tomography scan, underwent an endoscopic ultrasound examination (Pentax 3630U). No mass was noted during the initial endoscopic ultrasound survey; however, on reintubation of the descending duodenum, a frank perforation occurred. Evaluation of the bulb with a panendoscope (Pentax EG-3440) revealed a 6-mm slit-like perforation site (Figure **1 a**). Three endoclips were successfully applied to reapproximate the mucosal surface of the perforation. Two additional clips were then placed beneath the initial clips (Figure **1 b**). A nasogastric tube was inserted and treatment with broad-spectrum antibiotics was begun. No signs of peritonitis developed. A gastrograffin swallow performed 1 day later showed no evidence of perforation other than intra-abdominal free air. At 1 month after discharge the patient underwent uneventful laparoscopic cholecystectomy.

Despite the endoscope's 12-mm diameter, 4 cm rigid tip, and oblique viewing angle, perforation of a viscus during an endoscopic ultrasound examination is an infrequent occurrence [5]. Following a perforation, there is usually minimal peritoneal soiling if the perforation is closed promptly. Because of some concern about early clip migration, which would result in a reopening of the defect, the mucosa was first approximated with three clips, then two additional clips were placed beneath these, presumably deeply into the submucosa. For a select group of patients with a high surgical risk, the clinician's familiarity with the use of endoclips, and their immediate availability and proper deployment, can avoid a laparotomy when a small, well-visualized perforation occurs during endoscopy.

D. G. Seibert
RC Byrd HSC, West Virginia University, Morgantown, West Virginia, USA

References

[1] Binmoeller KF. Endoscopic closure of a perforation using metallic clips after snare excision of a gastric leiomyoma. Gastrointest Endosc 1993; 39: 172 – 174

[2] Baron TH, Gostout CJ, Herman L. Hemoclip repair of a sphincterotomy-induced duodenal perforation. Gastrointest Endosc 2000; 52: 566 – 568

[3] Yoshikane H, Hidano H, Sakakibara A et al. Endoscopic repair by clipping of an iatrogenic colonic perforation. Gastrointest Endosc 1997; 46: 464 – 466

[4] Mana F, de Vogelaere K, Urban D. Iatrogenic perforation of the colon during diagnostic colonoscopy: endoscopic treatment with clips. Gastrointest Endosc 2001; 54: 258 – 259

[5] Rösch T, Dittler HJ, Fockens P et al. Major complications of endoscopic ultrasonography: results of a survey of 42 105 cases (abstract). Gastrointest Endosc 1993; 39 : 341

Corresponding Author

D. G. Seibert, M.D.
Department of Medicine
Box 9161
RC Byrd HSC
Morgantown
WV 26506-9161
USA
Fax: + 1-304-293-2135
E-mail: dseibert@hsc.wvu.edu

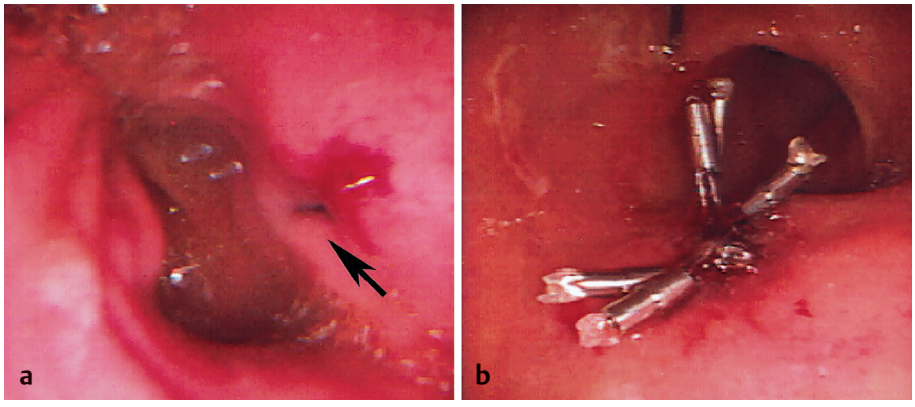

Figure 1 **a** At the apex of the duodenal bulb a perforation (arrow) can be seen. **b** Five endoclips have been placed, closing the perforation. In the background an additional clip is lying unattached.

This document was downloaded for personal use only. Unauthorized distribution is strictly prohibited.