

Biliary stent exchange is usually performed in two steps: 1) removal of the occluded stent using either a snare or a rat-tooth forceps, and 2) placement of a new biliary stent. However, in cases of complicated strictures, recannulation of the stricture may be difficult or even impossible. The Soehendra stent retriever was designed to avoid such problems and guarantee stent replacement. Those using this device for replacing an occluded stent may, however, encounter difficulties in inserting the guide wire into the stent and advancing the retriever over the guide wire to engage the distal end of the stent. This drawback has recently been eliminated by modifying the tip of the retriever (Figures 1 and 2.)

In order to replace an occluded 10-French or 11.5-French plastic stent, the Soehendra stent retriever can now be inserted together with a 400-cm 0.035-inch Teflon-coated guide wire or other hydrophilic wire. The addition of a curved plastic tip significantly facilitates the cannulation of the occluded stent and the insertion of the guide wire (SSR-10-T or SSR-11.5-T; Wilson-Cook, Winston-Salem, North Carolina, USA). The retriever can then easily be coupled and screwed into the distal end of the stent. The stent is withdrawn leaving the guide wire in place, ensuring that a new stent can be placed.

Plastic stents made of polyethylene tend to become softer after a few months, and so the tip of the retriever may not anchor properly in the distal end of the stent,




Figure 1 A 2.5 cm long 5-French curved catheter is mounted on the tip of the retriever, to facilitate the engagement of the retriever with the distal end of the stent and thereby the insertion of the guide wire into the stent.

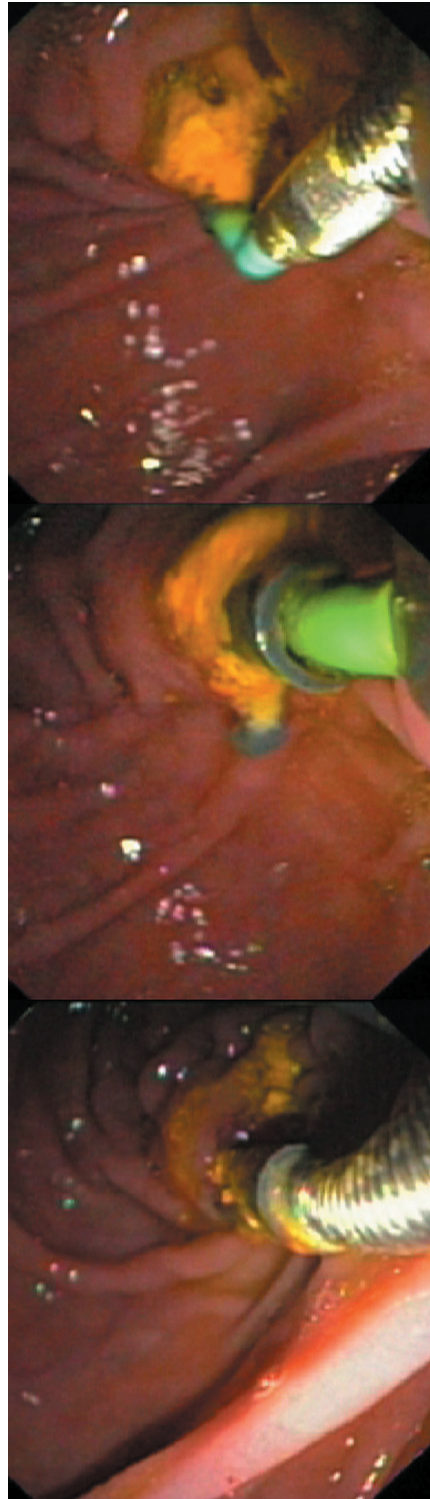


Figure 2 Endoscopic view showing the coupling of the retriever with the distal end of the occluded stent. The guide wire is then advanced.

causing failure of stent retrieval. In such cases, an 11.5-French retriever should be used for removal of a 10-French polyethylene stent.

So far, we have used the modified stent retriever to replace occluded biliary stent in 20 procedures. In all cases, the procedure was successful and uneventful. The use of the new retriever for replacing 10-French or 11.5-French plastic stents has become an easy procedure, even for trainees.

**U. Seitz, S. Seewald, X. He,
T. Akaraviputh, F. Thonke, N. Soehendra**
Dept. of Interdisciplinary Endoscopy,
University Hospital Hamburg-Eppendorf,
Germany

Corresponding Author

U. Seitz, M.D.
Dept. of Interdisciplinary Endoscopy
University Hospital Hamburg-Eppendorf
University of Hospital
Martinistr. 52
20246 Hamburg
Germany
Fax: +49-40-428034420
E-mail: seitz@uke.uni-hamburg.de