

Endoscopic Band Ligation for Rectal Dieulafoy's Lesion: Serial Endoscopic Images

Y. Mizukami¹, K. Akahoshi¹, N. Kondoh¹,
N. Harada², H. Nawata¹

¹ Department of Gastroenterology,
Aso Iizuka Hospital, Iizuka, Japan

² Third Department of Internal Medicine,
Faculty of Medicine, Kyushu University,
Fukuoka, Japan

Corresponding Author

K. Akahoshi, M.D., Ph.D.

Department of Gastroenterology
Aso Iizuka Hospital

3-83 Yoshio

Iizuka 820-8505

Japan

Fax: +81-948-298747

E-mail: kakahoshih1@aih-net.com

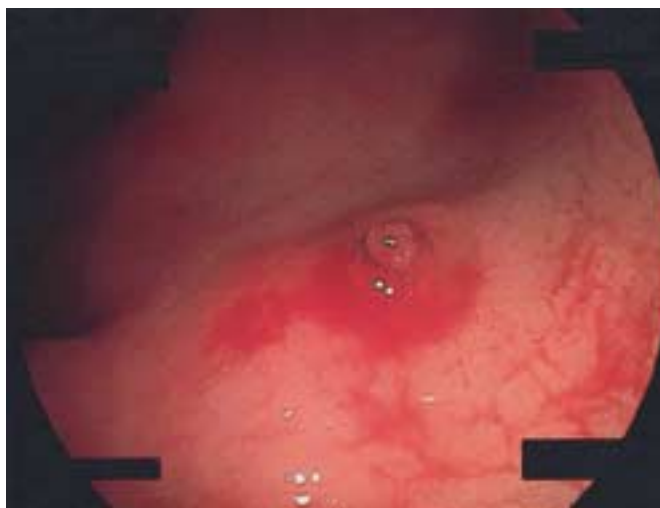

Figure 1 An 85-year-old Japanese woman with rectal Dieulafoy's lesion presented with fresh blood hematochezia. Colonoscopy revealed a 5 mm shallow mucosal defect with an exposed vessel in the anterior wall of the lower rectum.

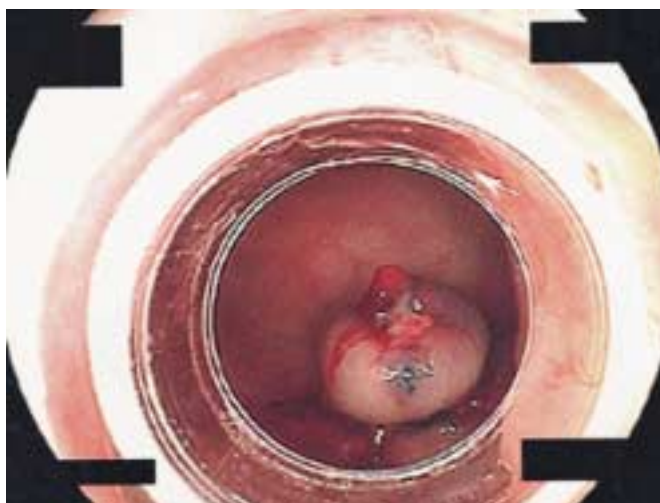


Figure 2 A gastro-duodenoscope with an attached single-band ligator was employed, and 4 ml of hypertonic saline epinephrine solution was injected beneath the lesion. After endoscopic band placement, the hemorrhage stopped completely. Note that the Dieulafoy's lesion had been wholly encased by the band.

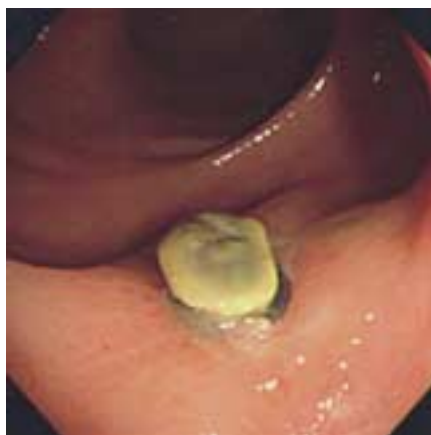

Figure 3 Endoscopy at 1 week after the procedure revealed a 10 mm wide shallow ulcer at the site of the lesion. The O-ring remained on the ulcerated lesion.

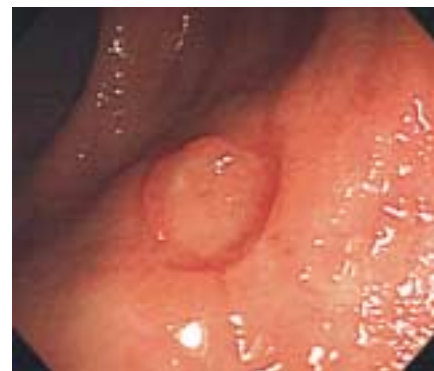

Figure 4 Follow-up colonoscopy (at 2 weeks) showed an ulcer scarring. No further bleeding has occurred during 6 months of follow-up.