

B. Kayhan, M. Akdoğan, O. Sezgin,
S. Dişibeyaz, B. Şahin
Department of Gastroenterology,
TYIH, Ankara, Turkey

Corresponding Author

B. Kayhan, M.D.
Department of Gastroenterology
TYIH
P.K. 203
06443 Yenışehir
Ankara
Turkey
E-mail: burkaygastro@hotmail.com

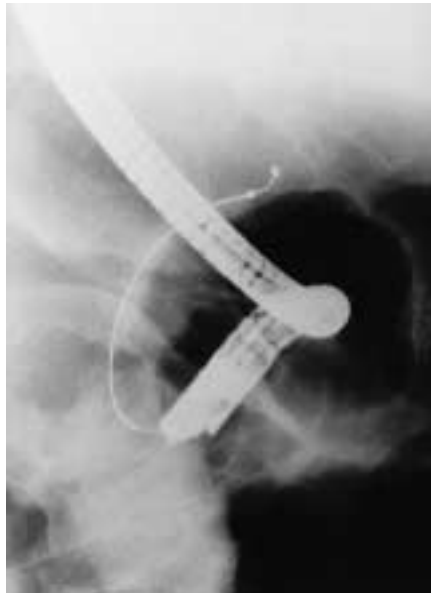


Figure 1 A 56-year-old man was diagnosed with distal cholangiocellular carcinoma, and treatment with placement of a biliary stent by endoscopic retrograde cholangiopancreatography (ERCP) was planned. After the selective cannulization of the common bile duct, we tried to find a way through to the mass with a black guide-wire, but the tip of the guide-wire became knotted. The knot was recognised at fluoroscopy



Figure 2 The knotting was probably caused by reuse of a disposable guide-wire