

The endoprosthesis materials currently in use, with low friction coefficients maintaining biliary passage, are Teflon, polyethylene, polyurethane, and Percuflex catheters. In order to reduce the obstruction and displacement rates, expandable metal stents have been developed and tested in cases of malignant biliary disease [1–5]. Self-expanding metallic stents create an expansion force that gives them the required diameter after they are placed in the stricture (Figure 1). This case report emphasizes the need for careful placement of metallic stents in order to avoid the complication of intestinal wall erosion.

A 58-year-old man was referred with jaundice, weight loss, vomiting, and pain. The cytological findings after a gastrojejunoscopic biopsy revealed a lower biliary neoplasm, with routine biochemical and radiological investigations. A pyloric-preserving Whipple operation was carried out. Five months after the operation, a self-expanding biliary Wallstent was placed, due to the development of biliary obstruction. On the fifth day after the stent had been placed, abdominal pain started. While the cause of the pain was still being investigated, gastrointestinal

bleeding of more than five units occurred on the fifteenth day after stent placement, reducing the patient's hematocrit to 30% from 42% (Figure 2). An endoscopic examination revealed an ulcer crater traversing the choledochojejunal anastomosis, caused by stent irritation of the opposite intestinal wall. The Wallstent was removed, and no further mishaps occurred after its removal. Twenty days after it had been removed, the patient died of sepsis. Proper stent placement is thus essential in order to avoid fatal complications.

M. Balkan, O. Kozak, I. Arslan, F. Alpasian

Department of Surgery,
Gülhane Military Medical Academy,
Ankara, Turkey

References

- ¹ Gillams A, Dick R, Rooley JS, Wallsten H, El-Din A. Self-expandable stainless steel braided endoprosthesis for biliary strictures. *Radiology* 1990; 174: 137–140
- ² Gottlieb K, Sherman S, Lehman GA. Therapeutic biliary endoscopy. *Endoscopy* 1996; 28: 113–130

³ Schöfl R, Brownstone E, Reichel W, Fommat W, Doblhofer F, Samec HJ et al. Malignant bile duct obstruction: experience with self-expanding metal endoprostheses (Wallstents) in Austria. *Endoscopy* 1994; 26: 592–596

⁴ Hoepffner N, Foerster EC, Högemann B, Domschke W. Long-term experience in Wallstent therapy for malignant choledochal stenosis. *Endoscopy* 1994; 26: 597–602

⁵ Van Berkel AM, Bergman JJGHM, Waxman I, Andres P, Huibregtse K. Wallstents for malignant biliary obstruction. *Endoscopy* 1996; 28: 418–421

Corresponding Author

M. Balkan, M.D.

Department of Surgery
Gülhane Military Medical Academy
Etilik 06018
Ankara
Turkey
Fax: +90-312-3045002
E-mail: mujdatbalkan@yahoo.com

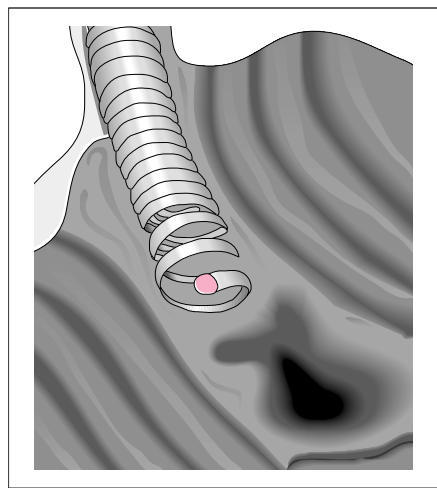


Figure 1 Expandable metal stent made of constricted round steel wire with a diameter of 0.018 inches

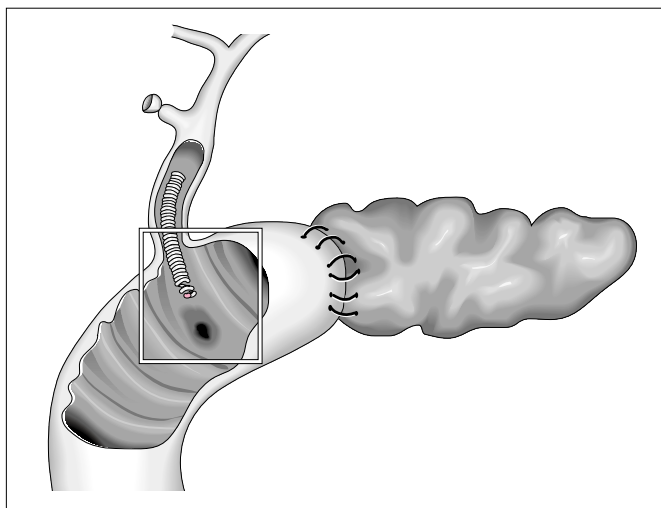


Figure 2 Stent-induced bleeding in an erosion on the jejunal wall