

Diminutive but Dangerous: A Case of a Polypoid Rectal Arteriovenous Malformation

UCTN

Arteriovenous malformations (AVMs) of the gastrointestinal tract – entities that are distinct from angiodysplasia and venous varices – present with acute blood loss or chronic anemia. They have been reported in both the upper and lower gastrointestinal tract after hemorrhage, or are found incidentally. However, polypoid AVMs are unusual, with only seven cases having been reported to date [1–5], three of which were colonic.

A 24-year-old healthy Oriental male presented with hematochezia. Flexible sigmoidoscopy revealed blood and feces throughout the left colon. A ⁹⁹Tc red blood cell scan disclosed active bleeding in the rectosigmoid region. Repeat endoscopy revealed active bleeding in the rectum, coming from a 7-mm polypoid lesion (Figure 1). Hemostasis was achieved after injecting 3 ml of 1:10 000 epinephrine at the base and tip of the lesion. At a repeat sigmoidoscopy three days later, the lesion was snared and cauterized. The histological findings were diagnostic for an AVM (Figure 2). There has been no further bleeding.

Previously reported noncolonic polypoid AVMs have included lesions in the mid-ileum [1] and stomach [2,3]. Koziara et al. [4] reported the first polypoid colonic AVMs in the sigmoid and transverse colons. More recently, Park et al. [5] de-

scribed a 1-cm pedunculated polyp in the descending colon causing massive bleeding. The patient with hematochezia whose case is reported here is both the youngest with a polypoid colonic AVM so far reported, and the only reported rectal case. The patient was Korean, as was the patient reported by Park et al. [5]. No conclusions concerning any ethnic predisposition can be made for this rare entity on the basis of only two reports, but it is curious that both shared the same ethnicity.

The size of lesions that can be safely transected using endoscopic snare polypectomy is not known. It has been suggested that vessels >1 mm in diameter should be treated with caution [4], although Koziara et al. [4] reported safely transecting vessels of 3 mm. In our experience, it is important to exercise caution when carrying out polypectomy on a suspected vascular lesion.

**E. C. McKeivitt¹, A. J. Attwell²,
J. E. Davis³, E. M. Yoshida²**

¹ Dept. of Surgery, University of British Columbia, Vancouver, Canada

² Dept. of Medicine, University of British Columbia, Vancouver, Canada

³ Dept. of Pathology, University of British Columbia, Vancouver, Canada

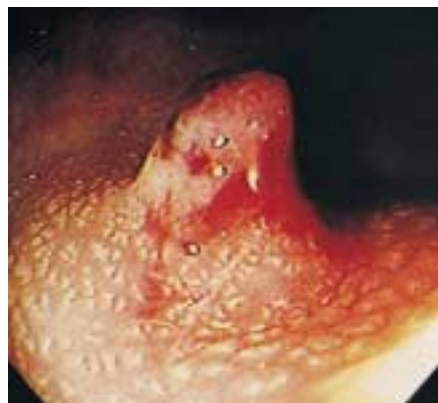

Figure 1 Colonoscopic view of the bleeding rectal lesion after basal injection of 1 ml of 1:10 000 epinephrine

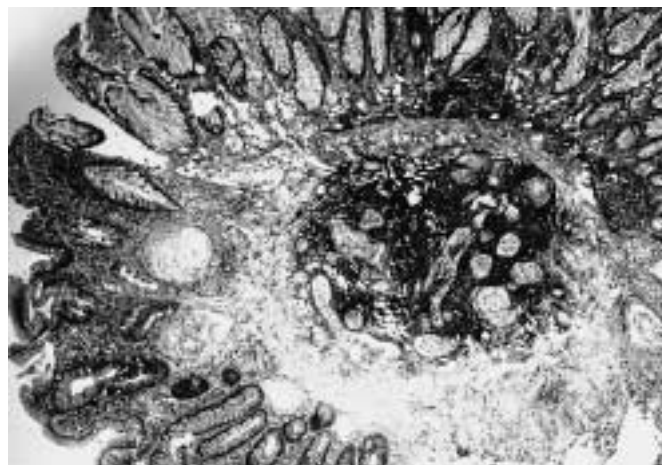


Figure 2 Photomicrograph of the polypectomy specimen, showing a collection of thick and thin-walled blood vessels in the submucosa, with extension into the lamina propria (elastic stain, original magnification $\times 50$)

References

- ¹ Kwasnik EM, Tahan SR, Lowell JA, Weinstein B. Neuromuscular and vascular hamartoma of the small bowel. *Dig Dis Sci* 1989; 34: 108–110
- ² Kaler SG, Westman JA, Bernes SM et al. Gastrointestinal hemorrhage associated with gastric polyps in Menkes disease. *J Pediatr* 1993; 122: 93–95
- ³ Tio TL, Tytgat GN. Endoscopic ultrasonography of an arteriovenous malformation in a gastric polyp. *Endoscopy* 1986; 18: 156–158
- ⁴ Koziara FJ, Brodmerkel GJ, Boylan JJ et al. Bleeding from polypoid colonic arteriovenous malformations. *Am J Gastroenterol* 1996; 91: 584–586
- ⁵ Park ER, Yang SK, Jung SA et al. A case of pedunculated arteriovenous malformation presenting with massive hematochezia. *Gastrointest Endosc* 2000; 51: 96–97

Corresponding Author

E. M. Yoshida, M.D., F.R.C.P.C.

Division of Gastroenterology
Vancouver General Hospital
100–2647 Willow Street
Vancouver, British Columbia V5Z 3P1
Canada

Fax: +1-604-875-5371

E-mail: e-yoshida@interchange.ubc.ca