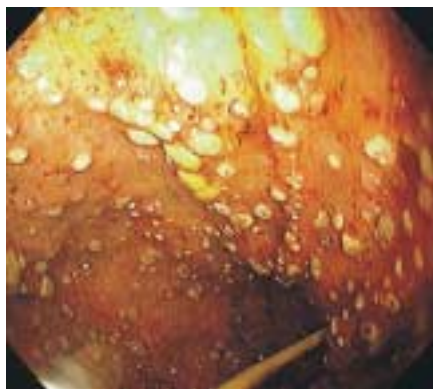


# Upper Gastrointestinal Bleeding From Leukemic Gastric Implants

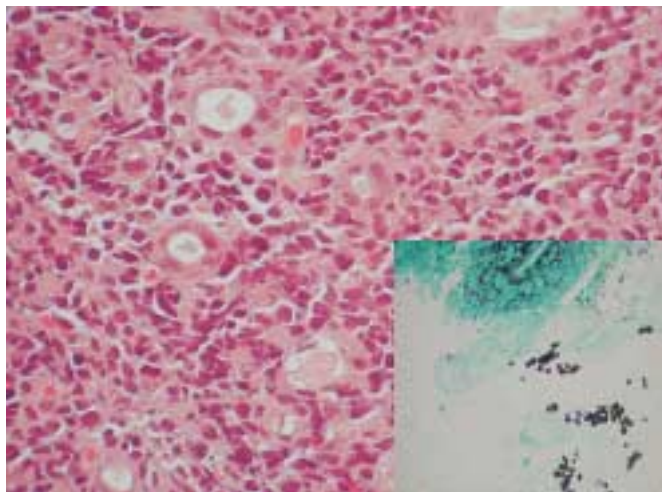
J. Nackley II, J. Barthel, D. Coppola  
Moffitt Cancer Center, University  
of South Florida, Tampa, Florida, USA

## Corresponding Author

J. Nackley II, M.D.  
University of South Florida  
Office of James S. Barthel, M.D.  
Moffitt Cancer Center  
12902 Magnolia Drive  
Tampa, FL 33612  
USA  
Fax: + 1-813-979-7229  
E-mail: barthejs@moffitt.usf.edu



**Figure 1** A 23-year-old woman admitted with an acute myelogenous leukemic blast crisis, developed thrombocytopenia, melena, and anemia. An esophagogastroduodenoscopy was performed, revealing an erythematous, friable mucosa with multiple white plaques lining the entire gastric mucosa. A small feeding tube was in place



**Figure 2** The stomach biopsy revealed fragments of ulcerated gastric mucosa involved by a marked leukemic infiltrate which was focally replacing the gastric pits. A special stain for fungi (GMS) revealed fungal forms within the fibrinopurulent exudate (hematoxylin and eosin  $\times 250$ ; GMS stain  $\times 100$ )