

Patient G. L. presented with a short bowel (40 cm) and chronic intestinal obstruction syndrome as the outcome of a gastroschisis complicated by an extensive necrotic bowel. He remained on total parenteral nutrition and need of continuous nasogastric decompression. When he was 6 months old it was decided to perform a percutaneous endoscopic gastrostomy (PEG) [1]. Since the small bowel remained both hypoperistaltic and dilated, a percutaneous endoscopic jejunostomy (PEJ) was also scheduled. As three previous laparotomy procedures had been done, it was decided to place the percutaneous jejunostomy so as to avoid further laparotomies and the risk of bowel resection. The PEJ (CH12 French) was performed first (Corflo; Ansell Medical, Cergy Pontoise, France). Catheterization of the bowel was easy because of its shortness and dilation and the PEJ was done 5 cm above the jejuno-colic anastomosis. PEG (CH16 French) was performed in the antrum-corpus junction. The outcome was the resolution of the intestinal obstruction. The jejunostomy tube remained in place for 7 months, with no complication. Endoscopic removal of the damaged jejunostomy tube was complicated by pneu-

moperitonitis and local peritonitis. The patient was discharged 4 weeks later with a closed jejunostomy and a decompression gastrostomy button. At the age of 19 months, the patient had a favourable course, with daily home parenteral nutrition along with limited food intake (20% of daily intake).

The use of combined PEJ and PEG has not yet been reported. However, adult percutaneous endoscopic colostomy or cecostomy has been used [2,3]. In our patient, PEJ offered a better alternative than surgical jejunostomy and was effective for bowel decompression. The complications associated with removal of the jejunostomy tube were probably secondary to insufflation which produced distension followed by a tearing of ileoperitoneal adhesions. In patients with a short bowel and severe intestinal obstruction, PEJ seems to be an effective technique for digestive decompression.

**S. Auvin<sup>1</sup>, L. Michaud<sup>1</sup>, D. Guimber<sup>1</sup>, R. Sfeir<sup>2</sup>, F. Gottrand<sup>1</sup>, D. Turck<sup>1</sup>**

<sup>1</sup> Division of Gastroenterology, Hepatology and Nutrition, Department of Pediatrics,

Lille University Children's Hospital and Faculty of Medicine, Lille, France

<sup>2</sup> Department of Pediatric Surgery, Lille University Children's Hospital and Faculty of Medicine, Lille, France

## References

- <sup>1</sup> Michaud L, Guimber D, Carpentier B et al. Gastrostomy as a decompression technique in children with chronic gastrointestinal obstruction. *J Pediatr Gastroenterol Nutr* 2001; 32: 82–85
- <sup>2</sup> Daniels IR, Lamparelli MJ, Chave H et al. Recurrent sigmoid volvulus treated by percutaneous endoscopic colostomy. *Br J Surg* 2000; 87: 1419
- <sup>3</sup> Ponsky JL, Aszodi A, Perse D. Percutaneous endoscopic cecostomy: a new approach to nonobstructive colonic dilation. *Gastrointest Endosc* 1986; 32: 108–111

## Corresponding Author

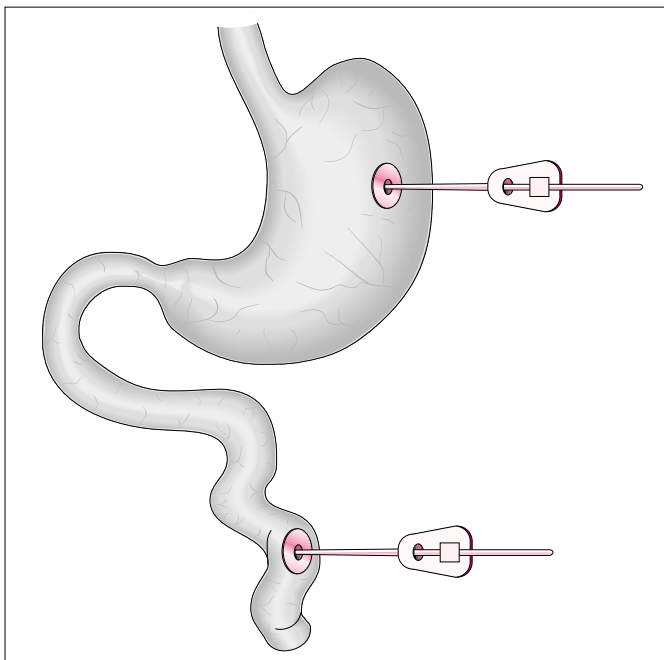
L. Michaud, M.D.

Unité de Gastroentérologie  
Hépatologie et Nutrition  
Clinique de Pédiatrie  
Hôpital Jeanne de Flandre  
2 Avenue Oscar Lambret  
59037 Lille

France

Fax: +33-3-20445969

E-mail: l-michaud@chru-lille.fr



**Figure 1** Positions of the percutaneous endoscopic gastrostomy (PEG) and percutaneous endoscopic jejunostomy (PEJ) in our patient