

Submucosal tumors (SMTs) in the digestive tract include neoplastic and non-neoplastic lesions. Attempts have been made to grade the severity of mesenchymal tumors pathologically, using various criteria for malignancy, such as tumor size, cellularity, mitotic index, and DNA content [1]. We recently treated a patient with a malignant gastrointestinal stromal tumor (GIST), and describe an interesting diagnostic pitfall which arose from the use of endoscopic ultrasonography for follow-up examination after the operation.

A 67-year-old woman was referred to our hospital for detailed investigation of an SMT of the upper stomach. Ultrasonography showed that the tumor was 80 mm in diameter and had an internal echo pattern of mixed irregular type. These findings matched positive signs of malignancy, which had met the diagnostic criteria for malignant SMT. A proximal gastrectomy was performed. The surgically resected tumor was 92 × 80 × 65 mm in diameter, and the surgical margin was free of tumor cells. The cellularity of the tumor was high, and a mitotic index of 1–3/1HPF was noted. Immunohistochemical staining gave results of s-100 protein-negative, actin-negative, c-kit-positive, and CD34-positive. Based on these pathological findings, the tumor was diagnosed as a GIST, uncommitted type or Cajal cell type, with low-grade malignancy. At 9

months after gastrectomy, follow-up endoscopic examination revealed two SMTs in the stomach remnant, which were 15 mm and 20 mm in diameter (Figure 1). With regard to the larger tumor, endoscopic ultrasonography revealed an echolucent submucosal mass arising from the fourth echolayer, the muscularis propria of the gastric wall. The tumor expanded with notched sign (Figure 2). These findings suggested that the lesions were recurrent or multiple aberrant GISTs with malignant potential. A total gastrectomy was performed. Histological examination showed that both of the resected tumors were foreign body granulomas composed of suture silk.

Thus the second operation turned out to be an overtreatment.

According to previous reports, 25% of all GISTs develop local recurrence and 33% develop distant recurrences; GISTs with more than one mitosis and size larger than 5 cm have an especially poor prognosis [2]. Depending on tumor size and prognostic parameters, an individual follow-up with endoscopic and radiological examination is recommended. Despite the misjudgement in our case, this is an interesting diagnostic pitfall which arose from using endoscopic ultrasonography for the follow-up examination.

H. Kimura<sup>1</sup>, Y. Shima<sup>1</sup>, S. Kinoshita<sup>1</sup>, I. Takahashi<sup>1</sup>, T. Okai<sup>2</sup>

<sup>1</sup> Department of Surgery, Yamanaka National Hospital, Ishikawa, Japan

<sup>2</sup> Department of Internal Medicine, Cancer Research Institute, Kanazawa University, Ishikawa, Japan

## References

- Kimura H, Yonemura Y, Kadoya N et al. Prognostic factors in primary gastrointestinal leiomyosarcoma. A retrospective study. *World J Surg* 1991; 15: 771–777
- Pierie JP, Choudry U, Muzikansky A et al. The effect of surgery and grade on outcome of gastrointestinal stromal tumors. *Arch Surg* 2001; 136: 383–389

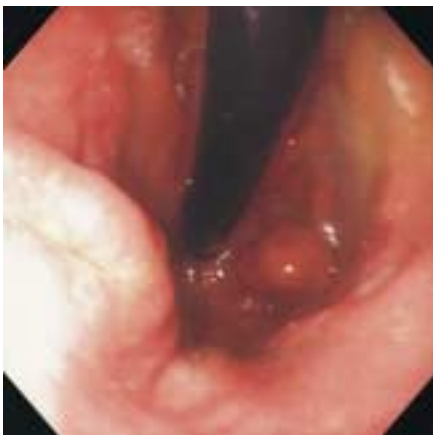## Corresponding Author

H. Kimura, M.D.

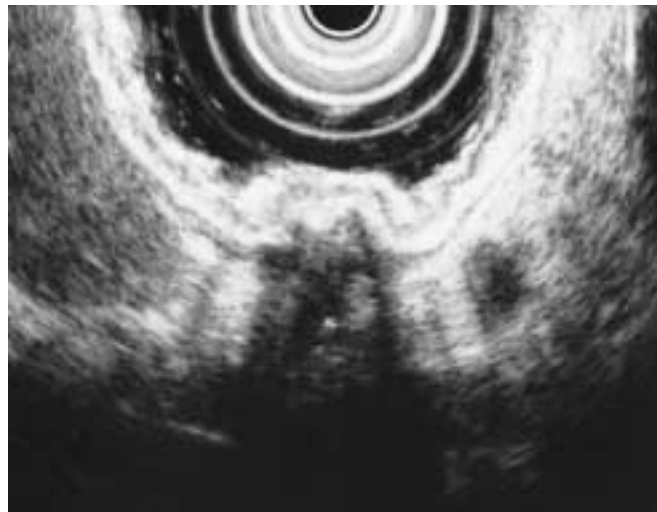
Department of Surgery  
Yamanaka National Hospital  
15-1, Uenomachi, Yamanaka-machi  
Enuma-gun, Ishikawa, 922-0193  
Japan

Fax: +81-761-785234

E-mail: kimu-chan@mtb.biglobe.ne.jp



**Figure 1** Endoscopic finding of two submucosal tumors in the remnant stomach



**Figure 2** Ultrasonography demonstrated a mixed irregular echo pattern