

Duodenocolic Fistula: An Unusual Sequela of Stent Migration

Approximately 15% of pancreatic head cancers are resectable at the time of presentation [1]. In the remaining patients, successful palliation is the only realistic goal, for achieving a comfortable survival [2]. Although endoscopic stenting to relieve biliary obstruction is an attractive option, with a high success rate, and relatively lower procedural morbidity and shorter hospital stay [3], it has its own complications. A restriction of stent mobility in the duodenum, as in the case of a tumor, may result in pressure necrosis of the duodenal wall, causing perforation [4]. Stent-related duodenocolic fistula usually presents with hepatobiliary sepsis, secondary to colonization of the stent and biliary tree with colonic flora [5]. We present an unusual and interesting case of silent duodenocolic fistula resulting from stent migration.

A 43-year-old lady underwent cholecystojejunostomy and jejunojejunostomy in February 1998 for a locoregionally advanced neuroendocrine tumor of the pancreatic head. Follow-up was uneventful for 14 months following surgery, then the patient again developed jaundice. Endoscopic retrograde cholangiography (ERC) suggested a blocked cholecystojejunostomy, as the opacified gallbladder was not draining into the jejunal loop. A 10-F Teflon stent was placed after papillotomy. The patient's serum bilirubin level came down to within normal limits and had remained so when we saw her 6 months later. However, her abdominal computed tomography (CT) scan showed the lower end of the stent in the ascending colon, with no intrahepatic dilatation (Figure 1), and a 5.5-cm mass in the head of pancreas indenting the inferior vena cava and encasing the portal vein and superior mesenteric artery. Duodenoscopy showed the stent to have perforated the lateral wall of the duodenum. On colonoscopy, the stent was found to have entered the hepatic flexure of the colon, and it was retrieved using forceps. A new 10-F Teflon stent was placed after a check cholangiography. The patient was asymptomatic at the time of her last visit in June 2000.

K. A. Pathak, L. J. de Souza
G. I. Service, Department of Surgery,
Tata Memorial Hospital, Mumbai, India

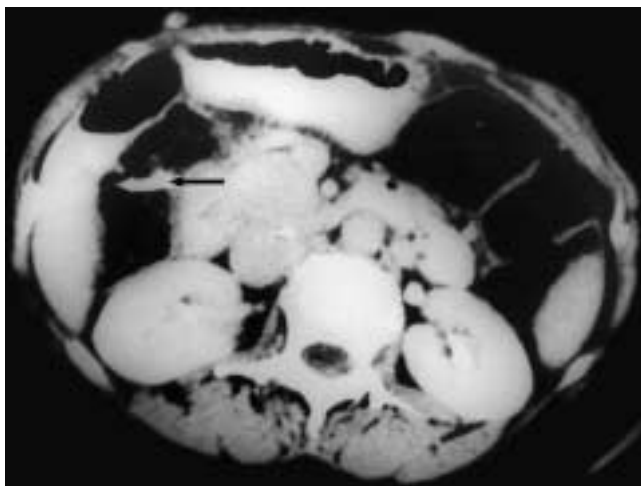


Figure 1 Axial computed tomography (CT) scan of the abdomen; arrow indicates perforated stent in colon

References

- ¹ Watanpa P, Williamson RCN. Surgical palliation for pancreatic carcinoma: developments during the past two decades. *Br J Surg* 1992; 79: 8–20
- ² Scarr MG, Cameron JL. Surgical management of unresectable carcinoma. *Surgery* 1981; 91: 123–133
- ³ Lichtenstein DR, Carr-Locke DL. Endoscopic palliation for unresectable pancreatic carcinoma. *Surg Clin N Am* 1995; 75 (5): 969–988
- ⁴ Gould J, Tram JS, Dan SJ, Mitty HA. Duodenal perforation as a delayed complication of placement of biliary endoprosthesis. *Radiology* 1998; 167: 467–469
- ⁵ Ang BK, Wee SB, Kaushik SP, Low CH. Duodenal–colic fistula resulting from migration of a biliary stent: a case report. *Gastrointest Endosc* 1998; 48 (1): 80–83

Corresponding Author
K. A. Pathak, M.D.

Dept. of Surgery
Tata Memorial Hospital
Dr. E. Borges Road
Parel
Mumbai 400 012
India

Fax: +91-22-4146937
E-mail: kapathak@yahoo.com