Cytomegalovirus Acute Necrotizing Esophagitis

E. Barjas [1], S. Pires [1], J. Lopes [1], A. Valente [1], E. Oliveira [2], R. Palma [1], M. Raimundo [1], P. Alexandrino [1], M. C. Moura [1]

[1] Serviço de Medicina II, Unidade de Cuidados Intensivos de Gastroenterologia e Hepatologia (UCIGE-H), Hospital de Santa Maria, Lisbon, Portugal
[2] Serviço de Anatomia Patologica, Hospital de Santa Maria, Lisbon, Portugal

Corresponding Author

E. Barjas, M.D.
Serviço de Medicina II
Hospital de Santa Maria
Av. Prof. Egas Moniz
1649-035 Lisboa
Portugal
Fax: + 351-21-7932605
E-mail: nc34119a@netc.pt

Figure 1 A 50-year-old man was admitted with obstructive acute renal failure. In the second week after admission he suffered an episode of upper gastrointestinal bleeding. Emergency upper endoscopy revealed black diffuse mucosa and mucosal bridges resulting from laceration of the submucosal layer in the lower esophagus. Biopsies showed unspecified esophagitis with necrosis. The patient's condition deteriorated and he died with multiple organ failure.

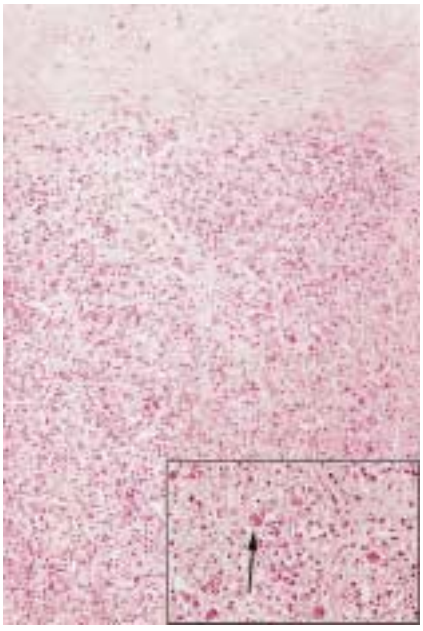

Figure 2 The postmortem examination of the esophagus demonstrated multiple inclusion bodies of cytomegalovirus (arrow) in the granulation tissue of the ulcer base, both in the mucosal and muscular layers. HIV serology was negative.

Dieses Dokument wurde zum persönlichen Gebrauch heruntergeladen. Vervielfältigung nur mit Zustimmung des Verlages.