



## Catheter-Directed Thrombolysis for Treatment of Axillary-Subclavian Venous Thrombosis

ANTHONY J. COMEROTA, M.D.<sup>1</sup>

**ABSTRACT** Primary axillary-subclavian vein thrombosis with associated symptoms of painful swelling and cyanosis of the upper extremity is best treated with catheter-directed thrombolysis. Following lysis the subclavian vein is evaluated for extrinsic compression, which is frequently observed as the vein crosses the first rib. First rib resection followed by balloon dilation of the stricture and stenting if necessary has proven to be a successful and durable approach. Catheter-directed thrombolysis is also the most effective technique to treat secondary axillary-subclavian venous thrombosis, although in some patients removal of the indwelling catheter and anticoagulation is also a satisfactory therapy.

**Keywords** Axillary-subclavian venous thrombosis, thrombolysis, thoracic outlet syndrome, venous stents

Thrombosis of the axillary-subclavian venous system is an infrequent occurrence, with an estimated event rate of 0.5 to 1.5% of all venous thrombosis. Axillary-subclavian deep vein thrombosis (DVT) can be divided into spontaneous or effort-related thrombosis and secondary axillary-subclavian DVT, usually related to long-term indwelling catheters.

*Perspectives in Vascular Surgery and Endovascular Therapy*, Volume 14, Number 1, 2001. Address for correspondence and reprint requests: Anthony J. Comerota, M.D., Temple University School of Medicine, Department of Surgery, Broad & Ontario Streets, Philadelphia, PA 19140. <sup>1</sup>Department of Surgery, Temple University School of Medicine, Philadelphia, PA. Copyright © 2001 by Thieme Medical Publishers, Inc., 333 Seventh Avenue, New York, NY 10001, USA. Tel: +1(212) 584-4662. 1531-0035.p;2001,14,01,051,056,ftx,en;pvs00107x.

## SPONTANEOUS AXILLARY-SUBCLAVIAN VENOUS THROMBOSIS

Spontaneous thrombosis of the axillary-subclavian venous system (effort thrombosis) usually occurs in healthy, young individuals. This entity was originally described over 100 years ago by Paget from England and Von Schroetter from Germany. Therefore, the eponym frequently given to this entity is the Paget-Schroetter syndrome.

Patients usually present with a swollen arm and dilated, distended veins of the upper chest wall, shoulder, neck, and axilla as well as the arm and hand. A cyanotic hue of the arm is observed in many patients, reminiscent of phlegmasia cerulea dolens of the lower extremity. A dull, aching pain that is worsened with exercise is commonly described by patients, which is essentially upper extremity venous claudication. Frequently, patients present after strenuous upper extremity exercise, although some may fail to associate any particularly vigorous activity before their presentation.

Venous duplex imaging usually confirms the diagnosis but may not identify the proximal extent of the thrombus. Phlebography is used much more commonly for upper extremity DVT because the clavicle and ribs frequently obscure the ultrasound evaluation of the central deep veins.

Although some physicians believe that axillary-subclavian DVT is a benign condition, others suggest that more aggressive management techniques of clot removal and full anticoagulation are indicated. Untreated, 25 to 75% of the affected patients will have some limitation of activity.<sup>1-3</sup>

The underlying pathology is usually chronic extrinsic compression of the vein as it crosses over the first rib, between the first rib and the clavicle. This extrinsic compression causes stricture of the subclavian vein at the thoracic inlet. A hypertrophied anterior scalene muscle and/or subclavius tendon causes additional narrowing of the thoracic inlet. A large exostosis at the costoclavicular junction has also been described.

### Catheter-Directed Thrombolysis

Treatment of these patients is designed to remove the acute thrombus, decompress the extrinsic compression, and relieve the intrinsic stricture (Fig. 1). After the diagnosis is established with venous duplex imaging, catheter-directed thrombolysis is planned. Following proper positioning of the catheter within the thrombus, a loading dose of rt-PA of approximately 2 to 4 mg is given in bolus, pulsed fashion. Recombinant tissue plasminogen activator (rt-PA) is then infused at approximately 1 to 2 mg/h. Heparin is given concurrently at 500 to 1000 U/h.

Significant clinical improvement is observed as the thrombus is lysed. As the clot occluding the first rib venous collaterals is lysed, swelling and discomfort rapidly subside.

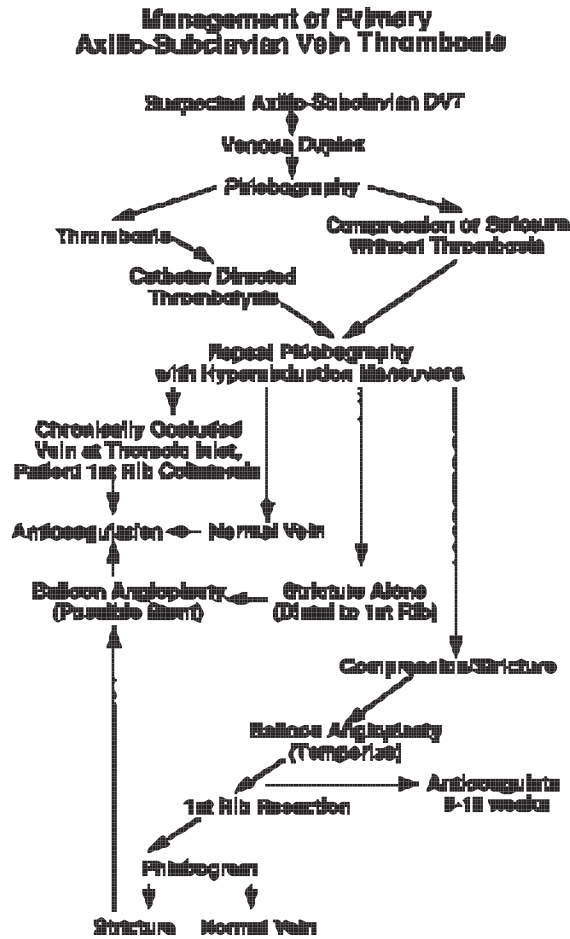


Fig. 1 Algorithm for the management of primary axillary-subclavian vein thrombosis.

Following thrombolysis, repeat phlebography is performed with hyperabduction maneuvers. If the vein is normal, the patient is continued on anticoagulation. If the vein is chronically occluded at the thoracic inlet and a balloon angioplasty catheter cannot be passed across the segmental occlusion, the first rib collaterals may provide adequate venous drainage if rethrombosis does not occur; therefore, the patient is continued on long-term anticoagulation.

### Balloon Angioplasty and Stenting

If stricture of the vein is observed without an extrinsic compression, balloon angioplasty is performed. A stent can be used to support the angioplasty if recoil of the stricture is observed. However, a stent should not be placed

between the first rib and the clavicle due to the extrinsic compression occurring in this location with arm elevation. A temporizing balloon angioplasty of a stricture at the level of the first rib can be performed to maximize luminal diameter until permanent relief of the extrinsic compression is accomplished by first rib resection.

### **Thoracic Outlet Decompression**

Many prefer to anticoagulate for a period of 6 to 10 weeks before first rib resection to allow resolution of the phlebotic process and reendothelialization of the damaged vein.<sup>4</sup> Reports indicate that first rib resection can be performed safely and effectively immediately following thrombolysis, without the 6- to 10-week delay. Following first rib resection a phlebogram is performed with hyperabduction maneuvers. Intrinsic strictures are dilated (and stented if necessary) followed by anticoagulation. If the vein is normal at this point, further anticoagulation is not necessarily recommended. If the patient underwent an immediate rib resection following thrombolysis, anticoagulation is recommended.

### **Venous Reconstruction**

Symptomatic patients with long residual stenoses or obstructions of the axillary-subclavian vein, which cannot be corrected with percutaneous techniques, should be treated with a bypass procedure. A number of techniques have been reported; however, a popular option is the ipsilateral jugular vein turn-down procedure. The internal jugular vein is dissected to the base of the skull and divided. It is turned down and anastomosed to the patent axillary vein.

The early technique of claviclectomy and venous thrombectomy with direct vein reconstruction has given way to catheter-directed thrombolysis and endoluminal repair of strictures following first rib resection.

## **SECONDARY AXILLARY-SUBCLAVIAN VENOUS THROMBOSIS**

Secondary axillary-subclavian venous thrombosis is most commonly caused by indwelling catheters and is recognized more frequently than primary axillary-subclavian DVT. Screening phlebography in patients with central venous catheters has demonstrated that 33 to 60% of patients develop venous thrombosis of the axillary subclavian segment and 3% demonstrate clinically evident venous obstruction.<sup>5</sup> The approach to patients with secondary axillary-subclavian vein thrombosis depends on the severity of their symptoms, the hemotologic and systemic comorbidities, the need to preserve the thrombosed venous segment for subsequent vascular access, and the known risk of intervention.

## Anticoagulation

Traditional treatment of secondary axillary-subclavian vein thrombosis has been catheter removal, limb elevation, warm moist heat, and anticoagulation. Usually acute symptoms resolve within days, although persistent swelling, discomfort, and exercise-induced pain persist in up to 70% of patients. Anticoagulation is unlikely to restore patency to the occluded venous segment. Although ongoing symptomatic improvement is frequently observed following anticoagulation, it generally results from recruitment of collaterals, which serve to bypass the occluded central vein.

## Catheter-Directed Thrombolysis

Catheter-directed thrombolysis and correction of an underlying venous stenosis are considered in patients in whom preservation of venous access is mandatory and in patients in whom ongoing venous obstructive symptoms would be debilitating. The principles of clot dissolution followed by correction of an intrinsic stricture are followed. Although intrinsic stricture is commonly found in patients with catheter-related thrombosis, extrinsic compression must be considered as a potential etiology in patients with an underlying malignancy and especially those with mediastinal tumors.

### REFERENCES

1. Glociczki P, Kazmier FJ, Hollier LH. Axillary-subclavian venous occlusion: the morbidity of a nonlethal disease. *J Vasc Surg* 1986;4:333-338
2. Tilney NL, Griffiths HJG, Edwards EA. Natural history of major venous thrombosis of the upper extremity. *Arch Surg* 1970;101:792-796
3. Linblad B, Bornmyer S, Kullendorff B, Bergqvist D. Venous hemodynamics of the upper extremity after subclavian vein thrombosis. *VASA* 1990;19:218-221
4. Machleder HI. Thrombolytic therapy for acute primary axillary-subclavian vein thrombosis. In: Comerota AJ, ed. *Thrombolytic Therapy for Peripheral Vascular Disease*. Philadelphia: JB Lippincott Co; 1995:197-207
5. Brismar B, Hardstedt C, Jacobson S. Diagnosis of thrombosis by catheter phlebography after prolonged central venous catheterization. *Ann Surg* 1981;194:779-783

