

Laparoscopic Findings in Wilson's Disease without Cirrhosis

T. Sakai, K. Shiraki, T. Tada, H. Fuke, M. Tanabe, H. Inoue, K. Sugimoto, S. Ohmori, K. Takase, T. Nakano

First Dept. of Internal Medicine,
Mie University School of Medicine,
Tsu, Mie, Japan

Corresponding Author

K. Shiraki, M.D., Ph.D.
First Dept. of Internal Medicine
Mie University School of Medicine
2-174 Edobashi
Tsu
Mie
Japan
Fax: +81-59-231-5201
E-mail: katsuyas@clin.medic.mie-u.ac.jp

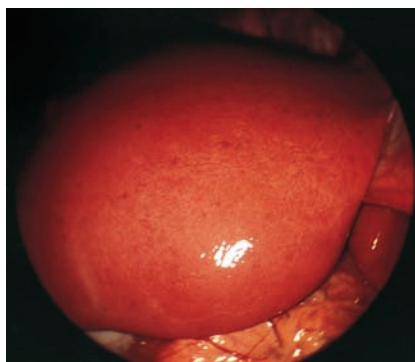


Figure 1 A 25-year-old man was referred to our hospital because of liver dysfunction with abnormal copper metabolism. Laparoscopic findings revealed a mild yellowish liver with smooth surface. There were multiple dark-bluish round spots 1–2 mm in diameter on the surface of both lobes, indicating uneven distribution of copper deposition. The patient was diagnosed as having the early stage of Wilson's disease.

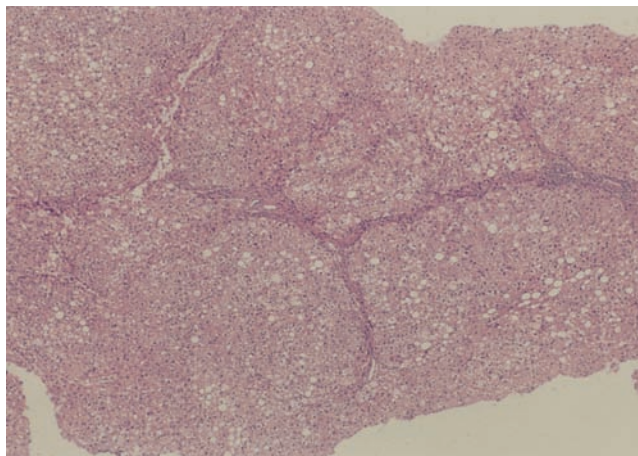


Figure 2 Histological findings revealed regenerative lobules with thin fibrous septa. In the parenchyma, fatty change was irregularly distributed, compatible with Wilson's disease (hematoxylin and eosin, original magnification $\times 100$).