



# Comparative Analysis of Radiation Dose in Advanced X-Ray Mammographic Modalities and Evaluation of Potential Influencing Factors

Porkodi Dharmalingam<sup>1</sup> Devimeenal Jagannathan<sup>1</sup>

<sup>1</sup>Institute of Radiodiagnosis, Government Kilpauk Medical College and Hospital, Chennai, Tamil Nadu, India

Indian J Radiol Imaging 2026;36:224–231.

Address for correspondence Porkodi Dharmalingam, MBBS, DMRD, Institute of Radiodiagnosis, Government Kilpauk Medical College and Hospital, Chennai, Tamil Nadu 600016, India (e-mail: porkodid1976@gmail.com; goldendoctor@yahoo.com).

## Abstract

### Keywords

- ▶ radiation dose
- ▶ average absorbed glandular dose
- ▶ contrast-enhanced mammography
- ▶ digital breast tomosynthesis
- ▶ synthetic mammography
- ▶ digital mammography
- ▶ combo mode
- ▶ low energy image of CEM
- ▶ CC views compared with MLO views

**Background and Aim** Contrast-enhanced mammography (CEM) is a highly accurate, patient-friendly imaging technique. This study aimed to compare the radiation dose of CEM with other mammographic modalities and examine factors influencing radiation exposure to minimize doses.

**Settings and Design** This retrospective study was conducted at a tertiary care teaching institute.

**Materials and Methods** We analyzed 184 craniocaudal (CC) and 184 mediolateral oblique (MLO) views from 93 participants who underwent both Combo mode (digital mammography [DM] with digital breast tomosynthesis [DBT]) and CEM. Data on automatic exposure control, average glandular dose (AGD), compressed breast thickness (CBT), compression force (CF), breast density, and the anode/filter used were collected.

**Statistical Analysis** Scheffe's post hoc analysis compared AGD across different modalities and factors.

**Results** The mean AGD for CEM (including low-energy [LE] and high-energy [HE] components) was 1.35 times that of DM, 1.3 times that of DBT alone or with synthetic mammography (SM), and 0.66 times that of the Combo mode. AGD in CEM\_LE and DBT with SM was comparable to DM across views. Higher AGDs were observed in the MLO view, dense breasts, and when using a tungsten–copper anode/filter. AGD positively correlated with CBT and CF.

**Conclusion** CEM\_LE and DBT with SM, showing similar AGD to DM in this study and comparable diagnostic value in the literature, may reduce the need for additional DM. CC views may be preferred over MLO for delayed imaging of contrast kinetics. With high diagnostic accuracy and acceptable radiation dose, CEM may be preferred over the Combo mode (DM + DBT).

article published online  
June 24, 2025

DOI <https://doi.org/10.1055/s-0045-1809902>.  
ISSN 0971-3026.

© 2025. Indian Radiological Association. All rights reserved.  
This is an open access article published by Thieme under the terms of the Creative Commons Attribution-NonDerivative-NonCommercial-License, permitting copying and reproduction so long as the original work is given appropriate credit. Contents may not be used for commercial purposes, or adapted, remixed, transformed or built upon. (<https://creativecommons.org/licenses/by-nc-nd/4.0/>)  
Thieme Medical and Scientific Publishers Pvt. Ltd., A-12, 2nd Floor, Sector 2, Noida-201301 UP, India

## Introduction

Diagnostic X-rays should ensure that the radiation dose is kept as low as reasonably achievable while maintaining adequate image quality.<sup>1-3</sup> Advanced mammographic procedures, such as 2D digital mammography (DM), digital breast tomosynthesis (DBT), and contrast-enhanced mammography (CEM), are widely used for both diagnostic and screening purposes due to their high diagnostic accuracy. However, these procedures carry a small risk of radiation-induced carcinogenesis.

For diagnostic X-rays, radiation dose evaluation is generally performed using the entrance surface dose. In mammography, however, the Average absorbed glandular dose/average glandular dose (AGD) is the preferred metric, as mammary glands are more sensitive to radiation's adverse effects than skin and fatty tissues.<sup>4</sup> To address this sensitivity, mammography doses are optimized based on AGD levels and image quality standards established by organizations such as the American College of Radiology (ACR) and the European Reference Organization for Quality Assured Breast Screening and Diagnostic Services (EUREF).<sup>4-6</sup>

While the risks associated with ionizing radiation are generally minimal and often outweighed by the benefits in symptomatic patients—such as evaluating suspicious findings, cancer staging, or assessing responses to neoadjuvant therapy<sup>7-9</sup>—assessing radiation doses becomes particularly critical when imaging healthy individuals, as in population screening using radiation-based techniques.<sup>10</sup> Therefore, meticulous evaluation of radiation doses is essential to define the appropriate clinical applications of these imaging modalities.

The primary objective of this study is to evaluate the mean AGD for CEM, which combines the AGD from low-energy (LE) and high-energy (HE) exposures, in comparison to other X-ray mammographic procedures, including 2D digital mammography (DM), DBT with synthetic mammography (SM), and the Combo mode (DBT combined with DM). The findings, along with insights into the indications and limitations of each modality from existing studies, will assist in prioritizing the most suitable imaging modality for individual patients.

The secondary objective is to investigate potential influencing factors, such as breast density, X-ray view (craniocaudal [CC] or mediolateral oblique [MLO]), compressed breast thickness (CBT), compression force (CF), and the anode/filter combination used. The ultimate aim is to identify modifiable factors and develop strategies for reducing radiation dose.

## Materials and Methods

### Study Population

A retrospective study was conducted at a tertiary care teaching institute following approval from the institutional review board. The study analyzed 184 CC and 184 MLO views from 93 participants who underwent both Combo mode imaging (DM with DBT) and CEM between January and May 2024. Participants' ages ranged from 28 to 92 years.

CEM was performed for the following indications.

1. Lesions classified as BIRADS 4a or higher on ultrasound (USG) and combo mode imaging.
2. Screening for high-risk individuals with dense breasts.
3. Evaluation of inconclusive findings from dual imaging (USG and combo mode).
4. Preoperative staging of confirmed breast cancer.

### Digital Breast Tomosynthesis

Both DBT and CEM were performed using the Hologic Selenia Dimensions 3D system. Combo mode (2D imaging with DBT) or combo HD mode (DM plus DBT with synthesized 2D images [SM]) was utilized for the following advantages<sup>11,12</sup>:

- The 2D image aids in comparison with prior studies.
- It facilitates the quick identification of microcalcifications.
- Tomosynthesis reduces structural overlap, improving the visualization of masses.

The Hologic system generates a synthesized 2D image (SM) using mathematical algorithms reconstructed from the tomosynthesis dataset (HD mode), eliminating the need for separate 2D imaging.<sup>11,12</sup>

For each breast view, a standard 2D image was acquired, followed by multiple low-dose images. During DBT, the X-ray tube moves across an arc (15–60 degrees, depending on the manufacturer) aligned with the chest wall to capture numerous low-dose images, which are reconstructed into stacked slices.<sup>11,12</sup>

Data regarding AGD, CBT, CF, breast density, and the anode/filter combination for each view during DM and DBT were obtained from the workstation monitor.

### Contrast-Enhanced Mammography

For CEM, a low-osmolar, non-ionic, iodinated contrast agent (Iohexol, 350 mg iodine/mL) was administered at 1.5 mL/kg body weight using a Medrad Plus single-head pressure injector at a rate of 3 mL/s through a peripheral intravenous cannula. Imaging began 120 seconds postinjection with the breast under compression.<sup>7</sup>

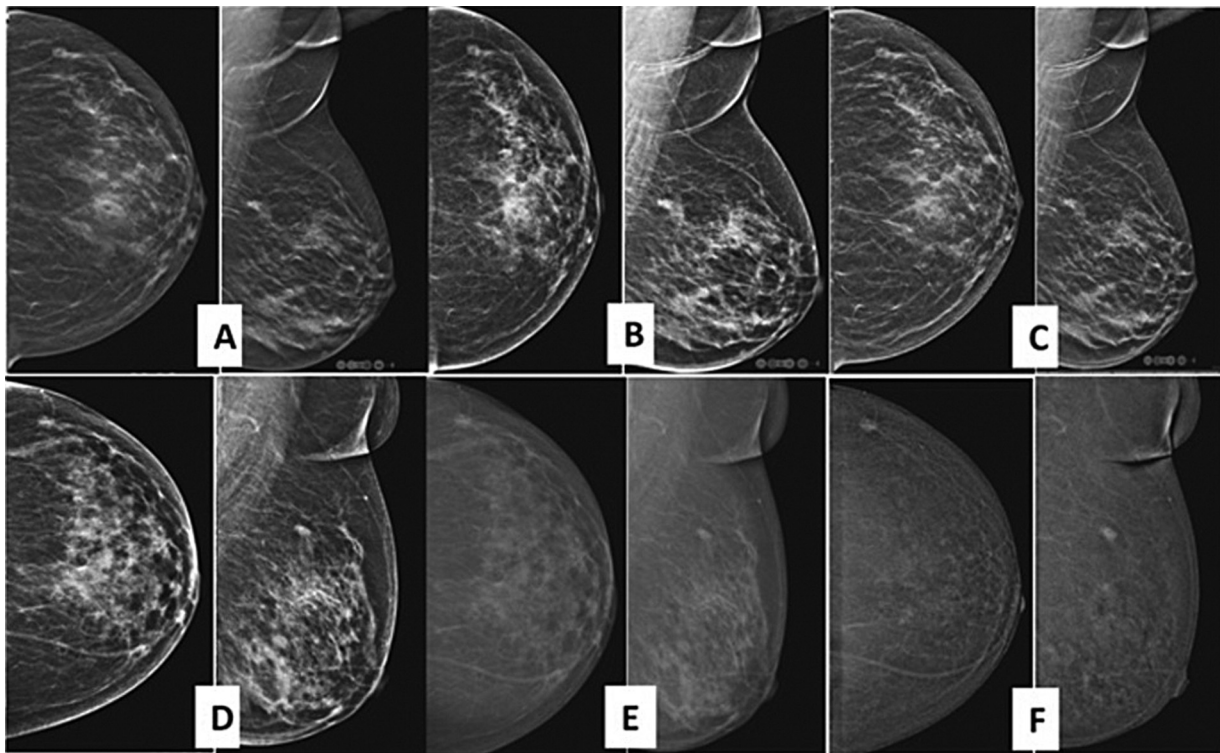
CEM collected two images per view<sup>7,13</sup>:

1. **Low-energy images:** Acquired at 28 to 32 kVp, below iodine's K-edge (33.2 keV), resembling standard 2D mammograms without visible iodine contrast.
2. **High-energy images:** Acquired at 45 to 49 kVp, above iodine's K-edge, highlighting contrast uptake but not suitable for direct interpretation.

Automatic postprocessing combined LE and HE images into recombined images, emphasizing contrast-enhanced areas while minimizing background tissue signals. Both LE and recombined images were used for diagnostic evaluation.<sup>7,13</sup>

For each view, the AGD of LE and HE images was recorded and summed to calculate the total AGD for CEM. Data on anode/filter combination, CBT, and CF were also collected.

► **Figure 1** presents images of a representative case across various imaging modalities.



**Fig. 1** Images of a representative case across various imaging modalities in CC and MLO views of RB. (A) 2D DM; (B) DBT; (C) SM; (D) CEM\_LE; (E) CEM\_HE; (F) CEM\_RC images. CC, craniocaudal; CEM, contrast-enhanced mammography; DBT, digital breast tomosynthesis; HE, high energy; LE, low energy; MLO, mediolateral oblique; RB, right breast; SM, synthesized mammography; 2D DM, two-dimensional digital mammography.

### Statistical Analysis

Data were entered into Microsoft Excel 2019 to create a master dataset and subsequently analyzed using SPSS version 26. The study included both quantitative and qualitative variables:

- Quantitative variables were summarized using mean and standard deviation (SD).
- Qualitative variables were presented as frequencies and percentages.

### Statistical Tests Used

- Independent sample *t*-test for comparing means between two groups.
- Analysis of variance (ANOVA) for comparing means across more than two groups, with Scheffé's test as the post hoc analysis.
- A *p*-value of <0.05 was considered statistically significant.
  - Bar charts were employed for the graphical representation of data.

### Results

► **Table 1** lists the comparison of AGD between CC and MLO in 2D DM, DBT, DM + DBT, and CEM. The mean AGD for CEM (including LE and HE components) was 1.35 times that of DM, 1.3 times that of DBT (alone or with SM), and 0.66 times that of the Combo mode. The AGD values in CEM\_LE and DBT with SM were comparable to those of DM across all views. Additionally, the mean AGD in the MLO view was consistently

**Table 1** Comparison of AGD between CC and MLO in DM imaging, DBT, DM + DBT, and CEM

Imaging modality	CC	MLO	t-Value	p-Value
DM	1.78 ± 0.67	2.44 ± 0.98	7.39	0.001 <sup>a</sup>
DBT	1.86 ± 0.37	2.30 ± 0.62	8.18	0.001 <sup>a</sup>
DM + DBT	3.65 ± 1.01	4.74 ± 1.44	8.42	0.001 <sup>a</sup>
CEM_LE	1.91 ± 0.80	2.57 ± 1.14	6.34	0.001 <sup>a</sup>
CEM_HE	0.49 ± 0.27	0.66 ± 0.58	3.57	0.001 <sup>a</sup>
CEM	2.41 ± 0.96	3.23 ± 1.40	6.59	0.001 <sup>a</sup>

Abbreviations: AGD, average glandular dose; CC, craniocaudal; CEM, contrast-enhanced mammography; DBT, digital breast tomosynthesis; DM, digital mammography; HE, high-energy; LE, low-energy; MLO, mediolateral oblique.

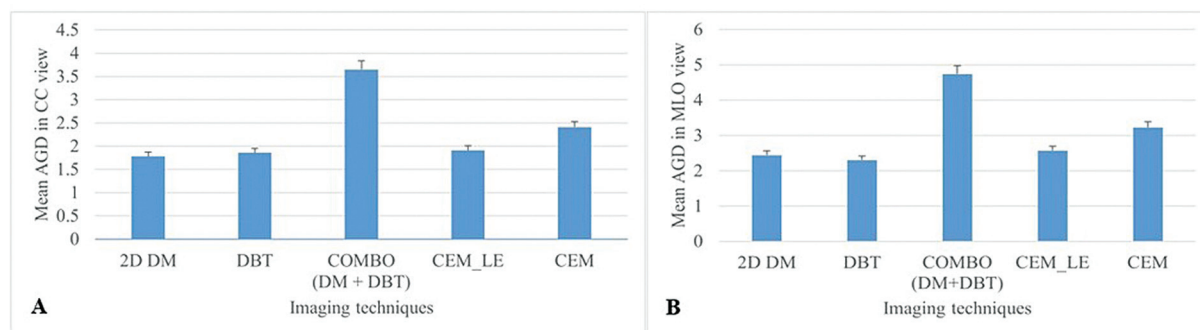
<sup>a</sup>Statistically significant with a *p*-value of less than 0.05.

higher than in the CC view across all imaging modalities. Specifically, the ratios of AGD in the MLO view compared with the CC view were 1.37, 1.24, 1.30, 1.35, and 1.34 for DM, DBT, Combo mode, CEM\_LE, and CEM, respectively.

In both the CC and MLO views, the AGD varied significantly across the different imaging modalities, with a *p*-value of less than 0.05 (► **Fig. 2**).

Based on the post hoc Scheffé's test, the AGD in Combo mode was significantly higher than in DM, DBT, CEM\_LE, and total CEM in both views. Furthermore, the AGD of total CEM was significantly higher than that of DM and DBT (► **Table 2**).

The mean AGD was significantly higher in dense breasts compared with non-dense breasts across all modalities,



**Fig. 2** Bar charts showing comparison of AGD in (A) CC view and (B) MLO view between DM imaging, DBT, and CEM. AGD, average glandular dose; CC, craniocaudal; CEM, contrast-enhanced mammography; DBT, digital breast tomosynthesis; DM, digital mammography; LE, low energy; MLO, mediolateral oblique.

**Table 2** Post hoc comparisons of AGD scores in CC and MLO views between DM imaging, DBT, and CEM

Imaging modality		CC view		MLO view	
		Mean difference	p-Value	Mean difference	p-Value
DM	DBT	-0.07	0.847	0.13	0.752
	DM + DBT	-1.86	0.001 <sup>a</sup>	-2.30	0.001 <sup>a</sup>
	CEM_LE	-0.12	0.675	-0.13	0.878
	CEM	-0.62	0.001 <sup>a</sup>	-0.79	0.001 <sup>a</sup>
DBT	DM + DBT	-1.78	0.001 <sup>a</sup>	-2.44	0.001 <sup>a</sup>
	CEM_LE	-0.05	0.983	-0.26	0.307
	CEM	-0.54	0.001 <sup>a</sup>	-0.93	0.001 <sup>a</sup>
DM + DBT	CEM_LE	1.73	0.001 <sup>a</sup>	2.17	0.001 <sup>a</sup>
	CEM	1.24	0.001 <sup>a</sup>	1.50	0.001 <sup>a</sup>
CEM_LE	CEM	-0.49	0.001 <sup>a</sup>	-0.66	0.001

Abbreviations: AGD, average glandular dose; CC, craniocaudal; CEM, contrast-enhanced mammography; DBT, digital breast tomosynthesis; DM, digital mammography; HE, high-energy; LE, low-energy; MLO, mediolateral oblique.

<sup>a</sup>Statistically significant with a p-value of less than 0.05.

including DM imaging, DM + DBT (Combo mode), and CEM, with a p-value of less than 0.05 (►Table 3 and ►Fig. 3).

For CEM (LE + HE), in both the CC and MLO views, the AGD was significantly higher with the anode combination of tungsten and aluminium, followed by tungsten and silver, and tungsten and rhodium. The lowest AGD was observed with tungsten and copper (p-value <0.05; ►Table 4 and ►Fig. 4).

**Table 3** Comparison of AGD across various breast densities

Imaging techniques	Breast density		t-Value	p-Value
	Non-dense	Dense		
2D DM	1.90 ± 0.89	2.27 ± 0.87	3.90	0.001 <sup>a</sup>
DBT	2.04 ± 0.66	2.11 ± 0.47	1.27	0.202
2D + DBT	3.95 ± 1.39	4.39 ± 1.30	3.11	0.002 <sup>a</sup>
CEM	3.34 ± 1.72	3.75 ± 1.65	2.29	0.022 <sup>a</sup>

Abbreviations: AGD, average glandular dose; CEM, contrast-enhanced mammography; DBT, digital breast tomosynthesis; 2D DM, two-dimensional digital mammography.

<sup>a</sup>Statistically significant with a p-value of less than 0.05.

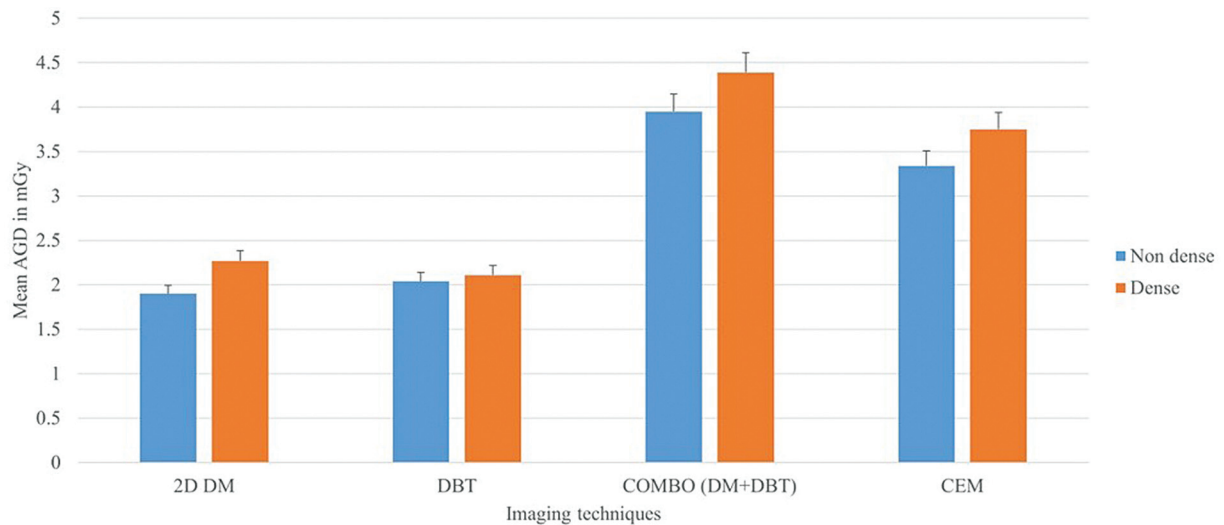
The AGD for compressed breast thickness (CBT) above 22 mm increased significantly with increasing CBT (►Table 5 and ►Fig. 5). Additionally, AGD increased significantly with an increase in CF (►Table 6 and ►Fig. 6).

The mean AGD with respect to CBT for 2D DM, DBT (alone or with SM), and CEM-LE was significantly lower than the acceptable level (ACC) defined by EUREF. However, the AGD of total CEM was slightly above the ACC, and the AGD of Combo mode exceeded the ACC level (►Fig. 7).

## Discussion

Considering the relatively high sensitivity of glandular breast tissue and the prevalence of annual or biannual breast screening programs, studies on radiation dose are crucial for optimizing patient safety.<sup>13</sup>

The study by Skaane et al. demonstrated that combining current reconstructed 2D images with DBT performed comparably to full-field digital mammography (FFDM) plus DBT and is sufficient for routine clinical use in screening mammograms. In our current study, the mean AGD of 2D DM and DBT with SM were nearly identical and below the acceptable level. Therefore, these modalities are viable for screening,



**Fig. 3** Bar chart showing comparison of AGD across various breast densities. AGD, average glandular dose; CEM, contrast-enhanced mammography; DBT, digital breast tomosynthesis; 2D DM, two-dimensional digital mammography.

**Table 4** Comparison of AGD across different anode/filter types

Anode type	AGD	F-value	p-Value
Tungsten and Rhodium	1.89 ± 0.77	522.81	0.001 <sup>a</sup>
Tungsten and Silver	2.09 ± 0.56		
Tungsten and Copper	0.57 ± 0.36		
Tungsten and Aluminium	2.77 ± 1.12		

Abbreviation: AGD, average glandular dose.  
 Note: <sup>a</sup> Statistically significant with a p-Value of less than 0.05.

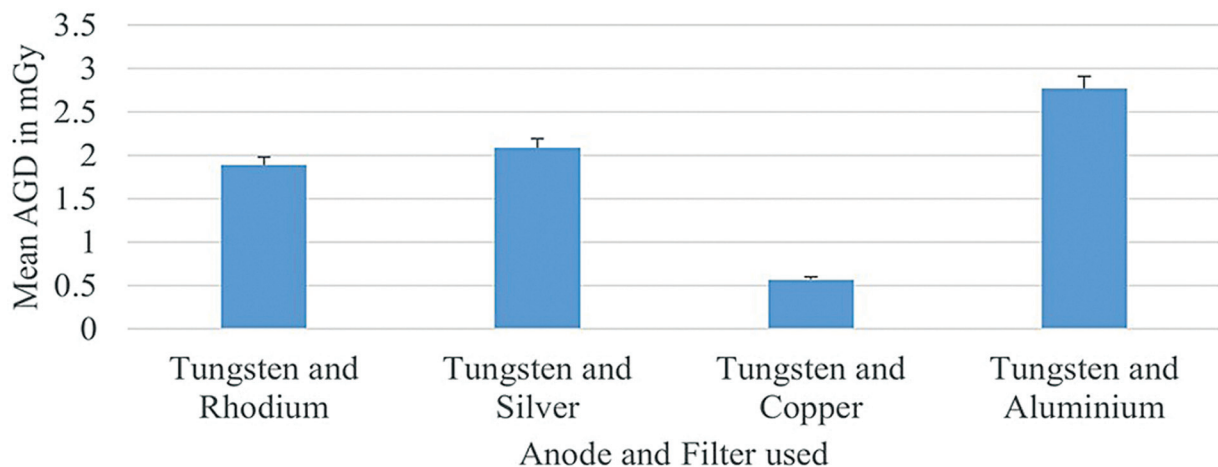
with DBT + SM being a potential alternative to the Combo mode (DBT + DM).<sup>12</sup>

Francescone et al. found that the diagnostic accuracy of LE mammograms obtained during contrast-enhanced digital mammography (CEDM) was comparable to routine FFD. In our study, the radiation dose of CEM-LE was well within acceptable limits and equivalent to that of DM. Thus, DM can

be omitted when planning CEM, potentially reducing radiation exposure without compromising diagnostic outcomes.<sup>13</sup>

Multiple studies, including one by Fusco et al., reported that the diagnostic accuracy of CEDM or CEDM + DBT is higher than DBT alone and equivalent to contrast-enhanced MRI (CE-MRI), with the added benefits of lower cost, faster imaging, and interpretation times.<sup>14</sup> In our current study, the mean AGD of total CEM (LE + HE) was lower than that of combo mode, making CEM a suitable option for high-risk screening, evaluation of suspicious lesions, preoperative staging, and posttreatment follow-up.

Gennaro et al. observed that LE images accounted for 64 to 77% of the total dose in CEM, with the remaining 23 to 36% contributed by HE images. Our study found that LE images contributed 79 to 80% of the total dose. Similarly, the mean AGD of total CEM in their study was 30% higher than that of DM, comparable to our finding of a 35% higher dose (1.35 times) than that of DM.<sup>15</sup>



**Fig. 4** Bar chart showing comparison of AGD among various anodes/filters used. AGD, average glandular dose.

**Table 5** Comparison of mean AGD with different categories of CBT

CBT (mm)	AGD (mGy)	F-value	p-Value
0–21	2.28 ± 0.16	37.49	0.001
22–32	1.82 ± 0.74 <sup>a</sup>		
33–45	2.07 ± 1.08		
46–53	2.13 ± 1.01		
54–60	2.64 ± 1.23		
61–75	3.43 ± 1.45 <sup>a</sup>		
76–90	4.39 ± 1.58 <sup>a</sup>		
>90	4.73 ± 2.58 <sup>a</sup>		

Abbreviation: AGD, average glandular dose.  
<sup>a</sup>The AGD increased significantly with increasing CBT, with a p-value of less than 0.05.

The mean AGD values for DM, DBT, and combo mode reported by Cavagnetto et al. were 1.31 mGy, 2.56 mGy, and 3.87 mGy, respectively, compared with 1.78 mGy, 1.86 mGy, and 3.65 mGy, respectively, in the current study.<sup>16</sup>

Supar et al. found a statistically significant difference in AGD between dense and non-dense breasts. Likewise, our study demonstrated that the mean AGD was significantly higher in dense breasts across all modalities.<sup>17</sup>

Similar to our study, Fusco et al. found that a tungsten anode with a copper filter at the same CBT minimized the dose in CEM, and AGD was lower in CC views compared with MLO views in both DBT and CEM. Additionally, while their study found no correlation between CF and AGD, our results showed that both CBT and CF influenced AGD.<sup>14</sup>

Studies by James et al. and Phillips et al. have concluded that, although CEM results in an increased AGD compared with DM and DBT, this increase is offset by the enhanced diagnostic accuracy that CEM provides when used alongside these modalities.<sup>18,19</sup>

**Table 6** Comparison of mean AGD with different categories of CF

CF (N)	AGD (mGy)	F-value	p-Value
≤50	2.04 ± 0.86 <sup>a</sup>	7.64	0.001
51–100	2.54 ± 1.23		
101–150	2.58 ± 1.39 <sup>a</sup>		
>150	2.95 ± 1.45 <sup>a</sup>		

Abbreviations: AGD, average glandular dose; CF, compression force.  
<sup>a</sup>AGD increased significantly with an increase in CF.

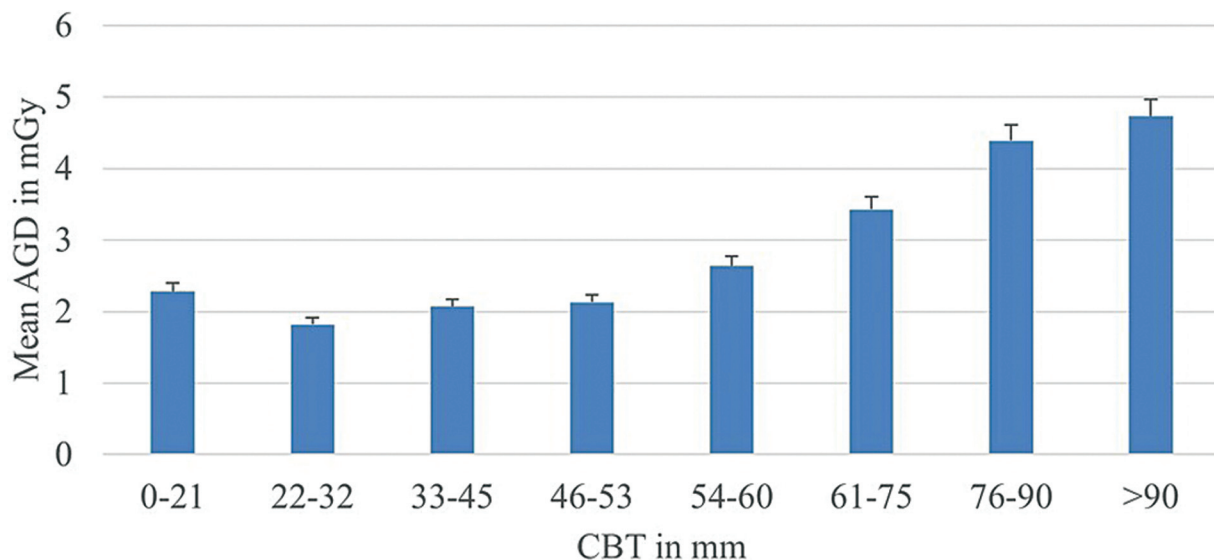
**Study Limitations and Future Directions**

Our data were derived from a single mammography unit at a single center. Consequently, DBT and CEM techniques used by other manufacturers and at other centers with varying equipment designs may yield different dose results.

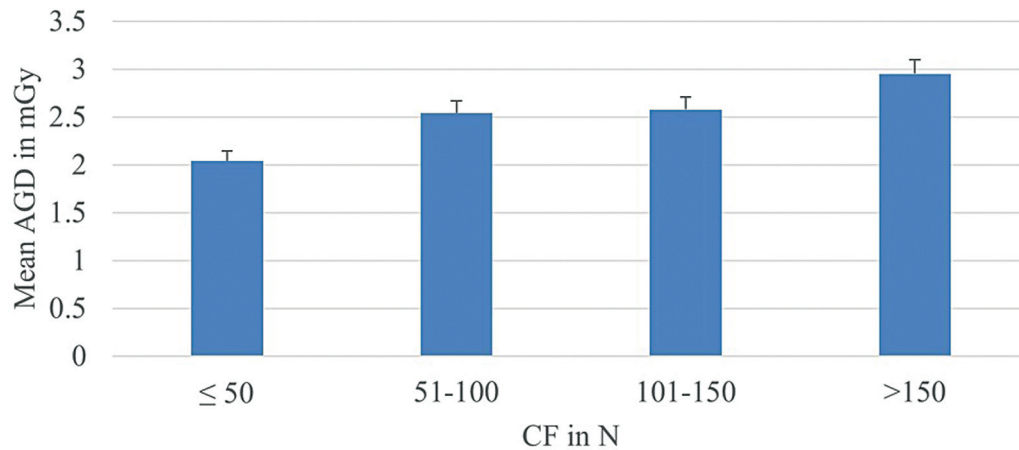
Larger, multicenter studies incorporating equipment from different manufacturers are necessary to better understand radiation dose variations. Such studies could also help develop strategies to minimize radiation exposure without compromising diagnostic accuracy.

**Conclusion**

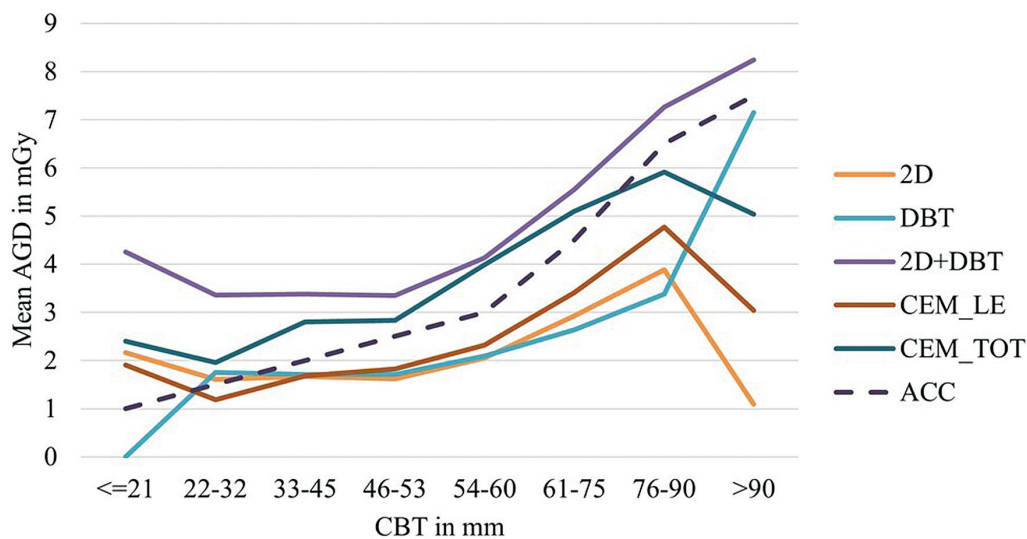
CEM, with its high diagnostic accuracy as supported by the literature and a radiation dose well below that of the combo mode (DBT + DM) in our study, may be preferred for high-risk screening and diagnostic indications. Its use should not be restricted. The LE image of CEM, which demonstrates diagnostic accuracy equivalent to DM as per the literature and has a comparable radiation dose in our current study, suggests that CEM-LE may eliminate the need for additional plain DM, reducing overall radiation exposure. DBT with SM, having a radiation dose below the acceptable level, may serve as a better alternative to the



**Fig. 5** Bar chart showing the comparison of mean AGD across different categories of CBT. AGD, average glandular dose; CBT.



**Fig. 6** Bar chart showing the comparison of mean AGD across different categories of CF. AGD, average glandular dose; CF, compression force.



**Fig. 7** Line diagram showing change in AGD levels with regard to CBT across all modalities. ACC, acceptable level; AGD, average glandular dose; CEM, contrast-enhanced mammography; DBT, digital breast tomosynthesis; LE, low energy; 2D DM, two-dimensional digital mammography.

combo mode (DBT + DM). Furthermore, as the CC view is associated with lower radiation exposure than the MLO view, it may be preferred for additional delayed imaging to assess contrast kinetics in lesions with indeterminate morphological features.

#### Note

This manuscript was presented as an oral proffered paper category at AOCR 2025 on January 26, 2025.

#### Conflict of Interest

None declared.

#### Acknowledgments

This study is a part of authors Ph.D. research thesis on "Comparison of outcome of 3D digital tomosynthesis and Ultrasound mammogram with and without Contrast mammogram" under The Tamil Nadu Dr. M.G.R. Medical University, Chennai, India, conducted from July 2019.

#### References

- 1 Kawaguchi A, Kobayashi M, Suzuki M, Otsuka T, Hattori S, Suzuki S Average Glandular Dose and Entrance Surface Dose in Mammography. Paper presented at: 13th International Radiation Protection Association International Congress 2019. IRPA 13, Glasgow
- 2 IAEA. International Basic Safety Standards for Protection against Ionization Radiation and for the Safety of Radiation Sources, Appendix 2. IAEA Safety Series, No. 115, Vienna; 1996:pp. 45–56
- 3 ICRP. ICRP Publication 60: Recommendations of the International Commission on Radiological Protection. Ann ICRP 1991;21(1–3)
- 4 American College of Radiology Committee on Quality Assurance in Mammography. Mammography Quality Control Manual. American College of Radiology; 1999
- 5 Zoetelief J, Fitzgerald M, Leitz W, Säbel M. European protocol on dosimetry in mammography, EUR 16263. Luxembourg: European Commission Official Publications; 1996
- 6 European Reference Organisation for Quality Assured Breast Screening and Diagnostic Services. European Guidelines for Quality Assurance in Breast Cancer Screening and Diagnosis. Fourth Edition. The Netherlands: European Communities; 2003
- 7 Ghaderi KF, Phillips J, Perry H, Lotfi P, Mehta TS. Contrast-enhanced mammography: Current applications and future directions. Radiographics 2019;39(07):1907–1920

- 8 Zanardo M, Cozzi A, Trimboli RM, et al. Technique, protocols and adverse reactions for contrast-enhanced spectral mammography (CESM): a systematic review. *Insights Imaging* 2019;10(01):76
- 9 Sensakovic WF, Carnahan MB, Czaplicki CD, et al. Contrast-enhanced mammography: How does it work? *Radiographics* 2021; 41(03):829–839
- 10 Skaane P, Bandos AI, Gullien R, et al. Comparison of digital mammography alone and digital mammography plus tomosynthesis in a population-based screening program. *Radiology* 2013; 267(01):47–56
- 11 Skaane P, Gullien R, Eben EB, et al. Reading time of FFDM and Tomosynthesis in a Population-Based Screening Program. Paper presented at: Radiology Society of North America Annual Meeting, Chicago, IL; November 29, 2011
- 12 Skaane P, Bandos AI, Eben EB, et al. Two-view digital breast tomosynthesis screening with synthetically reconstructed projection images: comparison with digital breast tomosynthesis with full-field digital mammographic images. *Radiology* 2014; 271(03):655–663
- 13 Francescone MA, Jochelson MS, Dershaw DD, et al. Low energy mammogram obtained in contrast-enhanced digital mammography (CEDM) is comparable to routine full-field digital mammography (FFDM). *Eur J Radiol* 2014;83(08):1350–1355
- 14 Fusco R, Raiano N, Raiano C, et al. Evaluation of average glandular dose and investigation of the relationship with compressed breast thickness in dual energy contrast enhanced digital mammography and digital breast tomosynthesis. *Eur J Radiol* 2020; 126:108912
- 15 Gennaro G, Cozzi A, Schiaffino S, Sardanelli F, Caumo F. Radiation dose of contrast-enhanced mammography: a two-center prospective comparison. *Cancers (Basel)* 2022;14(07):1774
- 16 Cavagnetto F, Taccini G, Rosasco R, Bampi R, Calabrese M, Tagliafico A. 'In vivo' average glandular dose evaluation: one-to-one comparison between digital breast tomosynthesis and full-field digital mammography. *Radiat Prot Dosimetry* 2013;157(01):53–61
- 17 Supar R, Suliman NI, Sharip H, Yamin LM. Effect of mammographic breast density on average glandular dose (AGD) during full-field digital mammogram. *J Med Imaging Radiat Sci* 2022;53(04):S35
- 18 James JR, Pavlicek W, Hanson JA, Boltz TF, Patel BK. Breast radiation dose with CESM compared with 2D FFDM and 3D tomosynthesis mammography. *AJR Am J Roentgenol* 2017;208(02):362–372
- 19 Phillips J, Mihai G, Hassonjee SE, et al. Comparative dose of contrast-enhanced spectral mammography (CESM), digital mammography, and digital breast tomosynthesis. *AJR Am J Roentgenol* 2018;211(04):839–846