




Pedicle Morphology Analysis in Adolescents with Lenke Type 5 Idiopathic Scoliosis in Thai Population

Tinnakorn Pluemvitayaporn¹  Tassana Kaewmano¹ Sombat Kunakornsawat¹
Suttinont Surapuchong¹ Warot Ratanakoosaku¹ Kitjapat Tiracharnvut¹ Pritsanai Pruttikul¹
Chaiwat Piyasakulkaew¹ Piyabuth Kittithamvongs²

¹Spine Unit, Department of Orthopaedic Surgery, Institute of Orthopedics, Lerdsin Hospital, College of Medicine, Rangsit University, Bangkok, Thailand

²Research Unit, Department of Orthopaedic Surgery, Institute of Orthopedics, Lerdsin Hospital, College of Medicine, Rangsit University, Bangkok, Thailand

Address for correspondence Tinnakorn Pluemvitayaporn, MD, Spine Unit, Department of Orthopaedic Surgery, Institute of Orthopedics, Lerdsin Hospital, College of Medicine, Rangsit University, 190 Silom Road, Bangkok 10500, Thailand (e-mail: dr.tinnakorn@gmail.com).

Asian J Neurosurg 2025;20:132–137.

Abstract

Background The surgical management of adolescent idiopathic scoliosis (AIS) often incorporates the utilization of pedicle screws, which are three-column construct devices. A comprehensive understanding of the pedicle morphology is essential for determining the appropriate pedicle screw diameter. While previous studies have examined pedicle morphology in Lenke type 1 AIS, there is a scarcity of information about the pedicle morphology in Lenke type 5 AIS, especially in the Thai population.

Objective The aim of this study is to analyze the morphology of the thoracolumbar pedicle, specifically the pedicle width and trajectory length on both the concave and convex sides within a sample of the Thai population diagnosed with Lenke type 5 AIS.

Materials and Methods In this study, we used computed tomography (CT) measurements to examine the thoracolumbar pedicle morphology in Lenke type 5 AIS patients in the Thai population. We also analyzed the pedicle width and trajectory length on both concave and convex sides in 112 AIS patients with Lenke type 5 curvature.

Results A total of 3,808 pedicles from 112 consecutive AIS patients of Lenke type 5 were enrolled in the study. It was observed that the transverse pedicle width was notably smaller on the concave side compared with the convex side in the apical region of the thoracolumbar spine (T12 to L2). Additionally, the pedicle width of T3 was also found to be significantly smaller on the concave side. Moreover, it was noted that the pedicle trajectory length is significantly longer on the concave side, indicating that the concave side in the apical region may have the capacity to accommodate a slightly longer pedicle screw at T3, T6, L2, L3, and L4.

Conclusion Our analysis of measurements indicates that the thoracolumbar pedicle morphology in Lenke type 5 AIS among the Thai population typically shows smaller

Keywords

- ▶ pedicle
- ▶ pedicle morphology
- ▶ adolescent idiopathic scoliosis
- ▶ Lenke type 5

article published online
December 2, 2024

DOI <https://doi.org/10.1055/s-0044-1800812>.
ISSN 2248-9614.

© 2024. Asian Congress of Neurological Surgeons. All rights reserved.

This is an open access article published by Thieme under the terms of the Creative Commons Attribution-NonDerivative-NonCommercial-License, permitting copying and reproduction so long as the original work is given appropriate credit. Contents may not be used for commercial purposes, or adapted, remixed, transformed or built upon. (<https://creativecommons.org/licenses/by-nc-nd/4.0/>)

Thieme Medical and Scientific Publishers Pvt. Ltd., A-12, 2nd Floor, Sector 2, Noida-201301 UP, India

widths and longer trajectory lengths on the concave side. This information enhances our understanding of the appropriate selection of pedicle screw diameter and length for treating Lenke type 5 AIS in the Thai population.

Introduction

Adolescent idiopathic scoliosis (AIS) stands as a prevalent spinal deformity, affecting 1 to 3% of children aged between 10 and 14 years.¹ This condition manifests as a complex three-dimensional deformation of the spine, characterized by lateral deviation in the coronal plane, thoracic hypokyphosis in the sagittal plane, and rotation deformity in the axial plane. Treatment modalities encompass observation, bracing, and surgical intervention. In the cases where surgical correction is warranted, pedicle screws, serving as a three-column construct device, are extensively utilized owing to their ability to enhance curve correction efficacy and pullout strength in comparison to alternative implants. Surgeons commonly endeavor to implement pedicle screws at as many levels as possible.² Notably, a notable surgical complication entails screw malposition, which may diminish pullout strength and give rise to various complications related to nearby visceral, vascular, and neurologic structures. The literature reports these complications at an incidence of 1.2 to 65%.³

Various studies have extensively examined pedicle morphology to assess its dimensions in normal and scoliotic spines. Previous studies have documented the pedicle morphology of Lenke type 1 AIS.⁴⁻⁶ However, few studies have

been conducted on pedicle morphology in the Thai population.⁷ To our knowledge, no studies have been conducted on pedicle morphology in Lenke type 5 AIS within the Thai population.

This study aims to evaluate the morphology of thoracolumbar pedicles, with a particular focus on pedicle width and trajectory length on both the concave and convex sides within a cohort of Thai individuals diagnosed with Lenke type 5 AIS.

Materials and Methods

Between January 2017 and December 2022, a total of 112 patients diagnosed with Lenke type 5 AIS were evaluated at our institution. Preoperative 36-inch cassette whole spine radiographs, including standing posteroanterior (PA), lateral, and side-bending views (►Fig. 1), were obtained and analyzed. The Cobb method was utilized to measure the coronal and sagittal curves. Patients were classified as Lenke curve type 5 according to the criteria defined in the Lenke classification system.⁸

Computed tomography (CT) scans were performed on all patients from T1 to L5 while in the supine position, utilizing a 64-slice CT scanner (SOMATOM Definition AS, Siemens AG, Germany). Measurements were obtained directly from the

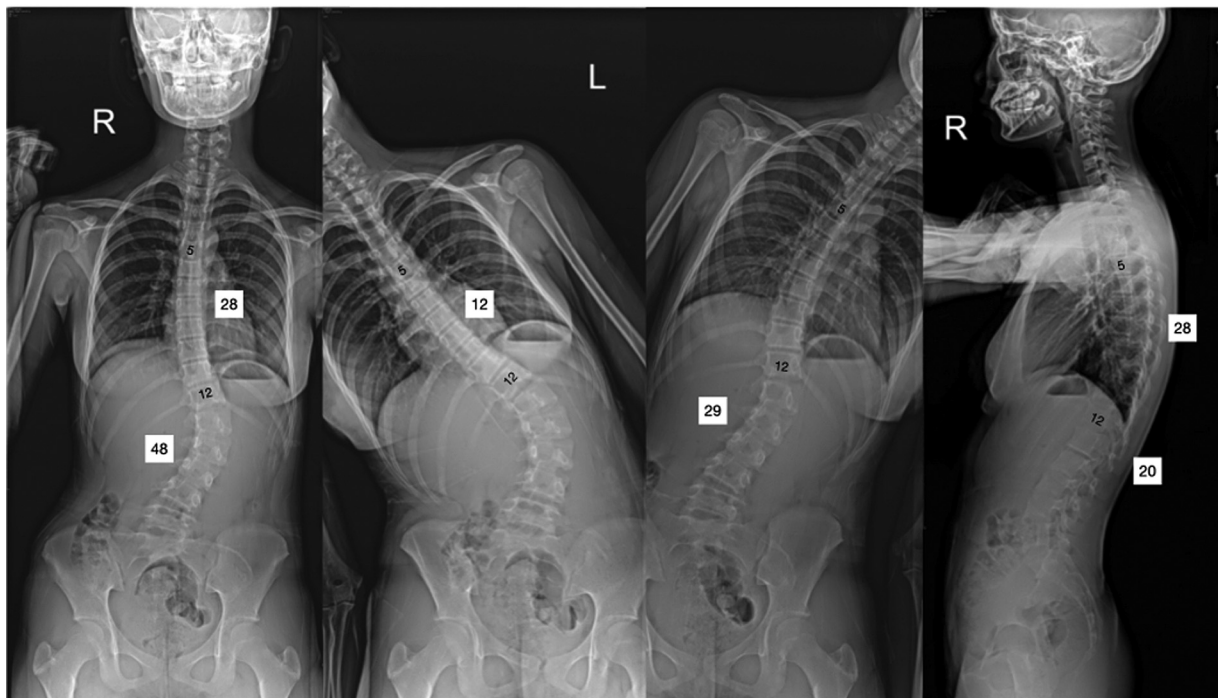


Fig. 1 A schematic diagram depicting 36-inch cassette whole spine in standing posteroanterior, side bending, and lateral radiographs of Lenke type 5 AIS.

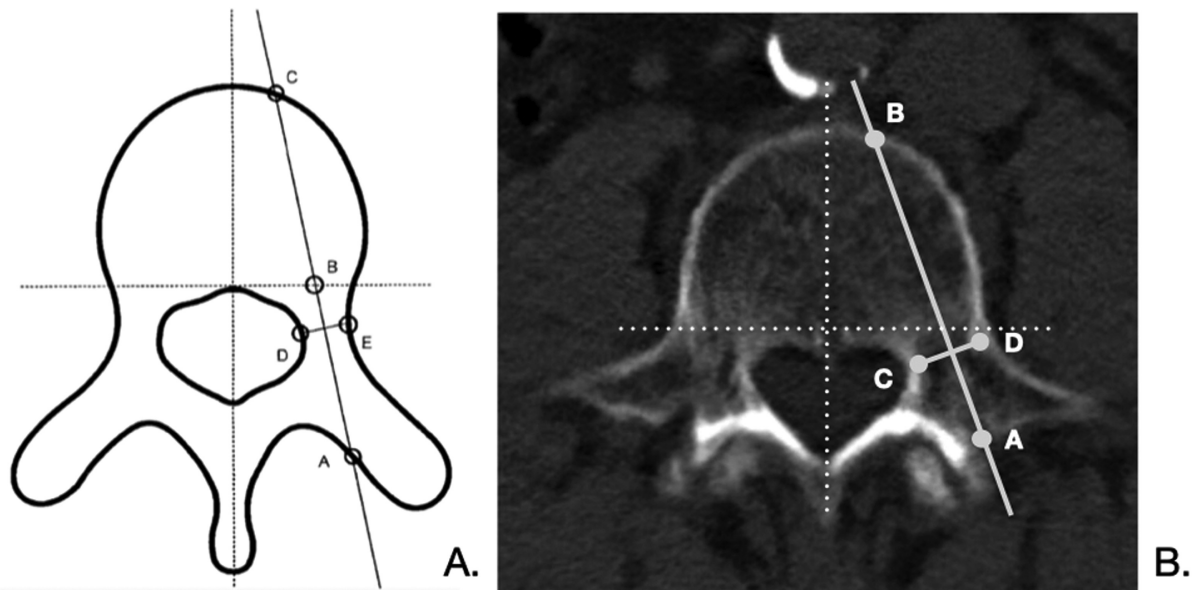


Fig. 2 (A) Illustration of the pedicle trajectory length (AC) and transverse pedicle width (DE) in a schematic representation. (B) Axial computed tomography image depicting the pedicle trajectory length (AB) and transverse pedicle width (CD).

images of the bone window. The pedicle width and trajectory length on both sides were assessed at each vertebral level. The optimal slice was selected to identify the insertion point and direction necessary to achieve the maximal pedicle diameter for each vertebra. Pedicle width was measured as the widest outer cortical diameter at the narrowest part of the pedicle between T1 and L5. The maximum pedicle trajectory length was measured as the distance between the posterior cortical entry point of the pedicle screw and the anterior vertebral cortex in line with the axis of the pedicle (→ Fig. 2).

In our analysis, all parameters on the concave side were compared with their corresponding values on the convex side. Statistical analysis was conducted using an unpaired “t” test, and significance was determined for values below $p < 0.05$.

Results

A total of 3,808 pedicles were examined, with half of the pedicles located on the concave side and the remaining half on the convex side, from 112 consecutive patients diagnosed with Lenke type 5 AIS gathered and evaluated. The average age of the patients was 14.7 years (range: 12–22 years), and the mean Cobb angle measured 48 degrees (range: 36–84 degrees).

Transverse Pedicle Width

The transverse pedicle width measurements ranged from 2.74 to 9.07 mm on the convex side and 2.71 to 8.71 mm on the concave side. At T5, the narrowest pedicles were observed, while the maximum transverse diameter was found at L5 on both sides. A clear trend is evident in which the pedicle width decreases from T1 to T5 and subsequently increases, reaching the maximum at L5 on both the concave

and convex sides. Consistently smaller transverse pedicle width values were observed on the concave side from T10 to L5. A significantly smaller concave pedicle width was found in the apical region of the thoracolumbar curves between T12 and L2, and the T3 pedicle width on the concave side was also significantly smaller than that on the convex side ($p < 0.05$; → Table 1).

Pedicle Trajectory Length

The length of the pedicle trajectory gradually increased from the proximal thoracic to the lumbar spine. The shortest pedicle trajectory length, measuring 28.39 mm, was observed at the concave side of T1, while the longest length was at the concave side of L3. Minimal variation in the pedicle trajectory length was noted between the concave and convex sides in the thoracic and lumbar regions. Notably, significantly longer pedicle trajectory lengths were observed at the concave side of levels T3, T6, L2, L3, and L4 ($p < 0.05$; → Table 2). However, at most levels, the differences were not statistically significant.

Discussion

The pedicle screw has gained widespread acceptance as a valuable tool in AIS surgery. Its advantages are particularly evident in the correction of three-dimensional deformities and its superior pullout strength, leading to enhanced biomechanical stabilization.^{9,10} It is imperative to possess a comprehensive understanding of the morphometric anatomy of pedicles, particularly in cases of spinal deformity, to ensure the precise placement of pedicle screws and mitigate the complications associated with screw malposition. Literature reports a wide-ranging pedicle screw perforation rate of 1.2 to 65%.¹¹ The incidence of pedicle screw perforation in AIS surgery has been documented at 20.3%.¹² CT is

Table 1 Measurement outcome for pedicle width in patients diagnosed with adolescent idiopathic scoliosis (AIS) Lenke type 5

Level	Convex side		Concave side		p-Value
	Mean width (mm)	SD	Mean width (mm)	SD	
T1	4.13	1.47	3.71	1.08	0.076
T2	3.68	1.03	3.48	1.12	0.162
T3	3.08	0.81	2.74	0.93	0.004*
T4	2.79	0.92	2.83	0.74	0.828
T5	2.74	0.81	2.71	0.91	0.779
T6	2.83	0.88	2.82	0.94	0.621
T7	2.85	0.82	2.79	0.76	0.609
T8	3.15	0.83	3.04	0.66	0.865
T9	3.42	0.83	3.26	0.82	0.834
T10	3.76	1.05	3.61	1.05	0.571
T11	4.62	0.88	4.43	1.09	0.082
T12	5.26	1.07	4.51	1.11	0.004*
L1	4.94	1.03	4.57	0.98	0.021*
L2	4.97	1.03	4.68	1.14	0.011*
L3	5.02	1.22	4.89	1.26	0.089
L4	6.27	1.38	6.02	1.51	0.218
L5	9.07	1.89	8.71	2.21	0.448
L5	47.28	3.31	46.04	3.56	0.124

Abbreviation: SD, standard deviation.

*Statistically significant difference (p-Value less than 0.05).

Table 2 Measurement outcome of pedicle trajectory length in Lenke type 5 AIS

Level	Convex side		Concave side		p-Value
	Mean length (mm)	SD	Mean length (mm)	SD	
T1	28.63	2.34	28.39	3.08	0.476
T2	31.33	2.61	30.76	3.16	0.162
T3	31.94	2.82	33.31	2.64	0.031*
T4	34.75	3.26	35.56	2.66	0.057
T5	35.54	2.78	36.22	2.96	0.129
T6	36.76	2.96	37.55	3.27	0.012*
T7	37.91	2.71	38.59	2.85	0.109
T8	39.53	4.67	38.92	3.34	0.566
T9	40.35	2.49	40.32	2.11	0.816
T10	42.55	2.98	43.03	3.09	0.341
T11	44.41	3.32	43.51	3.22	0.186
T12	45.48	2.76	45.81	3.04	0.588
L1	46.37	3.12	47.71	2.81	0.051
L2	47.28	3.44	50.05	3.38	0.003*
L3	48.12	3.52	51.31	3.38	0.003*
L4	46.41	3.46	48.48	3.52	0.013*
L5	47.28	3.31	46.04	3.56	0.124

Abbreviations: AIS, adolescent idiopathic scoliosis; SD, standard deviation.

recognized as the preferred imaging modality for a thorough evaluation of osseous structures. There is a significant correlation between measurements obtained from CT scans and precise anatomical assessments of the vertebrae.¹³ This study presents the findings of CT analyses concerning the width of the pedicle and the length of the pedicle trajectory in patients diagnosed with AIS, specifically those classified as Lenke type 5.

The transverse pedicle width is a critical determinant of the safe accommodation of pedicle screws without breaching the lateral and medial cortex. Conversely, the use of a smaller-diameter pedicle screw may lead to failure due to reduced pullout strength.^{14,15} Abul-Kasim and Ohlin have observed that the pedicle morphology on the concave side demonstrates significantly smaller dimensions compared with the convex side in the apical region of the scoliotic curve.¹⁶ Liljenqvist and Hackenberg observed a noteworthy reduction in the endosteal transverse pedicle width on the concave side in the apical region of the thoracic spine. Conversely, in the lumbar spine, no significant differences were noted in the width between the concave and convex sides.² Upendra et al discovered that the pedicle width decreases from T1 to T3 to T4, gradually increasing at each level, ultimately reaching its maximum at L5 on both the concave and convex sides.¹⁷ Our study reveals that patients classified as Lenke type 5 AIS exhibit a significant decrease in transverse pedicle width on the concave side compared with the convex side within the apical region of the thoracolumbar spine, specifically between T12 and L2. Moreover, at the T3 level, the pedicle width is significantly smaller on the concave side. The narrowest pedicle width was recorded at the T5 level. Additionally, we identified a declining trend in pedicle width from the T1 level through either the T4 or T5 level, followed by an increasing trend from the T4 or T5 level up to the T12 level.

The pedicle trajectory length refers to the measurement from the outermost posterior cortex of the pedicle to the anterior cortex of the vertebral body, considering the long axis of the pedicle in the transverse plane. According to Krag et al, for optimal resistance to pullout forces, it is recommended to insert pedicle screws between 80 and 100% of the pedicle trajectory length.¹⁸ Nevertheless, the insertion of pedicle screws beyond the anterior cortex of the vertebral body may pose a risk of injury to the nervous system and surrounding viscera, such as the aorta, azygos vein, and esophagus. Careful consideration and precise application of these recommendations are essential to avoid potential complications. Liljenqvist et al have also reported on the longer trajectory length on the concave pedicle of the scoliotic curve compared with the convex side.¹⁹ Kotwicki et al found that the vertebral body drifts toward the concavity in the transverse plane with the rotation of the spine. Consequently, as the vertebral body is slightly shifted to the concave side, a longer pedicle trajectory length is observed on the concave side.²⁰ In our study, we observed that the length of the pedicle trajectory is slightly longer on the concave side compared with the convex side. This finding suggests that the concave side in the apical region may

accommodate a longer pedicle screw at the T3, T6, L2, L3, and L4 vertebral levels.

The study reveals that individuals with Lenke type 5 AIS among the Thai population typically demonstrate a reduced transverse pedicle width on the concave side of the apical region. Approximately 30.15% of all assessed pedicles exhibited a transverse width smaller than the diameter of the corresponding pedicle screw. The variations observed in pedicle width and trajectory length were statistically significant at certain levels. It is essential to recognize that this significance may stem from random variation within the data. The difference in width (0.3 mm) and trajectory length (1.6 mm) is minimal and does not possess clinical significance.

It is critical to identify the narrowest diameter of each pedicle when selecting the appropriate diameter for pedicle screws, as utilizing screws with a larger diameter may lead to violations of both the medial and lateral walls. This study underscores the necessity of paying particular attention to the narrower and more medially oriented concave pedicle, particularly at the apical region of the scoliotic curve, while planning for pedicle screw placement in a scoliotic spine. It is recommended that routine preoperative CT scans be performed to obtain a comprehensive understanding of pedicle morphology in each patient, thereby ensuring safer pedicle screw insertion with minimal complications.

It is essential to acknowledge that our current data may be limited in generalizability to the broader population and centered on a comprehensive assessment without conducting a separate gender-based analysis. Therefore, further study is necessary to investigate vertebral morphology in a more extensive sample of patients encompassing various Lenke types of AIS.

Ethical Approval

The study was approved by the ethics committee of Lerdsin Hospital.

Funding

None.

Conflict of Interest

None declared.

References

- 1 Roach JW. Adolescent idiopathic scoliosis. *Orthop Clin North Am* 1999;30(03):353–365, vii–viii
- 2 Liljenqvist U, Hackenberg L. Morphometric analysis of thoracic and lumbar vertebrae in idiopathic scoliosis. *Stud Health Technol Inform* 2002;88:382–386
- 3 Li G, Lv G, Passias P, et al. Complications associated with thoracic pedicle screws in spinal deformity. *Eur Spine J* 2010;19(09):1576–1584
- 4 Suk SI, Kim WJ, Lee SM, Kim JH, Chung ER. Thoracic pedicle screw fixation in spinal deformities: are they really safe? *Spine* 2001;26(18):2049–2057
- 5 O'Brien MF, Lenke LG, Mardjetko S, et al. Pedicle morphology in thoracic adolescent idiopathic scoliosis: is pedicle fixation an anatomically viable technique? *Spine* 2000;25(18):2285–2293

- 6 Hu X, Siemionow KB, Lieberman IH. Thoracic and lumbar vertebrae morphology in Lenke type 1 female adolescent idiopathic scoliosis patients. *Int J Spine Surg* 2014;8:30
- 7 Bunmaprasert T, Roobsoong A, Pongmanee S, Khunsree S, Lao-watthanaphong S. Safety entry point, size and direction for placement of thoracic pedicle screw: a cadaveric study. *J Med Assoc Thai* 2014;97(12):1344–1351
- 8 Lenke LG, Betz RR, Harms J, et al. Adolescent idiopathic scoliosis: a new classification to determine extent of spinal arthrodesis. *J Bone Joint Surg Am* 2001;83(08):1169–1181
- 9 Chan CYW, Kwan MK. Safety of pedicle screws in adolescent idiopathic scoliosis surgery. *Asian Spine J* 2017;11(06):998–1007
- 10 Zindrick MR, Wiltse LL, Widell EH, et al. A biomechanical study of intrapeduncular screw fixation in the lumbosacral spine. *Clin Orthop Relat Res* 1986;1(203):99–112
- 11 Deng Y, Zhou Y, Lu G, et al; South Univ. Complication of thoracic pedicle screw fixation in spinal deformities. *Zhong Nan Da Xue Xue Bao Yi Xue Ban* 2009;34(08):820–824
- 12 Kwan MK, Chiu CK, Gani SMA, Wei CCY. Accuracy and safety of pedicle screw placement in adolescent idiopathic scoliosis patients: a review of 2020 screws using computed tomography assessment. *Spine* 2017;42(05):326–335
- 13 Ketenci İE, Yanik HS, Erdem Ş. Pedicle morphometry of thoracic and lumbar vertebrae in adolescent idiopathic scoliosis. *Medeniyet Med J* 2018;33:69–74
- 14 Gao B, Gao W, Chen C, et al. What is the difference in morphologic features of the thoracic pedicle between patients with adolescent idiopathic scoliosis and healthy subjects? A CT-based case-control study. *Clin Orthop Relat Res* 2017;475(11):2765–2774
- 15 Zhang W, Takigawa T, Wu Y, Sugimoto Y, Tanaka M, Ozaki T. Accuracy of pedicle screw insertion in posterior scoliosis surgery: a comparison between intraoperative navigation and preoperative navigation techniques. *Eur Spine J* 2017;26(06):1756–1764
- 16 Abul-Kasim K, Ohlin A. Patients with adolescent idiopathic scoliosis of Lenke type-1 curve exhibit specific pedicle width pattern. *Eur Spine J* 2012;21(01):57–63
- 17 Upendra B, Meena D, Kandwal P, Ahmed A, Chowdhury B, Jayaswal A. Pedicle morphometry in patients with adolescent idiopathic scoliosis. *Indian J Orthop* 2010;44(02):169–176
- 18 Krag MH, Weaver DL, Beynon BD, Haugh LD. Morphometry of the thoracic and lumbar spine related to transpedicular screw placement for surgical spinal fixation. *Spine* 1988;13(01):27–32
- 19 Liljenqvist UR, Halm HF, Link TM. Pedicle screw instrumentation of the thoracic spine in idiopathic scoliosis. *Spine (Phila Pa 1976)* 1997;22(19):2239–2245
- 20 Kotwicki T, Napiontek M. Intravertebral deformation in idiopathic scoliosis: a transverse plane computer tomographic study. *J Pediatr Orthop* 2008;28(02):225–229