




# What Is the Suitable Wide Cage Size for Stand-alone LLIF in Asian Population: A Computed Tomography Scan–Based Study of a Dimension of Lumbar Endplate

Tinnakorn Pluemvitayaporn<sup>1</sup> Sahapap Tadee<sup>1</sup> Sombat Kunakornsawat<sup>1</sup> Suttinont Surapuchong<sup>1</sup>  
Warot Ratanakoosakul<sup>1</sup> Kijapat Tiracharnvut<sup>1</sup> Pritsanai Pruttikul<sup>1</sup> Chaiwat Piyasakulkaew<sup>1</sup>  
Piyabuth Kittithamvongs<sup>2</sup>

<sup>1</sup>Spine Unit, Department of Orthopaedic Surgery, Institute of Orthopedics, Lerdsin Hospital, College of Medicine, Rangsit University, Bangkok, Thailand

<sup>2</sup>Research Unit, Department of Orthopaedic Surgery, Institute of Orthopedics, Lerdsin Hospital, College of Medicine, Rangsit University, Bangkok, Thailand

Address for correspondence Tinnakorn Pluemvitayaporn, MD, Spine Unit, Department of Orthopaedic Surgery, Institute of Orthopedics, Lerdsin Hospital, College of Medicine, Rangsit University, 190 Silom Road, Bangkok 10500, Thailand (e-mail: dr.tinnakorn@gmail.com).

Asian J Neurosurg 2025;20:119–125.

## Abstract

**Objective** The objective of this study is to establish a precise database detailing the width of vertebral endplates, the depth of vertebral endplates (anterior–posterior [A-P] width), and the height of intervertebral discs within the lumbar spine of the Asian population.

**Materials and Methods** The stand-alone lateral lumbar interbody fusion (LLIF) procedure is increasingly popular for minimally invasive spine surgery and has demonstrated effectiveness in treating various spinal pathologies. Previous studies have indicated that the use of a 26-mm wide cage in stand-alone LLIF can significantly decrease the incidence of cage subsidence. However, most of these studies were conducted on the Caucasian population, which has a larger anatomical structure compared with the Asian population. Consequently, the appropriate wide cage size suitable for stand-alone LLIF in the Asian population has not been previously explored. Ninety-one computed tomography (CT) images were obtained from patients who presented with back pain and had negative imaging results between 2017 and 2021. These images were analyzed using the Picture Archiving Communication System to assess the vertebral body's topography. The analysis involved measuring the vertebral endplate width, vertebral endplate depth (A-P width), and intervertebral disc height.

**Results** The findings of this study reveal that there is a noticeable increase in the overall width, depth, and intervertebral disc height of the lumbar vertebrae from the upper to the lower regions. Additionally, the morphometric attributes of the lumbar vertebrae observed in this study closely resemble those of Caucasian subjects.

## Keywords

- ▶ stand-alone LLIF
- ▶ lateral lumbar interbody fusion
- ▶ lumbar spine
- ▶ dimension
- ▶ lumbar endplate diameter

article published online  
December 2, 2024

DOI <https://doi.org/10.1055/s-0044-1796668>.  
ISSN 2248-9614.

© 2024. Asian Congress of Neurological Surgeons. All rights reserved.

This is an open access article published by Thieme under the terms of the Creative Commons Attribution-NonDerivative-NonCommercial-License, permitting copying and reproduction so long as the original work is given appropriate credit. Contents may not be used for commercial purposes, or adapted, remixed, transformed or built upon. (<https://creativecommons.org/licenses/by-nc-nd/4.0/>)

Thieme Medical and Scientific Publishers Pvt. Ltd., A-12, 2nd Floor, Sector 2, Noida-201301 UP, India

**Conclusion** The morphometric measurements of the lumbar vertebrae in the Asian population closely resemble those of Caucasian subjects. As a result, it is suggested that a 26-mm wide cage may be a suitable option for stand-alone LLIF in the Asian population.

## Introduction

Minimally invasive spine surgery represents an increasingly favored method of addressing spinal disorders. A prominent technique within this approach is the lateral lumbar interbody fusion (LLIF), which has demonstrated efficacy in treating various spinal pathologies, including low-to-moderate spinal canal stenosis, lateral recess and/or foraminal canal stenosis, low-grade spondylolisthesis (grades I–II), degenerative scoliosis, and degenerative disc disease.<sup>1,2</sup> Previously, the standard LLIF with supplemental fixation procedure typically utilized an 18-mm anterior–posterior (A-P) cage, but there have been recent developments in the form of 22- and 26-mm wide cages aimed at reducing the risk of subsidence, particularly in osteoporotic patients.<sup>3</sup>

Stand-alone LLIF is the trans-psoas approach technique that offers the advantage of maintaining segmental stability without supplemental fixation. However, previous studies have indicated higher rates of cage subsidence when LLIF is performed without additional instrumentation.<sup>4,5</sup> Recent literature suggests that using a 26-mm wide cage for stand-alone LLIF results in a significantly reduced cage subsidence rate.<sup>2,3</sup> It is important to note that most of the existing literature is based on studies conducted on Caucasian populations, which have a larger anatomical structure compared with Asians. Therefore, further studies on the morphologic vertebral body in the Asian population are warranted to determine the most suitable wide cage size for stand-alone LLIF.

The purpose of this study is to establish a precise database concerning the width of the vertebral endplate, A-P width of the vertebral endplate, and intervertebral disc height of the lumbar spine in Asian populations.

## Materials and Methods

A total of 91 digitized computed tomography (CT) images of the lumbosacral spine were obtained from patients experiencing back pain, all of whom had negative findings in their CT scans between 2017 and 2021. Approval for the study was obtained from the Committee on Human Rights Related to Research Involving Human Subjects at Lerdsin Hospital. The digitized CT images underwent measurement and analysis using the Picture Archiving Communication System. The analysis encompassed the measurement of the superior and inferior vertebral endplate width, superior and inferior vertebral endplate depth (A-P width), and intervertebral disc height of the lumbar spine. The superior vertebral endplate width is determined as the maximum distance of the superior endplate, measured from a tangen-

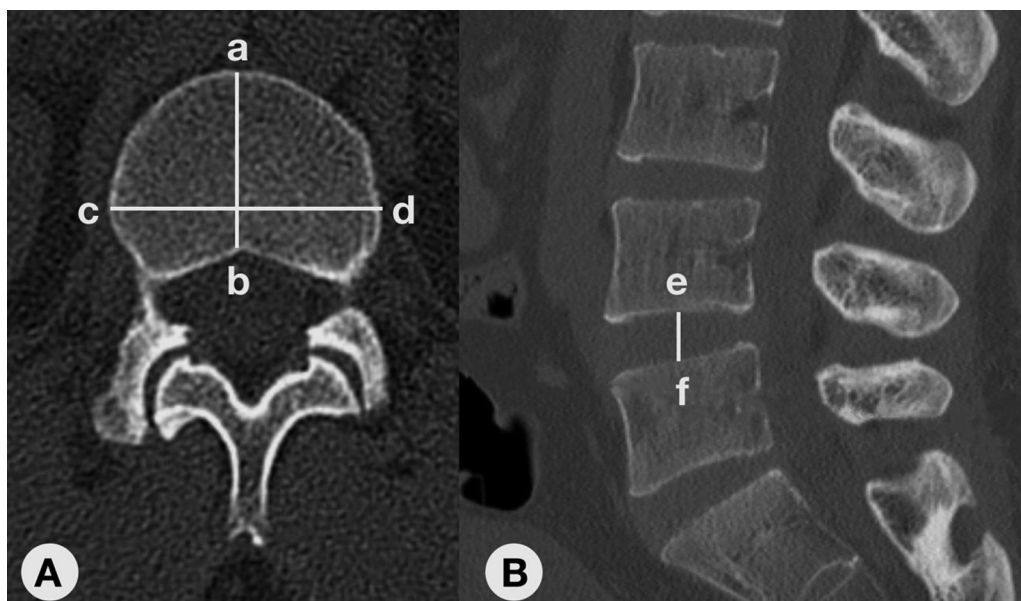
tially drawn line connecting the lateralmost edges of the superior endplate (►Fig. 1A). Similarly, the inferior vertebral endplate width is ascertained as the maximum distance of the inferior endplate, measured from a tangentially drawn line connecting the lateralmost edges of the inferior endplate. Moreover, the superior vertebral endplate depth (A-P width) is defined as the maximum distance of the superior endplate, measured from a perpendicular line drawn from the anteriormost edge of the superior endplate to the posterior edge of the superior endplate (►Fig. 1A). Likewise, the inferior vertebral endplate depth (A-P width) is defined as the maximum distance of the inferior endplate, measured from a perpendicular line drawn from the anteriormost edge of the inferior endplate to the posterior edge of the inferior endplate. Finally, the intervertebral disc height is defined as the maximum distance of the intervertebral disc, measured from a vertical line drawn from the inferior endplate of the cephalad vertebra to the superior endplate of the caudal vertebra (►Fig. 1B). The data will be reported using the mean and standard deviation (SD). An intraclass correlation coefficient (ICC) was employed to assess the reliability of the measurements. Given that a single observer (T.P. for blinding) conducted all the measurements, a two-way random-effects model with absolute agreement analysis was utilized.

## Results

A total of 91 digitized CT images encompassing 455 lumbar spine vertebrae were subject to measurement. The cohort comprised 52 males (57.1%) and 39 females (42.86%), with a mean age of 46.0 years (SD = 13.7), ranging from 17 to 69 years. The reliability analysis exhibited an ICC value of 1.00 across all measurements. ►Table 1 succinctly presents the mean values, SDs, and range of data for the lumbar spine (L1–L5) derived from measurements of axial and sagittal CT images of the 91 subjects.

### Superior Vertebral Endplate Width

The mean dimensions of the superior vertebral endplate width were as follows: at L1,  $39 \pm 2.7$  mm for females,  $43.3 \pm 3.3$  mm for males, and  $41.4 \pm 3.7$  mm overall; at L2,  $40.6 \pm 2.5$  mm for females,  $45.8 \pm 3.2$  mm for males, and  $43.6 \pm 3.9$  mm overall; at L3,  $43.1 \pm 3.1$  mm for females,  $48.1 \pm 3.7$  mm for males, and  $45.9 \pm 4.2$  mm overall; at L4,  $45.2 \pm 3.4$  mm for females,  $49.6 \pm 3.6$  mm for males, and  $47.7 \pm 4.1$  mm overall; and at L5,  $46.1 \pm 3.4$  mm for females,  $50.8 \pm 3.6$  mm for males, and  $48.8 \pm 4.2$  mm overall. The average superior vertebral endplate width of females was



**Fig. 1** (A, B) Measurement of superior vertebral endplate depth is defined as the maximum distance of the superior endplate, measured from the perpendicular line drawn from the anteriormost edge of the superior endplate (a) to the posterior edge of the superior endplate (b). Measurement of superior vertebral endplate width is defined as the maximum distance of the superior endplate, measured from the line drawn tangentially from the lateralmost edge of the superior endplate (c) to another lateralmost edge of the superior endplate (d). Measurement of the intervertebral disc height is defined as the maximum distance of the intervertebral disc, measured from the vertical line drawn from the inferior endplate of the cephalad vertebra (e) to the superior endplate of the caudal vertebra (f).

consistently smaller than that of males. Furthermore, there was a statistically significant increase in superior vertebral endplate width from L1 to L5 ( $p < 0.05$ ).

#### Inferior Vertebral Endplate Width

The mean dimensions of the inferior vertebral endplate width were as follows: at L1,  $40.4 \pm 2.6$  mm for females,  $45.3 \pm 3.3$  mm for males, and  $43.2 \pm 3.9$  mm overall; at L2,  $42.7 \pm 3.1$  mm for females,  $47.7 \pm 3.5$  mm for males, and  $45.6 \pm 4.1$  mm overall; at L3,  $45.4 \pm 3.3$  mm for females,  $50.5 \pm 3.8$  mm for males, and  $48.3 \pm 4.4$  mm overall; at L4,  $46.6 \pm 3.2$  mm for females,  $51.3 \pm 3.4$  mm for males, and  $49.3 \pm 4.0$  mm overall; and at L5,  $46.8 \pm 3.0$  mm for females,  $50.2 \pm 3.2$  mm for males, and  $48.7 \pm 3.5$  mm overall. The mean inferior vertebral endplate width of females was found to be generally smaller than that of males. Additionally, there was a statistically significant increase in the inferior vertebral endplate width from L1 to L5 ( $p < 0.05$ ).

#### Superior Vertebral Endplate Depth (A-P Width)

The mean dimensions of the superior vertebral endplate depth at L1 were found to be  $28.8 \pm 2.5$  mm in females and  $31.6 \pm 3.0$  mm in males, with an overall measure of  $30.4 \pm 3.1$  mm. At L2, the measurements were  $30.2 \pm 2.5$  mm in females,  $33.1 \pm 2.7$  mm in males, and  $31.8 \pm 3.0$  mm overall. For L3, the dimensions were  $31.8 \pm 2.7$  mm in females,  $34.4 \pm 2.3$  mm in males, and  $33.3 \pm 2.8$  mm overall. At L4, the measurements were  $32.4 \pm 2.2$  mm in females,  $35.0 \pm 2.5$  mm in males, and  $33.9 \pm 2.7$  mm overall. Finally, at L5, the dimensions were  $32.9 \pm 3.3$  mm in females,  $35.8 \pm 3.1$  mm in males, and  $34.5 \pm 3.5$  mm overall.

It was observed that the mean dimensions of the superior vertebral endplate depth were smaller in females compared with males. Moreover, the data indicated a statistically significant increase in the superior vertebral endplate depth from L1 to L5 ( $p < 0.05$ ).

#### Inferior Vertebral Endplate Depth (A-P Width)

The mean dimensions of the inferior vertebral endplate depth at L1 were  $29.7 \pm 2.2$  mm for females,  $32.4 \pm 3.1$  mm for males, and an overall of  $31.3 \pm 3.0$  mm. At L2, the dimensions were  $31.9 \pm 3.0$  mm for females,  $34.2 \pm 2.7$  mm for males, and an overall of  $33.2 \pm 3.0$  mm. At L3, the measurements were  $32.1 \pm 2.2$  mm for females,  $35.0 \pm 2.2$  mm for males, and an overall of  $33.7 \pm 2.6$  mm. Moving to L4, the dimensions were  $32.9 \pm 1.9$  mm for females,  $35.8 \pm 3.1$  mm for males, and an overall of  $34.6 \pm 3.0$  mm. Finally, at L5, the measurements were  $33.5 \pm 2.6$  mm for females,  $35.7 \pm 3.1$  mm for males, and an overall of  $34.8 \pm 3.1$  mm. It was observed that the average inferior vertebral endplate depth in females was smaller than that in males. Furthermore, there was a statistically significant increase in the inferior vertebral endplate depth from L1 to L5 ( $p < 0.05$ ).

#### Intervertebral Disc Height

The mean intervertebral disc height at T12/L1 was  $9.3 \pm 1.6$  mm in females and  $9.0 \pm 1.6$  mm in males, with an overall average of  $9.1 \pm 1.6$  mm. At L1/L2, the heights were  $10.1 \pm 1.8$  mm in females,  $10.0 \pm 1.7$  mm in males, and  $10.0 \pm 1.7$  mm overall. Moving to L2/L3, the respective values increased to  $10.4 \pm 2.0$  mm in females and  $11.8 \pm 2.0$  mm in males, with an overall average of  $11.2 \pm 2.1$  mm. Continuing to L3/L4, the values rose further to  $11.5 \pm 2.0$  mm in females,

**Table 1** The mean measurements of various anatomical dimensions, encompassing SVEW, SVED, IVEW, IVED, and IVDH derived from a cohort of 91 subjects

Parameters (mm)	Females	Males	t-test	Overall
<b>L1</b>				
SVEW	39 ± 2.7 (33.7–45.2)	43.3 ± 3.3 (36.6–51.0)	$p < 0.001$	41.4 ± 3.7 (33.7–51.0)
SVED	28.8 ± 2.5 (24.1–33.8)	31.6 ± 3.0 (25.1–41.0)	$p < 0.001$	30.4 ± 3.1 (24.1–41.0)
IVEW	40.4 ± 2.6 (35.9–47.3)	45.3 ± 3.3 (40.0–51.9)	$p < 0.001$	43.2 ± 3.9 (35.9–51.9)
IVED	29.7 ± 2.2 (24.3–34.1)	32.4 ± 3.1 (23.1–41.0)	$p < 0.001$	31.3 ± 3.0 (23.1–41.0)
IVDH (T12/L1)	9.3 ± 1.6 (5.7–12.5)	9.0 ± 1.6 (5.0–13.0)	$p = 0.33$	9.1 ± 1.6 (5.0–13.0)
<b>L2</b>				
SVEW	40.6 ± 2.5 (34.9–46.8)	45.8 ± 3.2 (38.9–52.9)	$p < 0.001$	43.6 ± 3.9 (34.9–52.9)
SVED	30.2 ± 2.5 (26.0–38.8)	33.1 ± 2.7 (26.6–41.3)	$p < 0.001$	31.8 ± 3.0 (26.0–41.3)
IVEW	42.7 ± 3.1 (36.0–50.0)	47.7 ± 3.5 (41.1–55.7)	$p < 0.001$	45.6 ± 4.1 (36.0–55.7)
IVED	31.9 ± 3.0 (26.0–41.3)	34.2 ± 2.7 (28.0–41.6)	$p < 0.001$	33.2 ± 3.0 (26.0–41.6)
IVDH (L1/L2)	10.1 ± 1.8 (6.6–13.7)	10.0 ± 1.7 (6.1–14.0)	$p = 0.93$	10.0 ± 1.7 (6.1–14.0)
<b>L3</b>				
SVEW	43.1 ± 3.1 (35.4–48.4)	48.1 ± 3.7 (38.0–55.8)	$p < 0.001$	45.9 ± 4.2 (35.4–55.8)
SVED	31.8 ± 2.7 (22.5–37.4)	34.4 ± 2.3 (28.6–39.6)	$p < 0.001$	33.3 ± 2.8 (22.5–39.6)
IVEW	45.4 ± 3.3 (37.8–53.3)	50.5 ± 3.8 (42.2–58.4)	$p < 0.001$	48.3 ± 4.4 (37.8–58.4)
IVED	32.1 ± 2.2 (27.1–36.4)	35.0 ± 2.2 (30.0–40.2)	$p < 0.001$	33.7 ± 2.6 (27.1–40.2)
IVDH (L2/L3)	10.4 ± 2.0 (5.2–14.4)	11.8 ± 2.0 (6.7–16.6)	$p = 0.001$	11.2 ± 2.1 (5.2–16.6)
<b>L4</b>				
SVEW	45.2 ± 3.4 (36.4–54.0)	49.6 ± 3.6 (40.7–57.7)	$p < 0.001$	47.7 ± 4.1 (36.4–57.7)
SVED	32.4 ± 2.2 (28.6–38.2)	35.0 ± 2.5 (29.0–42.2)	$p < 0.001$	33.9 ± 2.7 (28.6–42.2)
IVEW	46.6 ± 3.2 (37.9–53.5)	51.3 ± 3.4 (42.7–58.4)	$p < 0.001$	49.3 ± 4.0 (37.9–58.4)
IVED	32.9 ± 1.9 (29.0–37.5)	35.8 ± 3.1 (30.0–46.6)	$p < 0.001$	34.6 ± 3.0 (29.0–46.6)
IVDH (L3/L4)	11.5 ± 2.0 (6.7–16.1)	12.5 ± 2.1 (8.2–19.8)	$p = 0.04$	12.1 ± 2.1 (6.7–19.8)
<b>L5</b>				
SVEW	46.1 ± 3.4 (39.3–54.0)	50.8 ± 3.6 (44.1–59.5)	$p < 0.001$	48.8 ± 4.2 (39.3–59.5)
SVED	32.9 ± 3.3 (23.2–43.6)	35.8 ± 3.2 (29.1–45.5)	$p < 0.001$	34.5 ± 3.5 (23.2–45.5)
IVEW	46.8 ± 3.0 (40.8–53.9)	50.2 ± 3.2 (41.9–58.3)	$p < 0.001$	48.7 ± 3.5 (40.8–58.3)
IVED	33.5 ± 2.6 (27.9–40.8)	35.7 ± 3.1 (29.3–44.6)	$p < 0.001$	34.8 ± 3.1 (27.9–44.6)
IVDH (L4/L5)	11.5 ± 2.1 (6.7–15.9)	13.0 ± 2.2 (8.4–19.4)	$p = 0.001$	12.4 ± 2.3 (6.7–19.4)

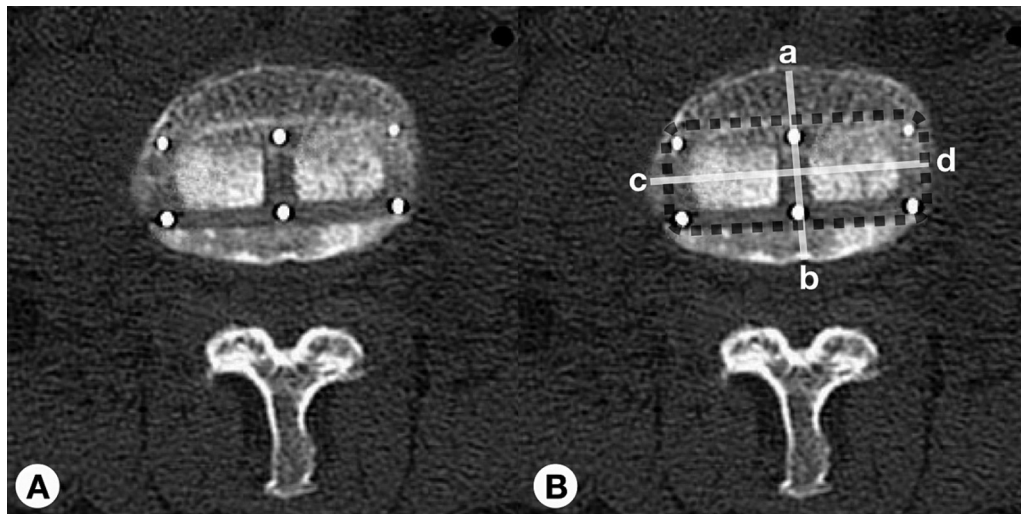
Abbreviations: IVDH, intervertebral disc height; IVED, inferior vertebral endplate depth; IVEW, inferior vertebral endplate width; SVED, superior vertebral endplate depth; SVEW, superior vertebral endplate width.

12.5 ± 2.1 mm in males, and an overall average of 12.1 ± 2.1 mm. Finally, at L4/L5, the heights were 11.5 ± 2.1 mm in females, 13.0 ± 2.2 mm in males, and an overall average of 12.4 ± 2.3 mm. Overall, there was a consistent increase in intervertebral disc height from T12/L1 to L4/L5. Statistical analysis indicated no significant differences in intervertebral disc heights at the T12/L1, L1/L2, and L3/L4 levels ( $p > 0.05$ ). However, significant differences were observed at L2/L3 and L4/L5 ( $p < 0.05$ ).

## Discussion

Over the past few decades, LLIF has emerged as a widely favored minimally invasive spinal procedure for addressing

various spinal disorders. Initially introduced by Ozgur<sup>6</sup> in 2001, the primary goal of LLIF is to achieve indirect decompression of the neural elements, restore intervertebral disc height, and increase the central and foraminal canal diameter, while avoiding the significant complications associated with anterior lumbar interbody fusion, such as bowel or great vessel injuries, retrograde ejaculation, and arterial thromboembolism.<sup>7–11</sup> Additionally, to minimize operative time, intraoperative blood loss, and rates of muscular structure damage, stand-alone LLIF, a relatively trans-psoas approach of cage placement without supplemental fixation, may be employed. Nevertheless, a significant concern with this procedure is determining the appropriate cage size and location of cage placement, as improper placement can



**Fig. 2** (A, B) An axial computed tomographic image showed an 18-mm wide cage position following the LLIF procedure performed on a Thai patient (A). Measurement of intervertebral endplate depth (a–b) was 30.4 mm, intervertebral endplate width (c–d) was 45.2 mm, and calculating of footplate-to-vertebral body endplate ratio was 0.6 (B). LLIF, lateral lumbar interbody fusion.

lead to several complications, including neural structure impingement or damage, cage migration, or cage subsidence.<sup>12,13</sup>

Regev et al<sup>14</sup> observed a higher incidence of cage overhang when the insertion site is located in the anterior one-third of the disc space, potentially resulting in serious complications, such as impingement of the retroperitoneal vessels, retroperitoneal seromas, hematomas, and radiculitis of adjacent nerve roots. Conversely, undersized cage placement can lead to postoperative cage subsidence, resulting in potential loss of indirect decompression due to bony structure collapse and condensation around the interbody cage.<sup>15–17</sup> Furthermore, the rate of subsidence depends on the cage width, with Le et al<sup>18</sup> reporting a 14.1% subsidence rate using an 18-mm wide cage compared with only 1.9% when using a 22-mm wide cage. It is widely agreed that proper cage placement involves using a large cage length and lateral placement to maximize contact with cortical bone, ensuring that the implant spans the lateral borders of the ring apophysis.<sup>5</sup> There is also a consensus that the cage center should lie within the middle 20% of the vertebral body, based on available semiquantitative data in the literature.<sup>19–21</sup> However, consensus on the proper size of the cage width in stand-alone LLIF has not been reached.

To reduce subsidence in LLIF, one of the major concerns for this issue is the cage dimensions.<sup>22</sup> According to Le et al,<sup>18</sup> the appropriate cage length is contingent on the distance of the periphery of the end plates. It becomes pertinent only if the implant does not fully reach the peripheral endplate. Hence, the width of the cage holds greater significance than the length, as the increased width provides enhanced biomechanical advantages, unlike the increased length. Prior literature has indicated that subsidence is linked to a low footplate-to-vertebral body endplate ratio (<0.5), low bone mineral density, and nonsupplemented fusion.<sup>2,23–26</sup> Currently, there are three

standard wide cage sizes—18, 22, and 26 mm—for the LLIF procedure. Custom-made width cages are not widely adopted and pose challenges in production (►Fig. 2). Lang et al<sup>2</sup> conducted an analysis on the implementation of a 26-mm wide cage in nine Caucasian patients for stand-alone LLIF, comparing the outcomes with previous cases using 18 and 22-mm wide cages. Their study established that using a 26-mm wide cage significantly reduced the incidence of cage subsidence compared with the 18- and 22-mm wide cages.

The morphological parameters of the lumbar spine have been described previously, but most of the studies have been conducted on Caucasian subjects.<sup>27–38</sup> Only a few studies were evaluated in Mongolian subjects.<sup>39–41</sup>

Our study demonstrated that the width of the superior vertebral endplate is consistently smaller than that of the inferior vertebral endplate within the same vertebra. Additionally, the width of the vertebral endplate generally exhibits an increasing trend toward the lower vertebral levels. In this examination, the range of vertebral endplate depth varied from 22.5 to 46.6 mm. Overall, the inferior vertebral endplate exhibited a greater depth compared with the superior vertebral endplate within the same vertebra. Nevertheless, the average depth of the superior and inferior vertebral endplates was found to be similar within the same disc space level.

Based on the geometrical features of lumbar vertebrae documented in previous literature, ►Table 2 presents a comparison of the various parameters measured in our study with those from previous studies. Our findings reveal similarities in the morphometric characteristics of lumbar vertebrae between Caucasian subjects and our research cohort. Consequently, it is suggested that a 26-mm wide cage may be appropriate for stand-alone LLIF in the Asian population.

Our study has some limitations. Primarily, the data were derived from individuals visiting a single institution, which

**Table 2** A comparative analysis of the average measurements of the SVEW, SVED, IVEW, IVED, and IVDH

Parameters (mm)	Panjabi et al <sup>27</sup>	Berry et al <sup>28</sup>	Wang et al <sup>29</sup>	Tan et al <sup>39</sup>	Current study
<b>L1</b>					
SVEW	41.2 ± 1.0	45.2 ± 4.6	45.3 ± 3.7	42.7 ± 0.4	41.4 ± 3.7
SVED	34.1 ± 1.3	31.9 ± 3.7	34.8 ± 3.2	32.3 ± 0.5	30.4 ± 3.1
IVEW	43.3 ± 0.8	49.1 ± 3.7	47.6 ± 4.0	46.2 ± 0.6	43.2 ± 3.9
IVED	35.3 ± 1.3	32.3 ± 3.5	33.5 ± 2.9	33.6 ± 0.6	31.3 ± 3.0
IVDH (T12/L1)	N/A	N/A	N/A	N/A	9.1 ± 1.6
<b>L2</b>					
SVEW	42.6 ± 0.7	47.7 ± 4.7	47.0 ± 3.5	44.9 ± 0.5	43.6 ± 3.9
SVED	34.6 ± 1.1	33.3 ± 3.7	35.7 ± 2.3	33.3 ± 0.6	31.8 ± 3.0
IVEW	45.5 ± 1.1	54.8 ± 4.8	50.3 ± 3.6	48.6 ± 0.4	45.6 ± 4.1
IVED	34.9 ± 0.7	33.4 ± 3.4	36.2 ± 2.8	34.4 ± 0.6	33.2 ± 3.0
IVDH (L1/L2)	N/A	N/A	N/A	N/A	10.0 ± 1.7
<b>L3</b>					
SVEW	44.1 ± 0.9	49.6 ± 3.2	48.0 ± 3.1	47.0 ± 0.4	45.9 ± 4.2
SVED	35.2 ± 1.1	33.9 ± 3.3	35.7 ± 3.1	35.2 ± 0.3	33.3 ± 2.8
IVEW	48.0 ± 1.2	53.8 ± 3.7	51.5 ± 3.4	51.2 ± 0.4	48.3 ± 4.4
IVED	34.8 ± 1.2	34.2 ± 3.3	35.6 ± 2.8	35.6 ± 0.7	33.7 ± 2.6
IVDH (L2/L3)	N/A	N/A	N/A	N/A	11.2 ± 2.1
<b>L4</b>					
SVEW	46.6 ± 1.2	51.2 ± 5.6	51.3 ± 3.7	49.4 ± 0.2	47.7 ± 4.1
SVED	35.5 ± 0.9	34.9 ± 3.4	35.8 ± 2.8	36.3 ± 0.6	33.9 ± 2.7
IVEW	49.5 ± 1.4	50.9 ± 4.6	53.6 ± 3.7	53.3 ± 0.6	49.3 ± 4.0
IVED	33.9 ± 0.9	35.6 ± 3.1	36.1 ± 2.8	35.6 ± 0.7	34.6 ± 3.0
IVDH (L3/L4)	N/A	N/A	N/A	N/A	12.1 ± 2.1
<b>L5</b>					
SVEW	47.3 ± 1.2	53.4 ± 4.4	53.0 ± 4.1	48.9 ± 0.4	48.8 ± 4.2
SVED	34.7 ± 1.2	35.1 ± 2.8	35.5 ± 2.9	35.8 ± 0.6	34.5 ± 3.5
IVEW	49.4 ± 1.4	52.7 ± 4.3	52.3 ± 4.7	51.4 ± 0.5	48.7 ± 3.5
IVED	33.2 ± 0.9	34.5 ± 3.0	34.7 ± 3.2	33.8 ± 0.5	34.8 ± 3.1
IVDH (L4/L5)	N/A	N/A	N/A	N/A	12.4 ± 2.3

Abbreviations: IVDH, intervertebral disc height; IVED, inferior vertebral endplate depth; IVEW, inferior vertebral endplate width; N/A, not available; SVED, superior vertebral endplate depth; SVEW, superior vertebral endplate width.

may result in variances in morphometric parameters between our demographic and patients from diverse geographic regions. Additionally, potential measurement errors exist; however, we mitigated this concern by averaging three measurements and conducting ICC analysis, which demonstrated strong correlations across all parameters. Finally, our study solely focuses on the morphometrics of the vertebral body without clinical application, underscoring the necessity for further clinical investigations.

## Conclusion

This study has compiled a dataset detailing the morphometric characteristics of lumbar vertebrae within the Asian population. Results indicate that the dimensions of lumbar

vertebrae in this study align closely with those observed in previous studies on the Caucasian population. This data could potentially inform surgical strategizing and aid in the selection of appropriately sized wide cages for stand-alone LLIF procedures within the Asian demographic.

### Ethical Approval

The study was approved by the ethics committee of Lerdsin Hospital.

### Funding

None.

### Conflict of Interest

None declared.

## References

- 1 Cappuccino A, Cornwall GB, Turner AW, et al. Biomechanical analysis and review of lateral lumbar fusion constructs. *Spine (Phila Pa 1976)* 2010;35(26, suppl):S361–S367
- 2 Lang G, Navarro-Ramirez R, Gandevia L, et al. Elimination of subsidence with 26-mm-wide cages in extreme lateral interbody fusion. *World Neurosurg* 2017;104:644–652
- 3 Pimenta L, Turner AW, Dooley ZA, Parikh RD, Peterson MD. Biomechanics of lateral interbody spacers: going wider for going stiffer. *ScientificWorldJournal* 2012;2012:381814
- 4 Marchi L, Abdala N, Oliverira L, Amaral R, Coutinho E, Pimenta L. Stand-alone lateral interbody fusion for the treatment of low-grade degenerative spondylolisthesis. *ScientificWorldJournal* 2012;2021:456364
- 5 Marchi L, Abdala N, Oliveira L, Amaral R, Coutinho E, Pimenta L. Radiographic and clinical evaluation of cage subsidence after stand-alone lateral interbody fusion. *J Neurosurg Spine* 2013;19:110–118
- 6 Ozgur BM, Aryan HE, Pimenta L, Taylor WR. Extreme lateral interbody fusion (XLIF): a novel surgical technique for anterior lumbar interbody fusion. *Spine J* 2006;6(04):435–443
- 7 Baker JK, Reardon PR, Reardon MJ, Heggeness MH. Vascular injury in anterior lumbar spine surgery. *Spine (Phila Pa 1976)* 1993;18:2227–2230
- 8 Regan JJ, McAfee PC, Guyer RD, Aronoff RJ. Laparoscopic fusion of the lumbar spine in a multi-center series of the first 34 consecutive patients. *Surg Laparosc Endosc* 1996;6:459–468
- 9 Christensen FB, Bungler CE. Retrograde ejaculation after retroperitoneal lower lumbar interbody fusion. *Int Orthop* 1997;21:176–180
- 10 Flynn JC, Price CT. Sexual complications of anterior fusion of the lumbar spine. *Spine (Phila Pa 1976)* 1984;9:489–492
- 11 Hackenberg L, Liljenqvist U, Halm H, Winkelmann W. Occlusion of the left common iliac artery following anterior lumbar interbody fusion. *J Spinal Disord* 2001;14:365–368
- 12 Knight RQ, Schwaegler P, Hanscom D, Roh J. Direct lateral lumbar interbody fusion for degenerative conditions: early complication profile. *J Spinal Disord Tech* 2009;22:34–37
- 13 Daffner SD, Wang JC. Migrated XLIF cage: case report and discussion of surgical technique. *Orthopaedics (Glendale Calif)* 2010;33:518
- 14 Regev GJ, Haloman S, Chen L, et al. Incidence and prevention of intervertebral cage overhang with minimally invasive lateral approach fusions. *Spine (Phila Pa 1976)* 2010;35(14):1406–1411
- 15 Hollowell JP, Vollmer DG, Wilson CR, Pintar FA, Yoganandan N. Biomechanical analysis of thoracolumbar interbody constructs. How important is the endplate? *Spine (Phila Pa 1976)* 1996;21(09):1032–1036
- 16 Lowe TG, Hashim S, Wilson LA, et al. A biomechanical study of regional endplate strength and cage morphology as it related to structural interbody support. *Spine (Phila Pa 1976)* 2004;29(21):2389–2394
- 17 Xu DS, Walker CT, Godzik J, Turner JD, Smith W, Uribe JS. Minimally invasive anterior, lateral, and oblique lumbar interbody fusion: a literature review. *Ann Transl Med* 2018;6(06):104
- 18 Le TV, Baaj AA, Dakwar E, et al. Subsidence of polyetheretherketone intervertebral cages in minimally invasive lateral retroperitoneal transposas lumbar interbody fusion. *Spine (Phila Pa 1976)* 2012;37(14):1268–1273
- 19 Kepler CK, Huang RC, Sharma AK, et al. Factors influencing segmental lumbar lordosis after transposas interbody fusion. *Orthop Surg* 2012;4(02):71–75
- 20 Kepler CK, Sharma AK, Huang RC, et al. Indirect foramina decompression after lateral transposas interbody fusion. *J Neurosurg Spine* 2012;16(04):329–333
- 21 Siu TL, Najafi E, Lin K. A radiographic analysis of cage positioning in lateral transposas lumbar interbody fusion. *J Orthop* 2016;22(01):142–146
- 22 Marulanda GA, Nayak A, Murtagh R, Santoni BG, Billys JB, Castellvi AE. A cadaveric radiographic analysis on the effect of extreme lateral interbody fusion cage placement with supplementary internal fixation on indirect spine decompression. *J Spinal Disord Tech* 2014;27:263–270
- 23 Kim MC, Chung HT, Cho JL, Kim DJ, Chung NS. Subsidence of polyetheretherketone cage after minimally invasive transforaminal lumbar interbody fusion. *J Spinal Disord Tech* 2013;26:87–92
- 24 Bhatia NN, Lee KH, Bui CN, Luna M, Wahba GM, Lee TQ. Biomechanical evaluation of an expandable cage in single-segment posterior lumbar interbody fusion. *Spine (Phila Pa 1976)* 2012;37(02):E79–E85
- 25 Karikari IO, Grossi PM, Nimjee SM, et al. Minimally invasive lumbar interbody fusion in patients older than 70 years of age: analysis of peri- and postoperative complications. *Neurosurgery* 2011;68:897–902
- 26 Lau D, Song Y, Guan Z, La Marca F, Park P. Radiologic outcomes of static versus expandable titanium cages after corpectomy: a retrospective cohort analysis of subsidence. *Neurosurgery* 2013;72:529–539
- 27 Panjabi MM, Goel V, Oxland T, et al. Human lumbar vertebrae. Quantitative three-dimensional anatomy. *Spine (Phila Pa 1976)* 1992;17:299–306
- 28 Berry JL, Moran JM, Berg WS, Steffee AD. A morphometric study of human lumbar and selected thoracic vertebrae. *Spine (Phila Pa 1976)* 1987;12(04):362–367
- 29 Wang Y, Battié MC, Videman T. A morphological study of lumbar vertebral endplates: radiographic, visual and digital measurements. *Eur Spine J* 2012;21:2316–2323
- 30 Zhou SH, McCarthy ID, McGregor AH, Coombs RH, Hughes SP. Geometrical dimensions of the lower lumbar vertebrae – analysis of data from digitized CT images. *Eur Spine J* 2000;9:242–248
- 31 Postacchini F, Ripani M, Carpano S. Morphometry of the lumbar vertebrae. An anatomic study in two Caucasoid ethnic groups. *Clin Orthop Relat Res* 1983;(172):296–303
- 32 Lakshmanan P, Purushothaman B, Dvorak V, Schratz W, Thambiraj S, Boszczyk M. Sagittal endplate morphology of the lower lumbar spine. *Eur Spine J* 2012;21(suppl 2):S160–S164
- 33 van der Houwen EB, Baron P, Veldhuizen AG, Burgerhof JG, van Ooijen PM, Verkerke GJ. Geometry of the intervertebral volume and vertebral endplates of the human spine. *Ann Biomed Eng* 2010;38(01):33–40
- 34 Hall LT, Esses SI, Noble PC, Kamaric E. Morphology of the lumbar vertebral endplates. *Spine (Phila Pa 1976)* 1998;23(14):1517–1522, discussion 1522–1523
- 35 Langrana NA, Kale SP, Edwards WT, Lee CK, Kopacz KJ. Measurement and analyses of the effects of adjacent endplate curvatures on vertebral stresses. *Spine J* 2006;6:267–278
- 36 Aharinejad S, Bertagnoli R, Wicke K, Firbas W, Schneider B. Morphometric analysis of vertebrae and intervertebral discs as a basis of disc replacement. *Am J Anat* 1990;189:69–76
- 37 Harrington J Jr, Sungarian A, Rogg J, Makker VJ, Epstein MH. The relation between vertebral endplate shape and lumbar disc herniations. *Spine (Phila Pa 1976)* 2001;26(19):2133–2138
- 38 Pappou IP, Cammisa FP Jr, Girardi FP. Correlation of endplate shape on MRI and disc degeneration in surgically treated patients with degenerative disc disease and herniated nucleus pulposus. *Spine J* 2007;7:32–38
- 39 Tan SH, Teo EC, Chua HC. Quantitative three-dimensional anatomy of lumbar vertebrae in Singaporean Asians. *Eur Spine J* 2002;11:152–158
- 40 Pan CL, Zhang BY, Zhu YH, et al. Morphologic analysis of Chinese lumbar endplate by three-dimensional computed tomography reconstructions for helping design lumbar disc prosthesis. *Medicine (Baltimore)* 2021;100(06):e24583
- 41 Chen H, Jiang D, Ou Y, Zhong J, Lv F. Geometry of thoracolumbar vertebral endplates of the human spine. *Eur Spine J* 2011;20(11):1814–1820