



Factors Predicting Recurrence and Resolution of Chronic SDH after Surgery

Shashin N. Vyas¹  Achal Sharma¹

¹Department of Neurosurgery, Sawai Man Singh Hospital, Jaipur, Rajasthan, India

Address for correspondence Achal Sharma, MS, MCH, Department of Neurosurgery, Sawai Man Singh Hospital, Jaipur 302021, Rajasthan, India (e-mail: sharma.achal@hotmail.com).

Asian J Neurosurg 2025;20:112–118.

Abstract

Keywords

- ▶ intracranial
- ▶ subdural
- ▶ recurrence
- ▶ chronic
- ▶ case series

Background Chronic subdural hematoma (SDH) is notoriously known to have high recurrence rates after surgery. We followed the course of 100 postoperative patients to determine the various stipulated factors associated with recurrence.

Materials and Methods In our study of 100 patients, there was a significant association with the size of SDH, amount of midline shift, increasing age, less duration of primary injury, and the increasing incidence of delayed resolution and recurrence. Also, the membrane of the patients with recurrent SDH was found to have a collection of neutrophils, plasma cells, histiocytes, and lymphocytes.

Conclusion Large size of SDH, increasing age, and recent injury were significant determining factors for delayed resolution and recurrence.

Introduction

A chronic blood accumulation that is stratified between the dura and the pial surface of the brain is known as a chronic subdural hematoma (CSDH). The mean age of presentation for CSDH is 76 years,^{1,2} with an incidence rate of *8 to 14 per 100,000 person-years.^{3–5} The prevalence of CSDH is estimated to significantly rise between 2010 and 2050 when the population older than 65 years is predicted to double.⁶ Even though neurosurgical procedures involving the evacuation of a CSDH are rather common and regular, recurrences requiring reoperation have been documented in 3 to 30% of instances, with the majority falling in the 20% range.^{7–10} Many studies conducted over the past few decades have attempted to determine the characteristics that are linked to recurrence in the aim of identifying which individuals will require closer monitoring throughout the postoperative phase (▶ **Table 1**). There is still a great deal of uncertainty surrounding the prediction of recurrence necessitating reoperation due to the variation between

studies, even though several factors, such as postoperative hematoma volume, appearance on imaging studies,⁸ and accumulation of angiogenic factors,¹¹ have been associated with recurrence necessitating reoperation.^{12–15} Lack of knowledge regarding a CSDH's normal life cycle is a major problem that prevents the research of recurrence requiring reoperation. A bridge vein rupture following a traumatic brain injury (TBI) causes gradual venous hemorrhage into the subdural region, according to an early notion about the development of CSDHs.¹⁶ This approach, however, has several problems, incorporating the fact that CSDHs can appear weeks after a TBI,¹⁷ a far slower course than even the most venous hemorrhages.¹⁸ Regardless of whether a tiny venous bleed is an initiating event, there is agreement that a traumatic process initiates a series of events that include exudation, inflammation, angiogenesis, recurrent small hemorrhages, fibrinolysis, and fibroblastic proliferation of the inner dural cells.¹⁷ The computed tomography (CT) scan provides the most precise understanding of the CSDH life

article published online
January 13, 2025

DOI <https://doi.org/10.1055/s-0044-1796663>.
ISSN 2248-9614.

© 2025. Asian Congress of Neurological Surgeons. All rights reserved.

This is an open access article published by Thieme under the terms of the Creative Commons Attribution-NonDerivative-NonCommercial-License, permitting copying and reproduction so long as the original work is given appropriate credit. Contents may not be used for commercial purposes, or adapted, remixed, transformed or built upon. (<https://creativecommons.org/licenses/by-nc-nd/4.0/>)

Thieme Medical and Scientific Publishers Pvt. Ltd., A-12, 2nd Floor, Sector 2, Noida-201301 UP, India

Table 1 Reported criteria of recurrence in chronic subdural hematomas (CSDHs)

Authors	Year	Criteria of recurrence
Nakaguchi et al ⁸	2001	Compression of the brain surface and a rise in the volume of the SDH on the operated side were noted
Abouzari et al ³³	2007	Clinical symptoms include localized neurological deficiency, new-onset headache, deterioration of an existing neurological or psychiatric condition, and change in mental status. Radiological: greater subdural fluid volume on the patient receiving treatment side compared with the volume measured 1–3 d postsurgery and compressed brain by subdural fluid observed on computed tomography (CT) scans obtained within 3 mo after surgery
Ramachandran and Hedge ¹⁰	2007	The reappearance of clinical symptoms and confirmed by a CT scan
Weigel et al	2007	Persistent or progressive neurological deficit accompanied by a space-occupying subdural lesion on the previously operated side
Torihashi et al ²⁶	2008	The ensuing hematoma volume increase in the neurologically compromised ipsilateral subdural region, which was followed by an additional surgery
Santarius et al ⁵	2009	Occurrence of symptoms and signs attributable to an ipsilateral hematoma seen on a CT scan within 6 mo of the original drainage procedure
Song et al	2014	Reappearance of symptoms after resolution of hematoma
Lee et al ²⁷	2016	Retrospective data on recurrent CSDH
Kim et al	2017	Recurrence as a case of reoperation due to an increase in hematoma volume in the ipsilateral subdural space seen on CT within 6 mo postoperatively
Cofano et al	2020	Symptoms and signs of ipsilateral increase of hematoma
Dubinski et al	2022	Reappearance or increase in hematoma on subsequent CT scan

cycle at the level of the individual patient., routinely obtained on all CSDH patients as part of the preoperative workup. A small group of studies have sought to know the history of CSDHs based on their presentation on CT.^{7,8,19} Despite the fact that no classification scheme has been able to fully account for the considerable variations across hematomas, Nakaguchi et al's is arguably the most popular and commonly accepted.^{8,11} According to their description, CSDHs develop from a homogeneous type (which goes from hypo- to hyperdense) to a separated type (which has a discernible hyper- and hypodense component), to a laminar type (with an inner hyperdense layer thought to reflect recent microhemorrhage), and finally to a trabecular type (with numerous septations). The laminar and separated varieties of hematoma are most likely to reoccur after surgical evacuation, whereas the trabecular type is least likely to do so, according to the original article by Nakaguchi et al and later studies.^{8,11} A trabecular appearance on a CT scan during the CSDH life cycle may signify that the hematoma is starting to disappear.^{8,11,19} The existence of eosinophils within the outer CSDH membrane has proven to be a particularly elusive phenomena in the process of elucidating the CSDH life cycle. Despite not being endogenous to the brain, eosinophils, which constitute up to 1% of white blood cells, can be found in as many as half of CSDH specimens.^{20,21} Eosinophils normally serve a crucial part in battling several sorts of infections and have been speculated to play a function against some types of cancer, while being best recognized for their pathological role in asthma and other allergic processes.²² As sentinels or observers of the surrounding environment, eosinophils can start

inflammatory or reparative processes in response to specific cytokines.²³ It has never been investigated how the outer membrane of a CSDH contains eosinophils about CT appearance. The current study examines the clinical, radiological, and surgical outcomes of CSDH surgical patients to determine the risk factors for bleeding that may reoccur and necessitate a repeat surgery.

Materials and Methods

This study was conducted retrospectively on 100 patients admitted to the Department of Neurosurgery, SMS Hospital, Jaipur from June 2021 to December 2022.

Double burr hole drainage was the most popular surgical procedure (81%) performed under local anesthesia. Bilateral double burr hole drainage (13%) without irrigation was done for the bilateral CSDHs. Only three patients (3%), single burr hole, and saline irrigation were employed. Three more patients had a craniotomy. Postoperative CT images were obtained within 3 days of the operation. Regular follow-up CT scans were taken immediately post-op, at 1 month, 6 months, and as and when required according to patient symptoms, and the status of the CSDH was monitored to determine whether it was resolved, resolving, or increasing.

Postoperative complications were either resolved or recurring. The CSDH that was resolved was either early resolution or delayed resolution.

Early resolution was defined as hematoma resolution within 30 days of surgery. Delayed resolution was defined as hematoma resolution occurring after 1 month.

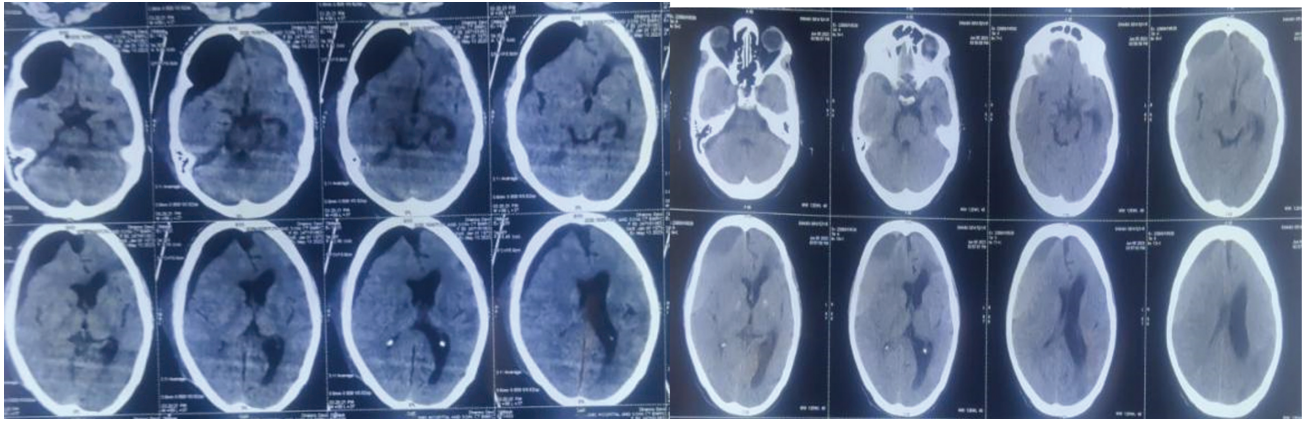


Fig. 1 Computed tomography scan showing recurrence after primary surgery.

Recurrent CSDH was defined as SDH appearance on CT after complete resolution or an increase in the size of SDH from previous scans (►Fig. 1).

Imaging after 1 month was only done if the patient's symptoms recurred.

The thickness of the CSDH was measured on a CT scan, which revealed the maximum thickness of the hematoma.²⁴ The degree of midline shift was measured near the level of the third ventricle or septum pellucidum on the CT scan.

Statistical significance was tested using the chi-squared test. It was considered significant when $p < 0.05$.

Results

The CSDH resolved within 30 days after surgery in 14% of patients, between 1 and 3 months in 58% of patients, and after 3 months in 28% of patients. The CSDH recurred in 14% of patients. Late resolution or recurrence was more common in the aged. This difference was statistically significant ($p = 0.11$; ►Table 2).

According to the laterality of the CSDH, a delayed resolution was more common in the left CSDHs. Late resolution was also more common in the bilateral CSDHs. The recurrence rate was 14.7% in the bilateral CSDH, while it was 13.7% on the left CSDH and 6.9% on the right CSDH (►Table 3).

The CSDH recurred in 14 patients. The recurrent hematoma was on the same side in 12 patients and on a different side in 2 patients. We performed a repeat surgery for the recur-

rent hematomas in four patients. In 10 patients, the recurrent hematomas were resolved spontaneously (►Table 4).

Recurrence was significantly more common in the cases where injury occurred less than 10 days prior (►Table 3).

The recurrence rate was relatively high on the left side (►Table 3).

Recurrence was significantly more common in hematomas of 10 to 20 mm. However, the recurrence rate was relatively high in the hematomas with a 5- to 10-mm midline shift (►Table 3).

The incidence of delayed resolution and recurrence was higher with increasing age and the data were statistically significant (►Chart 1).

The difference between males and females was statistically nonsignificant (►Chart 2).

Recurrence was significantly more common in injuries that occurred less than 10 days ago (►Chart 3).

Delayed resolution and recurrence were more common on left-sided SDHs but were not statistically significant (►Chart 4).

Delayed resolution and recurrence were significantly more common in hematoma size of 10 to 20 mm (►Chart 5).

Recurrence rates were significantly more common in hematoma with a midline shift of 5 to 10 mm (►Chart 6).

Eight membrane tissue samples from the recurrent cases were sent for biopsies, and neutrophil, lymphocyte, histiocyte, and plasma cell infiltration were observed, but no eosinophilic infiltration was noted in any case (►Fig. 2).

Table 2 Demographic features and postoperative courses of chronic subdural hematoma

Demographic features	Early resolution	Delayed resolution	Late resolution	Recurred	Statistics
Age					$p = 0.011$
Up to 49 y	7	10	9	2	Fisher's test
50–69 y	1	24	14	5	
Above 70 y	6	24	5	7	
Sex					$p = 0.063$
Male	14	41	22	12	Chi-squared test
Female	0	17	6	2	

Table 3 Radiologic features and postoperative courses of the chronic subdural hematoma

Radiologic features	Early resolution	Delayed resolution	Late resolution	Recurred	Statistics
No. of days of injury					p = 0.036
< 10	0 (0.0)	9 (50.0)	2 (11.1)	7 (38.9)	Chi-squared test
10–20	14 (20.0)	34 (48.6)	17 (24.3)	5 (7.1)	
> 20	0 (0.0)	15 (57.7)	9 (34.9)	2 (7.7)	
Laterality					p = 0.506
Right	14 (48.3)	13 (44.8)	0 (0.0)	2 (6.9)	Chi-squared test
Left	0 (0.0)	44 (86.3)	0 (0.0)	7 (13.7)	
Bilateral	0 (0.0)	1 (2.9)	28 (82.4)	5 (14.7)	
Thickness					p = 0.001
< 10 mm	14 (87.5)	0 (0.0)	0 (0.0)	2 (12.5)	Chi-squared test
10–20 mm	0 (0.0)	58 (89.2)	0 (0.0)	7 (15.2)	
> 20 mm	0 (0.0)	0 (0.0)	28 (84.8)	5 (15.2)	
Midline shift					p = 0.047
Up to 5 mm	14 (35.9)	18 (46.2)	3 (7.7)	4 (10.3)	Chi-squared test
5–10 mm	0 (0.0)	40 (66.7)	14 (23.3)	6 (10.0)	
> 10 mm	0 (0.0)	0 (0.0)	11 (73.3)	4 (26.7)	

Discussion

In the postoperative courses of CSDH, they either resolved or recurred. For the CSDH, an early or delayed remission was the most typical postoperative outcome. From a pathological perspective, CSDH is characterized by liquid hematomas that have accumulated within the subdural space, which is encircled by the outer and inner membranes.²⁴ If the CSDH does not go away a month after drainage, the lesion is a liquid hematoma covered with membranes. In pathologic terminology, hematoma is a CSDH even if it corresponds clinically to incomplete evacuation.

Under stringent conditions, it is especially difficult to deal with both incomplete removal and reaccumulation.²⁵

About 30% of the recurrent CSDHs returned within 30 days and more than half within 3 months.

The recurrent hematoma was on the same side in 12 patients and on the opposite side in 2 patients. The opposite side SDH is thought of as a previous negligible SDH that increased in size due to rebleeding after removal of primary SDH. Hence, it is considered a recurrence and not a primary event in our study. Recurrence is defined as the recurrence of symptoms after remission. The return of SDH in another site is

Table 4 Clinical features of the recurrent chronic subdural hematomas

Case no.	Age (y)	Sex	1st lesion	1st GCS	1st Tx	2nd lesion	2nd Tx	Duration	Previous resolution
1	66	F	B	15	2bh	Rt	cons	21	No
2	74	M	Lt	15	2bh	Rt	cons	64	Yes
3	80	M	Rt	12	2bh	Rt	cons	110	Yes
4	75	M	Lt	15	2bh	Lt	2bh	42	Yes
5	42	M	B	15	2bh	Lt	cons	26	No
6	88	M	Lt	10	2bh	Lt	2bh	148	Yes
7	64	M	B	15	2bh	Rt	cons	178	No
8	55	M	Lt	15	2bh	Lt	2bh	94	No
9	66	M	Lt	15	2bh	Lt	cons	17	No
10	51	F	B	15	2bh	Lt	cons	77	Yes
11	72	M	Lt	15	2bh	Lt	cons	196	Yes
12	75	M	Rt	12	2bh	Rt	cons	88	Yes
13	74	M	Lt	15	2bh	Rt	2bh	22	No
14	38	M	B	15	2bh	Rt	Cons	46	Yes

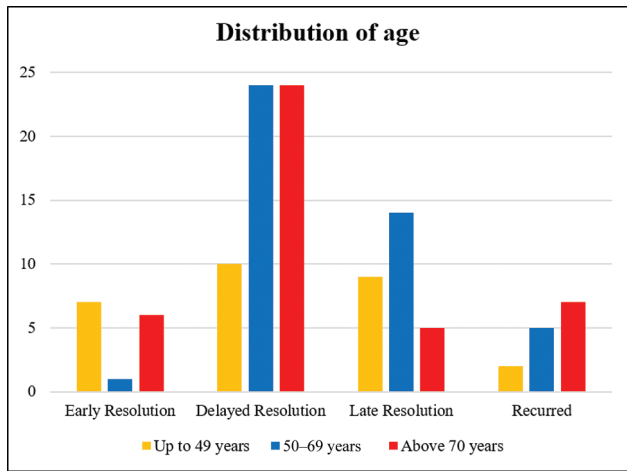


Chart 1 Resolution/recurrence and distribution according to age.

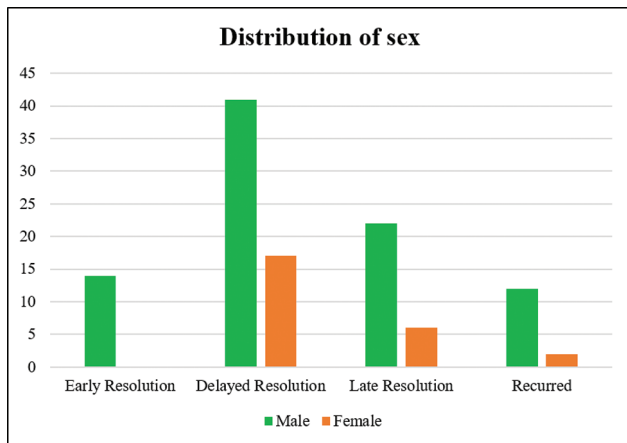


Chart 2 Resolution/recurrence and distribution according to gender.

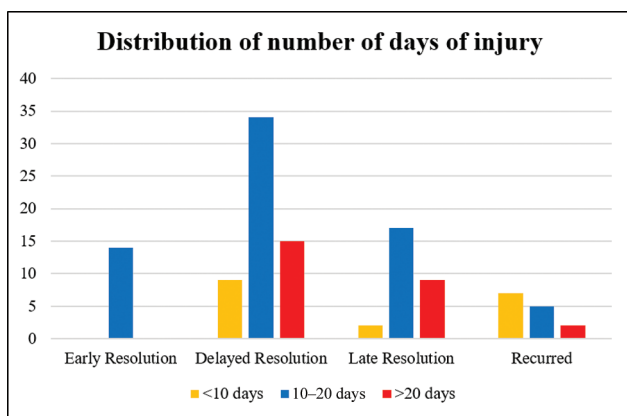


Chart 3 Resolution/recurrence and distribution according to the duration of injury.

also referred to as a recurrence, even though some people may insist on using the term “re-accumulation of the hematoma on the previously operated side.” To diagnose recurrence, Torihasi et al²⁶ required another operation after the initial surgery. On the other hand, hematomas that are not removed can undergo subsequent procedures. The development of the

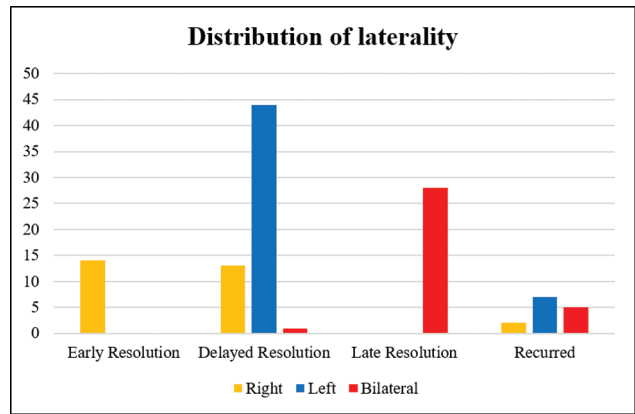


Chart 4 Resolution/recurrence and distribution according to laterality.

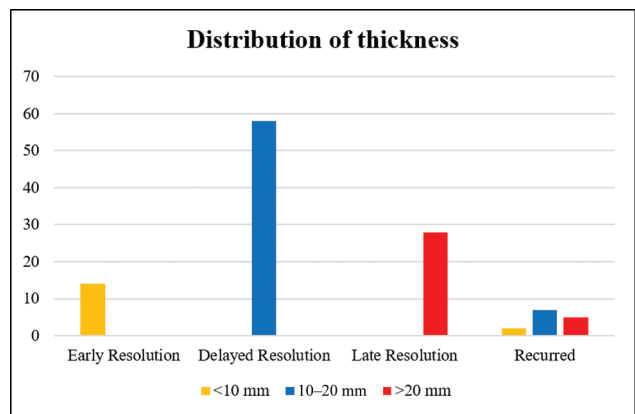


Chart 5 Resolution/recurrence and distribution according to thickness.

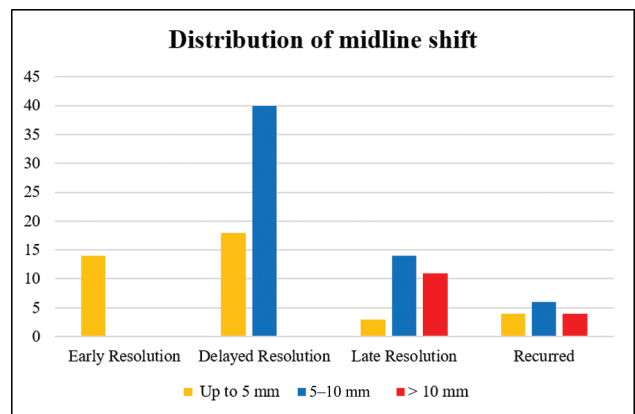


Chart 6 Resolution/recurrence and distribution according to midline shift.

neomembrane and stabilization of the neovasculature can lead to spontaneous resolution of CSDH.²⁷ Steroid therapy is a possible and safe option in the management of CSDH.²⁸ In such cases, another operation is not necessary. A minor subdural hygroma on both sides. Also, after the excision of a large unilateral CSDH with a noticeable midline shift, the development of a recurrent bilateral CSDH can be seen. Even if the hematoma is not surgically removed, the lesion is still

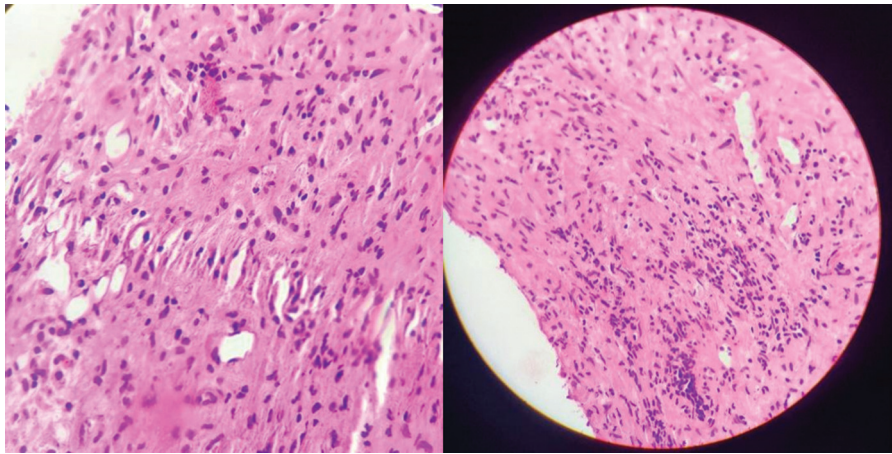


Fig. 2 Electron micrograph showing lymphocytes, plasma cells, histiocytes, and neutrophil infiltration in the subdural hematoma membrane.

CSDH pathologically, which would consist of liquid hematoma inside the inner and outer membranes. A second procedure is not essential to diagnose recurrent CSDHs.

In this study, the resolution CSDH was quicker among younger patients. After burr hole drainage, the amount of cerebral re-expansion determines whether the CSDH will resolve. The re-expansion rate was low in patients who were ≥ 50 years compared to that of patients who were younger than 50 years.²⁹ This is the reason why late resolution or recurrence was more common in patients aged ≥ 50 years. It was thought that the brain's re-expansion following surgery was influenced by variables other than age, a prior cerebral infarction, and air in the subdural region. Despite a publication suggesting that bilateral CSDHs constituted a separate risk factor for CSDH recurrence,²⁶ the recurrence rate of the bilateral CSDHs was not higher than the unilateral hematomas in this study. According to theory, patients with bilateral CSDH frequently have prior brain atrophy, which could hinder brain regrowth. However, the expansion of CSDH from a bilateral subdural hygroma is not always equal on both sides. This hemispheric pressure discrepancy may be caused by head tilting or a premorbid brain state. Bilateral lesions become unilateral lesions when the CSDH on one side is expanded, eradicating the opposite lesion.²⁷ At this time, the thickness of the hematoma becomes more important to the bilaterality itself. In this study, thick CSDHs had a very high recurrence rate. Some authors³⁰ reported that thickness as a risk factor for recurrence, while others²⁶ reported bilaterality as a risk factor for recurrence. Age, cerebral atrophy, large hematoma, bilateral hematomas, hematoma density, inflammatory indicators, alcohol use, bleeding propensity, and some technical aspects of surgery are among several risk factors for recurrence of CSDH that have been documented.^{8,18,31,32} Recently, an upright posture after surgery was reported as a risk factor for CSDH recurrence.³³ The majority of these risk factors are related to poor brain re-expansion. Eosinophils were found to be markers for initiating repair and local inflammation and were theorized to be present in the membrane of CSDH. We found an aggregation of neutrophils, plasma cells, lymphocytes, and histiocytes, but no eosinophils in the membrane evaluation. Although groups such as early, delayed, and late

based on time interval are arbitrary, we have to differentiate recurrence from incomplete removal at least clinically. It seems fair to use the term "early recurrence" when there is a return of symptoms or re-accumulation of the hematoma within 3 months following surgery, regardless of the second procedure, since 70% of the recurrences happened within that time frame. It is possible to classify persistent CSDHs more than 3 months following surgery as a late recurrence, independent of the site, volume, or number of surgeries.

Conclusion

The criteria for recurrence were an accumulation of CSDH after primary surgery and we have defined the time of resolution based on different durations of resolution after the primary surgery. In our study, recurrence was observed more commonly when the thickness of the SDH was greater than 10 mm and the midline shift was greater than 5 mm. The incidence of recurrence also increased with increasing age and there was no statistical association with the gender of the patient. Additionally, we observed no eosinophilic aggregation, but infiltration by lymphocytes, histiocytes, plasma cells, and neutrophils was noted in the membrane of recurrent CSDHs.

Authors' Contributions

S.N.V. collected the data and wrote the manuscript and A.S. did the proofreading and advised on corrections.

Funding

None.

Conflict of Interest

None declared.

References

- 1 Koliass AG, Chari A, Santarius T, Hutchinson PJ. Chronic subdural haematoma: modern management and emerging therapies. *Nat Rev Neurol* 2014;10(10):570–578
- 2 Asghar M, Adhiyaman V, Greenway MW, Bhowmick BK, Bates A. Chronic subdural haematoma in the elderly: a North Wales experience. *J R Soc Med* 2002;95(06):290–292

- 3 Cousseau DH, Echevarría Martín G, Gaspari M, Gonorazky SE. Chronic and subacute subdural haematoma. An epidemiological study in a captive population. *Rev Neurol* 2001;32(09):821–824
- 4 Kudo H, Kuwamura K, Izawa I, Sawa H, Tamaki N. Chronic subdural hematoma in elderly people: present status on Awaji Island and epidemiological prospect. *Neurol Med Chir (Tokyo)* 1992;32(04):207–209
- 5 Santarius T, Kirkpatrick PJ, Ganesan D, et al. Use of drains versus no drains after burr-hole evacuation of chronic subdural haematoma: a randomised controlled trial. *Lancet* 2009;374(9695):1067–1073
- 6 Ducruet AF, Grobelny BT, Zacharia BE, et al. The surgical management of chronic subdural hematoma. *Neurosurg Rev* 2012;35(02):155–169, discussion 169
- 7 Ridwan S, Bohrer AM, Grote A, Simon M. Surgical treatment of chronic subdural hematoma: predicting recurrence and cure. *World Neurosurg* 2019;128:e1010–e1023
- 8 Nakaguchi H, Tanishima T, Yoshimasu N. Factors in the natural history of chronic subdural hematomas that influence their postoperative recurrence. *J Neurosurg* 2001;95(02):256–262
- 9 Yamamoto H, Hirashima Y, Hamada H, Hayashi N, Origasa H, Endo S. Independent predictors of recurrence of chronic subdural hematoma: results of multivariate analysis performed using a logistic regression model. *J Neurosurg* 2003;98(06):1217–1221
- 10 Ramachandran R, Hegde T. Chronic subdural hematomas: causes of morbidity and mortality. *Surg Neurol* 2007;67(04):367–372, discussion 372–373
- 11 Stanišić M, Pripp AH. A reliable grading system for prediction of chronic subdural hematoma recurrence requiring reoperation after initial burr-hole surgery. *Neurosurgery* 2017;81(05):752–760
- 12 Nanko N, Tanikawa M, Mase M, et al. Involvement of hypoxia-inducible factor-1 α and vascular endothelial growth factor in the mechanism of development of chronic subdural hematoma. *Neurol Med Chir (Tokyo)* 2009;49(09):379–385
- 13 Hua C, Zhao G, Feng Y, Yuan H, Song H, Bie L. Role of matrix metalloproteinase-2, matrix metalloproteinase-9, and vascular endothelial growth factor in the development of chronic subdural hematoma. *J Neurotrauma* 2016;33(01):65–70
- 14 Hong HJ, Kim YJ, Yi HJ, Ko Y, Oh SJ, Kim JM. Role of angiogenic growth factors and inflammatory cytokine on recurrence of chronic subdural hematoma. *Surg Neurol* 2009;71(02):161–165, discussion 165–166
- 15 Frati A, Salvati M, Mainiero F, et al. Inflammation markers and risk factors for recurrence in 35 patients with a posttraumatic chronic subdural hematoma: a prospective study. *J Neurosurg* 2004;100(01):24–32
- 16 Markwalder TM. Chronic subdural hematomas: a review. *J Neurosurg* 1981;54(05):637–645
- 17 Edlmann E, Giorgi-Coll S, Whitfield PC, Carpenter KLH, Hutchinson PJ. Pathophysiology of chronic subdural haematoma: inflammation, angiogenesis and implications for pharmacotherapy. *J Neuroinflammation* 2017;14(01):108
- 18 Gelabert-González M, Iglesias-Pais M, García-Allut A, Martínez-Rumbo R. Chronic subdural haematoma: surgical treatment and outcome in 1000 cases. *Clin Neurol Neurosurg* 2005;107(03):223–229
- 19 Nomura S, Kashiwagi S, Fujisawa H, Ito H, Nakamura K. Characterization of local hyperfibrinolysis in chronic subdural hematomas by SDS-PAGE and immunoblot. *J Neurosurg* 1994;81(06):910–913
- 20 Sarkar C, Lakhtakia R, Gill SS, Sharma MC, Mahapatra AK, Mehta VS. Chronic subdural haematoma and the enigmatic eosinophil. *Acta Neurochir (Wien)* 2002;144(10):983–988, discussion 988
- 21 Osuka K, Watanabe Y, Usuda N, Aoyama M, Takeuchi M, Takayasu M. Eotaxin-3 activates the Smad pathway through the transforming growth factor beta 1 in chronic subdural hematoma outer membranes. *J Neurotrauma* 2014;31(16):1451–1456
- 22 Varricchi G, Galdiero MR, Loffredo S, et al. Eosinophils: the unsung heroes in cancer? *Oncol Immunology* 2017;7(02):e1393134
- 23 Rosenberg HF, Dyer KD, Foster PS. Eosinophils: changing perspectives in health and disease. *Nat Rev Immunol* 2013;13(01):9–22
- 24 Murakami H, Hirose Y, Sagoh M, et al. Why do chronic subdural hematomas continue to grow slowly and not coagulate? Role of thrombomodulin in the mechanism. *J Neurosurg* 2002;96(05):877–884
- 25 Rohde V, Graf G, Hassler W. Complications of burr-hole craniotomy and closed-system drainage for chronic subdural hematomas: a retrospective analysis of 376 patients. *Neurosurg Rev* 2002;25(1-2):89–94
- 26 Torihashi K, Sadamasa N, Yoshida K, Narumi O, Chin M, Yamagata S. Independent predictors for recurrence of chronic subdural hematoma: a review of 343 consecutive surgical cases. *Neurosurgery* 2008;63(06):1125–1129, discussion 1129
- 27 Lee KS. Natural history of chronic subdural haematoma. *Brain Inj* 2004;18(04):351–358
- 28 Delgado-López PD, Martín-Velasco V, Castilla-Díez JM, Rodríguez-Salazar A, Galacho-Harriero AM, Fernández-Arconada O. Dexamethasone treatment in chronic subdural haematoma. *Neurocirugía (Astur)* 2009;20(04):346–359
- 29 Mori K, Maeda M. Surgical treatment of chronic subdural hematoma in 500 consecutive cases: clinical characteristics, surgical outcome, complications, and recurrence rate. *Neurol Med Chir (Tokyo)* 2001;41(08):371–381
- 30 Matsumoto K, Akagi K, Abekura M, et al. Recurrence factors for chronic subdural hematomas after burr-hole craniotomy and closed system drainage. *Neurol Res* 1999;21(03):277–280
- 31 Amirjamshidi A, Abouzari M, Eftekhari B, et al. Outcomes and recurrence rates in chronic subdural haematoma. *Br J Neurosurg* 2007;21(03):272–275
- 32 Fogelholm R, Heiskanen O, Waltimo O. Chronic subdural hematoma in adults. Influence of patient's age on symptoms, signs, and thickness of hematoma. *J Neurosurg* 1975;42(01):43–46
- 33 Abouzari M, Rashidi A, Rezaei J, et al. The role of postoperative patient posture in the recurrence of traumatic chronic subdural hematoma after burr-hole surgery. *Neurosurgery* 2007;61(04):794–797, discussion 797