



# Incendiary Appearance of a Scalp Lesion: Whether Benign or Malignant?

Chinmay Shrikrishna Pendharkar<sup>1</sup>  Deepti Mutreja<sup>2</sup>  Rahul Vatsgotra<sup>3</sup> Shubhram Mishra<sup>4</sup>  
Arijit Sen<sup>5</sup>

<sup>1</sup> Department of Pathology, Armed Forces Medical College, Pune, Maharashtra, India

<sup>2</sup> Department of Pathology, Command Hospital (Air Force), Bangalore, Karnataka India

<sup>3</sup> Department of Pathology, INHS, Jeevanti, Goa, India

<sup>4</sup> Department of Pathology, Command Hospital (Northern Command), Assam, India

<sup>5</sup> Office of DGAFFMS, Command Hospital (Northern Command), Udhampur, Jammu & Kashmir, India

**Address for correspondence** Dr. (Maj) Chinmay Shrikrishna Pendharkar, MBBS, MD, DNB, Department of Pathology Armed Forces Medical College, Pune 411040, Maharashtra, India (e-mail: drchinmaypendharkar@gmail.com).

Ind J Med Paediatr Oncol 2025;46:93–95.

## Case Summary

A 46-year-old woman presented to the surgical outpatient department with a 10-year history of scalp swelling in the occipital region. The swelling was initially small in size, which gradually increased to attain the size of a pebble (► **Fig. 1**). There was no history of trauma preceding the onset of swelling. The patient did not complain of any pain, itching, or discoloration. On examination, the skin overlying the swelling was normal. The swelling was freely mobile in all directions and was not adherent to overlying skin or underlying structures. The consistency was soft to firm on palpation. The patient underwent surgical excision, and the specimen was sent for histopathological examination.

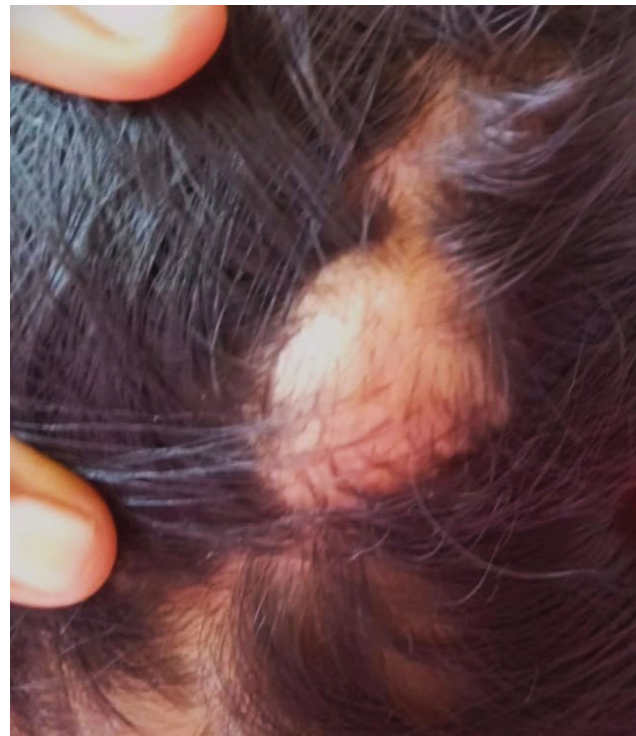## Differential Diagnosis

The differential diagnoses considered on clinical examination in this case were lipoma, epidermoid cyst, and sebaceous cyst.

## Histopathological Workup

### Gross Examination

A partially skin-covered globular tissue mass measuring  $2.0 \times 1.4 \times 0.8$  cm was observed. It had a well-demarcated solid cystic swelling with a glossy white cyst wall (► **Fig. 2**). The cut surface showed a firm whitish ovoid area measuring  $1 \times 0.6 \times 0.6$  cm with other cystic area filled with yellowish material (► **Fig. 3**).



**Fig. 1** Swelling in occipital region of the scalp. The overlying skin appears normal.

### Microscopy

The cyst wall was lined by a keratinized stratified squamous epithelium with the absence of a granular cell layer. Variable sized lobules of squamous epithelium were noted

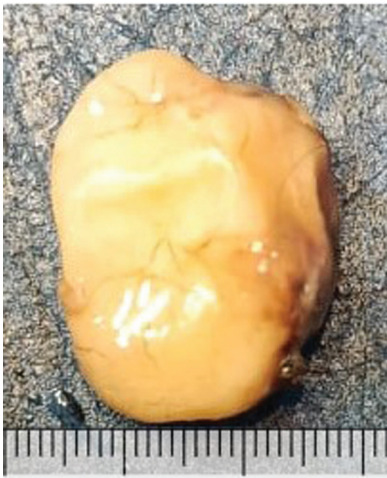article published online  
December 13, 2024

DOI <https://doi.org/10.1055/s-0044-1795093>.  
ISSN 0971-5851.

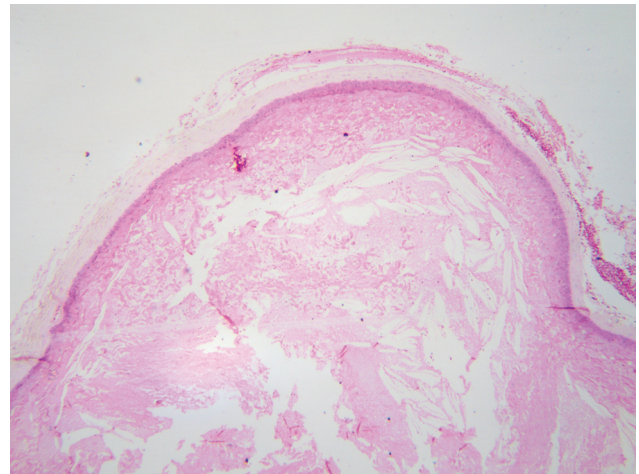
© 2024. The Author(s).

This is an open access article published by Thieme under the terms of the Creative Commons Attribution License, permitting unrestricted use, distribution, and reproduction so long as the original work is properly cited. (<https://creativecommons.org/licenses/by/4.0/>)

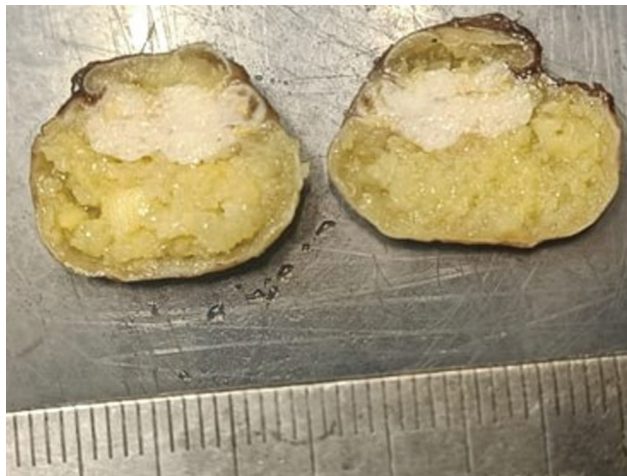Thieme Medical and Scientific Publishers Pvt. Ltd., A-12, 2nd Floor, Sector 2, Noida-201301 UP, India



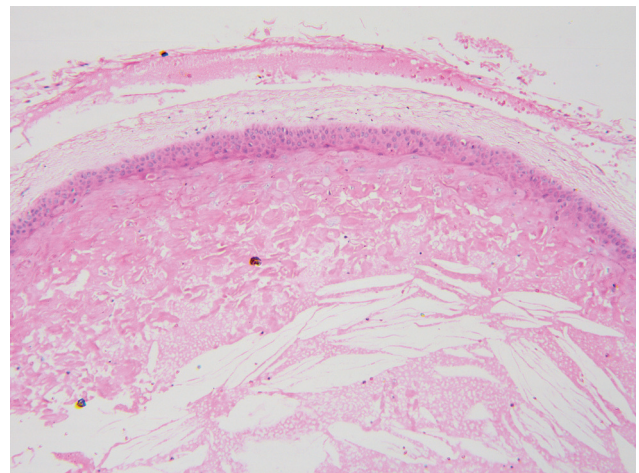
**Fig. 2** Excision biopsy of the scalp lesion. The outer surface is glossy white in appearance.



**Fig. 4** Cystic cavity lined by keratinized stratified squamous epithelium with the absence of the granular layer. Cholesterol clefts are also evident (hematoxylin and eosin,  $\times 40$ ).



**Fig. 3** The cut surface of the solid cystic lesion, which showed a firm whitish ovoid solid area with other cystic area filled with yellowish material.



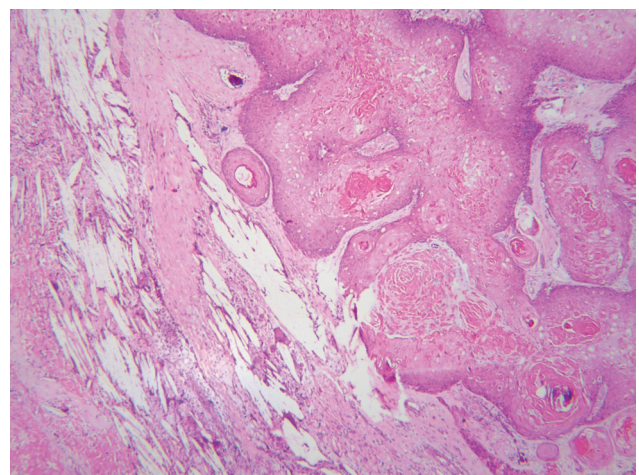
**Fig. 5** Similar findings as in Fig. 4 but at a higher magnification. The keratin-filled cavity is better appreciable at this magnification (hematoxylin and eosin,  $\times 100$ ).

undergoing abrupt change into eosinophilic amorphous keratin. The proliferating epithelium showed pushing borders. The cyst cavity contained abundant keratin, cholesterol clefts, and areas of calcification. No granuloma or giant cells were present. No dysplasia existed (**► Figs. 4–7**).

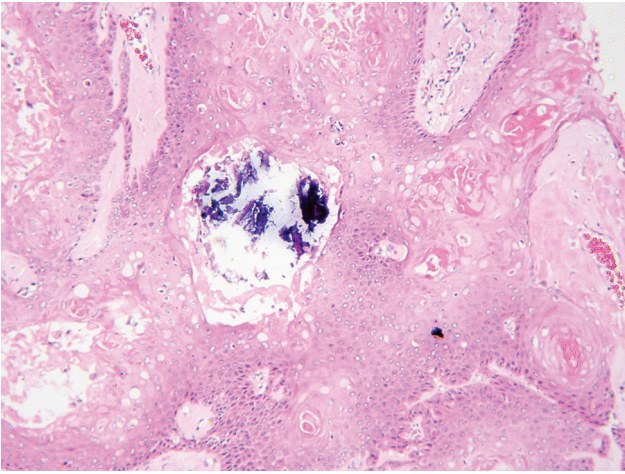
### Diagnosis and Discussion

The low-power histomorphology of the lesion may mimic the appearance of a squamous cell carcinoma. However, the important differentiating points that need to be considered here are pilar-type keratinization, absence of a granular layer, presence of a well-defined capsule, and the presence of the proliferating part only within the capsule, which support the diagnosis of a proliferating pilar tumor.

This tumor was first described by E.W. Jones who referred to it as a proliferating epidermoid cyst, which



**Fig. 6** Variable sized lobules of squamous epithelium undergoing abrupt change into eosinophilic amorphous keratin. The proliferating epithelium shows pushing borders. The lesion is considered a mimic of squamous cell carcinoma (hematoxylin and eosin,  $\times 40$ ).



**Fig. 7** Areas of calcification, which commonly occur in proliferating pilar tumors.

has also been called a proliferating pilar tumor.<sup>1</sup> Other terms that are used for the condition include proliferating trichilemmal cyst, proliferating trichilemmal tumor, and pilar tumor of the scalp.<sup>2</sup> Although this has been considered a benign mimic of squamous cell carcinoma, there are few reports describing the malignant behavior of these tumors.<sup>3,4</sup> Most cases are noted in women in the 43- to 66-year age range, with the most common location being the scalp.<sup>5</sup> The incendiary appearance of this lesion may create a diagnostic dilemma, but a thorough microscopic examination would lead to a definite diagnosis.

#### Patient Consent

The authors certify that they have obtained all appropriate patient consent forms. In the form, the patient has given her consent for her images and other clinical information to be reported in the journal. The patient understands that their names and initials will not be published and due efforts will be made to conceal their identity, but anonymity cannot be guaranteed.

#### Funding

None.

#### Conflict of Interest

None declared.

#### References

- 1 Jones EW. Proliferating epidermoid cysts. *Arch Dermatol* 1966;94(01):11–19
- 2 Ye J, Nappi O, Swanson PE, Patterson JW, Wick MR. Proliferating pilar tumors: a clinicopathologic study of 76 cases with a proposal for definition of benign and malignant variants. *Am J Clin Pathol* 2004;122(04):566–574
- 3 Osto M, Parry N, Rehman R, Ahmed U, Mehregan D. Malignant proliferating trichilemmal tumor of the scalp: a systematic review. *Am J Dermatopathol* 2021;43(12):851–866
- 4 Joshi TP, Marchand S, Tschén J. Malignant proliferating trichilemmal tumor: a subtle presentation in an African American woman and review of immunohistochemical markers for this rare condition. *Cureus* 2021;13(08):e17289
- 5 Alarcón Pérez CE, Gómez Ángulo D, Olmos Pérez M, Mora Hernández O, Morales SD. Management of 3 proliferating pilar tumors: definition, differential diagnosis, and treatment options. *Actas Dermosifiliogr (Engl Ed)* 2019;110(10):850–854