




Bone Mineral Density Distribution in the Posterior Wall of the Lateral Mass Evaluated by Computed Tomography Osteoabsorptiometry

Kazuma Doi¹  Nozomu Inoue² Satoshi Tani¹ Junichi Mizuno¹

¹Center for Minimally Invasive Spinal Surgery, Shin Yurigaoka General Hospital, Kawasaki, Kanagawa, Japan

²Department of Orthopedic Surgery, Rush University Medical Center, Chicago, Illinois, United States

Address for correspondence Kazuma Doi, MD, Center for Minimally Invasive Spinal Surgery, Shin Yurigaoka General Hospital, 255 Furusawatsuko, Asao, Kawasaki, Kanagawa 215-0026, Japan (e-mail: mogulaiko1987@yahoo.co.jp).

Asian J Neurosurg 2025;20:82–87.

Abstract

Objective Cervical open-door laminoplasty using plates and miniscrews is gaining popularity. One of the complications of this procedure is the loosening or back-out of the miniscrews inserted in the lateral mass (LM). Bone mineral density (BMD) measured by computed tomography (CT) has been used as a predictor of bone strength. However, bone density distribution in the LM remains unclear.

Materials and Methods We investigated bone density distribution in the posterior wall of the LM. A total of 120 LMs were analyzed from the patients who underwent laminoplasty. The distribution of BMD defined by Hounsfield unit (HU) in the posterior wall of the LM was measured by CT osteoabsorptiometry. The posterior wall was divided into nine zones, which consisted of three columns (lateral, center, and medial) and three rows (cranial, center, and caudal). BMD in each zone was averaged and compared by zones and cervical levels.

Results Overall mean \pm standard deviation BMD was $1,092 \pm 433$ HU. Averaged BMD in the entire posterior wall was highest at C4 ($1,365 \pm 459$ HU), second highest at C3 ($1,239 \pm 435$ HU), and lower in the lower levels. BMD in the medial–center zone ($1,357 \pm 443$ HU) was the highest in all zones. BMD in the medial–caudal region at C7 was only 59% of the highest BMD in the medial–center region at C4.

Conclusion The medial–center to the cranial region was most suitable for miniscrew fixation for laminoplasty. These biomechanical findings would be useful in the preoperative planning of laminoplasty especially for the determination of the LM screw entry points and in the design of laminoplasty implants.

Keywords

- ▶ bone mineral density
- ▶ lateral mass
- ▶ osteoabsorptiometry
- ▶ screw loosening

Introduction

Cervical laminoplasty using laminoplasty plates and miniscrews is gaining popularity in the surgical treatment of degenerative cervical diseases. However, loosening and

back-out of the miniscrews inserted into the LMs are sometimes encountered with this technique.¹ Bone mineral density (BMD) measured by quantitative computed tomography (CT) has been associated with mechanical properties, such as bone

article published online
November 19, 2024

DOI <https://doi.org/10.1055/s-0044-1793929>.
ISSN 2248-9614.

© 2024. Asian Congress of Neurological Surgeons. All rights reserved.

This is an open access article published by Thieme under the terms of the Creative Commons Attribution-NonDerivative-NonCommercial-License, permitting copying and reproduction so long as the original work is given appropriate credit. Contents may not be used for commercial purposes, or adapted, remixed, transformed or built upon. (<https://creativecommons.org/licenses/by-nc-nd/4.0/>)

Thieme Medical and Scientific Publishers Pvt. Ltd., A-12, 2nd Floor, Sector 2, Noida-201301 UP, India

strength, stiffness, and yield load.² CT osteoabsorptiometry (CT-OAM) has been used for the three-dimensional evaluation of BMD at arbitrary locations in the bones.^{3–6} A previous study on BMD distribution in the cervical spine demonstrated that the pedicles had the highest BMD, followed by the laminae and LMs, among cervical anatomical structures.² However, detailed bone density distribution within the posterior wall of the LM, which is used for miniscrew fixation in laminoplasty, remains unknown. Therefore, this study analyzed the bone density distribution in the posterior wall of the LM using CT-OAM. In addition, we aimed to determine whether significant differences in BMD existed among the C3–C7 LMs.

Materials and Methods

Selection of Patients and Model Creation

A total of 120 LMs from C3 to C7 were analyzed using preoperative CT images from 12 patients (2 females and 10 males; mean age, 60.5 years) who underwent open-door laminoplasty for degenerative diseases. A polygon model was created for each vertebra. The posterior walls of LMs and superior and inferior facet joint surfaces were then segmented from the vertebral polygon model. Centroids of the superior and inferior facet joint surfaces adjacent to the LM were calculated, as well as the axis connecting these centroids. A cylindrical coordinate system was established, with its longitudinal axis oriented along the axis connecting the facet centroids.⁶ The segmented polygon model of the posterior wall of the LM was converted into a point-cloud dataset. The coordinates of each point in the point cloud were converted from CT coordinates to cylindrical coordinates. CT-OAM analysis was performed at 0.3-mm intervals until 3.0-mm deep (defined by the radius of the cylindrical coordinate system) beneath the posterior wall of the LM. The highest Hounsfield unit (HU) recorded at each point was defined as BMD at that point. The posterior wall was divided into nine zones consisting of three columns (lateral, center, and medial) and three rows (cranial, center, and caudal) (► Fig. 1).

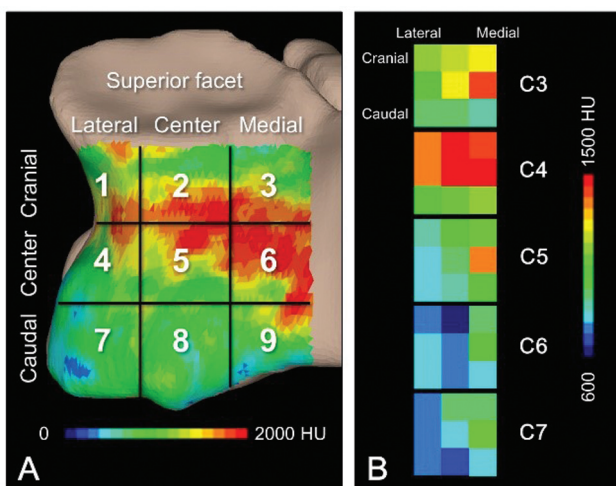


Fig. 1 (A) Representative (C4 left lateral mass) bone mineral density (BMD) distribution and zoning system. (B) Mean BMD levels and zones are presented by color codes. HU, Hounsfield unit.

Statistical Analysis

The mean BMD of each LM was compared between the right and left sides using a paired *t*-test. BMD was further compared by zone and spinal level using analysis of variance with Fisher's protected least significant difference post hoc *t*-test. A *p*-value < 0.05 was considered to indicate statistical significance for all tests performed. Results are presented as mean ± standard deviation (SD).

Results

The mean ± SD BMD at all levels and zones was $1,092 \pm 433$ HU. A significant difference was observed between the right and left sides ($p = 0.0117$); therefore, all LMs were included in the subsequent analyses. The mean BMD was highest in the entire posterior wall at C4 ($p = 0.0009$ vs. C3; $p < 0.0001$ vs. C5–C7), second highest at C3 ($p < 0.0001$ vs. C5–C7), and lowest at C6 ($p < 0.0001$ vs. C3–C5) and C7 ($p < 0.0001$ vs. C3–C5; $p = 0.0035$ vs. C5) (► Fig. 2, ► Table 1). BMD in the medial-center zone (zone 6, $1,357 \pm 443$ HU) was the highest among all zones ($p = 0.0149$ vs. zone 3; $p < 0.0001$ vs. zones 1, 2, 4, 5, 7–9), followed by that in the medial-cranial zone (zone 3, $1,226 \pm 408$ HU), which was higher than those in zone 1 ($p = 0.0047$), zone 4 ($p < 0.0001$), zone 5 ($p = 0.237$), and zones 7–9 ($p < 0.0001$) (► Fig. 3, ► Table 1). However, BMD in the medial-caudal zone (zone 9, $1,067 \pm 379$ HU) was lower than those in other medial zones ($p = 0.0039$ vs. zone 3; $p < 0.0001$ vs. zone 6) (► Fig. 3, ► Table 1). When split by cervical levels, BMD in the medial-caudal zone (zone 9) was lower than that in the medial-center zone (zone 6) at C3 ($p < 0.0001$), C4 ($p = 0.0053$), and C5 ($p = 0.0091$) (► Table 1).

Discussion

The present study demonstrated cervical level-dependent variations in BMD in the posterior wall of the LM, showing the highest BMD at C4, second highest at C3, and lower BMD decreased with descending cervical level. A previous study that measured BMD of the cervical spine reported higher overall BMD at C4–C5 than those at C3, C6, and C7.² This study further speculated that higher BMD at C4–C5 may be caused by the greater load in the middle cervical spine due to natural lordosis.² Higher segmental motion in the middle cervical spine may also increase BMD at C4–C5.⁷

The present study also demonstrated considerable variation in BMD within each posterior wall, with the highest BMD in the medial-center zone and higher BMD in the medial-cranial zones. In contrast, the present study showed that BMD in the medial-caudal zone was lower than those in other cranial zones in the medial LM, especially in the lower cervical levels. These findings indicate the medial-center and medial-cranial zones are suitable for miniscrew fixation in cervical laminoplasty, given the suitable BMD distribution in the posterior wall of the LM.

A previous study investigating BMD in distinct anatomical regions in C3–C7 showed that the pedicles had the highest

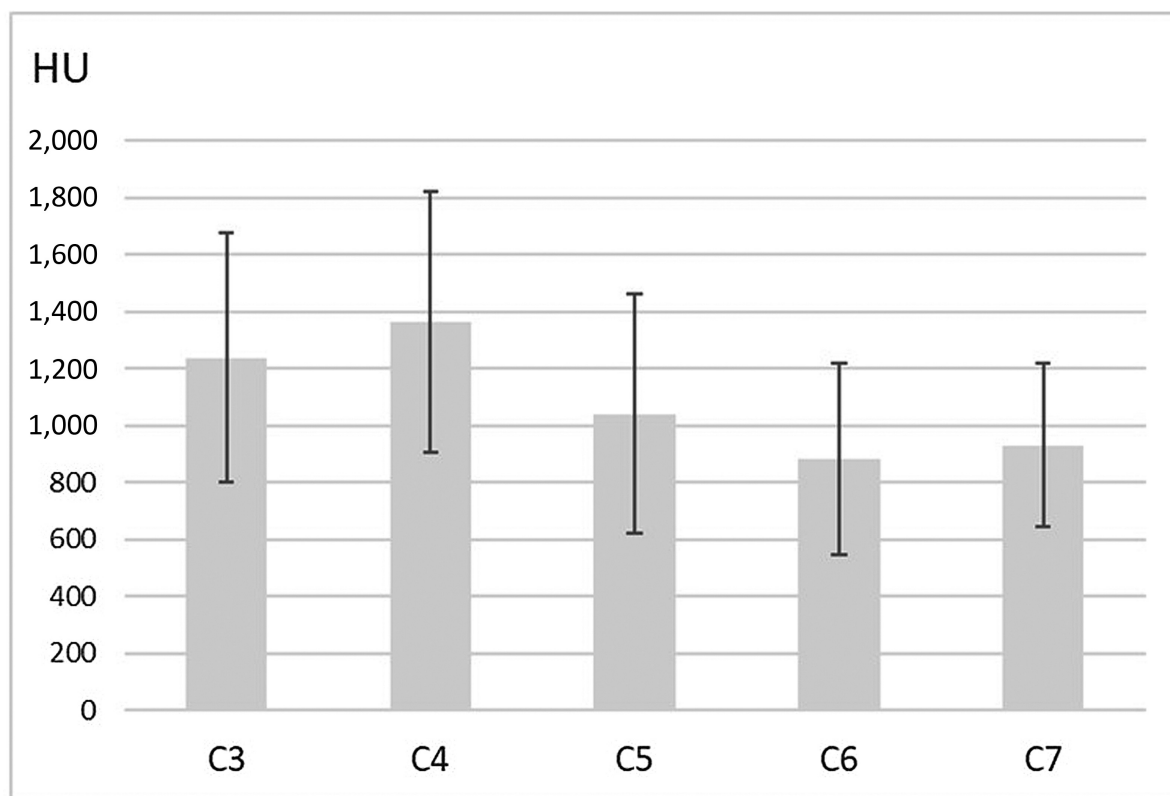


Fig. 2 Average bone mineral density through the posterior wall of the lateral mass at the cervical level. Level effects: C4 was the highest, and C3 was the second highest. Overall density was lower in lower levels. Bone density decreases in lower levels. Error bar: standard deviation. HU, Hounsfield unit.

BMD, followed by laminae and LMs among cervical anatomical structures.² In the present study, overall BMD in the posterior wall at C4–C5 LMs was more than 1,000 HU, indicating that these LMs were as strong as the medial cortical bone of the pedicle.⁸

Correlation between BMD and mechanical properties of the cervical endplate has been repeatedly demonstrated.^{5,9–11} These studies showed that BMD can be used as a predictor of the mechanical properties of the bony parts of the spine. Screw insertion torque and BMD were highly correlated in lumbar pedicle screw fixation.^{12,13} The screw insertion torque was also studied in cervical LM screw fixation, showing the highest insertion torque at C4 and gradually decreased with descending cervical level.¹⁴ The cervical level-dependent BMD reported in the present study supports these clinical outcomes.

A cadaveric study showed that the pull-out resistance of the LM screws was significantly different by level.¹⁵ Similar to the clinical results on the screw insertion torque,¹⁴ a cadaveric study showed that the pull-out strength was greatest at C4, decreasing cephalic and caudal to C4.¹⁵ Another biomechanical cadaveric study analyzed the contribution of BMD to insertion torque and pull-out strength using the method of placing the revision screws after removing the instrumented LM screws.¹⁶ In this study, the original LM screws were inserted by a Magerl trajectory, and the revision LM screws were placed using a Roy-

Camille trajectory, a larger diameter Magerl trajectory, or pedicle screws.¹⁶ The authors of the study reported that pull-out strength and insertion torque increased with increased BMD, and these parameters were significantly correlated in each group.¹⁶ These clinical and cadaveric biomechanical studies indicate a significant association between BMD and pull-out strength or insertion torque.

Few studies have documented screw back-out as complication related to the use of laminoplasty plates and miniscrews. A study showed that screw back-out occurred in 5.2% of instrumented screws within 3 months postoperatively in 68.2% of cases,¹ indicating the importance of initial screw fixation strength.¹ In this study, the miniscrews that caused back-out were located either at the most cranial or caudal operative levels in 79.4% of cases.¹ Another study reported a 4.9% incidence of loosening following cervical LM miniscrew fixation.¹⁴ This study also found that none of the screws was located in the intermediate cervical levels.¹⁴ Although segmental motion is higher in the middle cervical spine, the higher BMD in the posterior wall of the LM in the middle levels may contribute to preventing miniscrew loosening and back-out.

The present study describes the detailed distribution of BMD in the posterior wall of the LM obtained by CT-OAM. To the best of our knowledge, this is the first study to investigate BMD distribution in the LM and the difference in level effects.

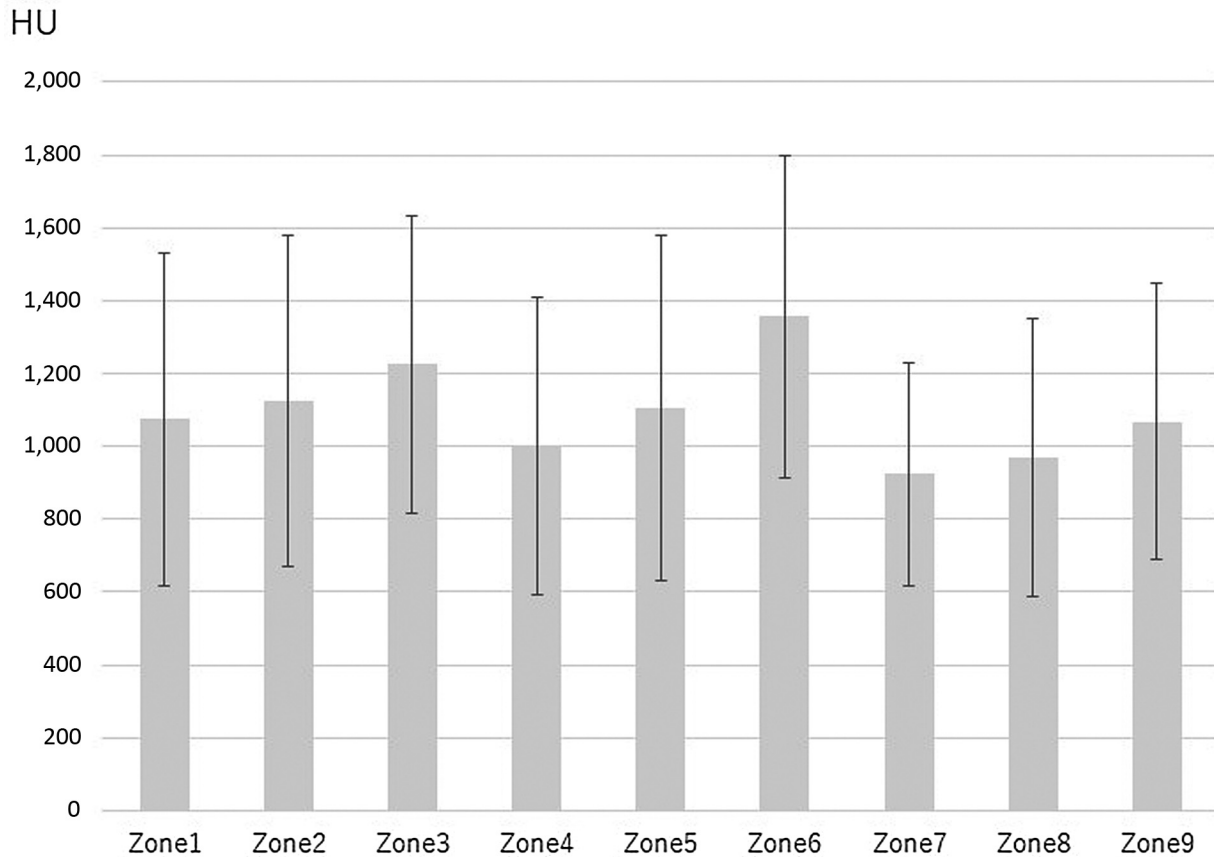


Fig. 3 Regional variations in bone mineral density; zone 6 was the highest. Zone 3 was the second highest. Error bar: standard deviation. HU, Hounsfield unit.

CT-OAM was developed to measure BMD on a curved bony surface and underneath the surface and applied to the evaluation of BMD in the endplates and facet joints in the spinal field.^{3-5,9-11} This technique allows the measurement of BMD distribution on and underneath the surface of the LM, which has cylindrical geometry. In the present study, BMD was measured using a cylindrical coordinate system so that BMD in the cortical shell of the LM and the concentric layers underneath the cortical shell at different depths could be evaluated.

In the present study, the regional analysis of BMD in the posterior wall revealed higher BMD in the medial one-third of the posterior area. The medial region is typically used for miniscrew fixation for the laminoplasty plates. However, BMD in the medial-caudal region is not as high as compared with those in medial-cranial and medial-center regions. Therefore, the most suitable insertion points for miniscrew fixation for laminoplasty would be the medial-cranial and medial-center regions in the posterior wall of the LM. Considering the level variation altogether, BMD in the medial-caudal region in C7 was only 59% of the highest BMD in the medial-center region at C4. These biomechanical findings would be useful in the preoperative planning of laminoplasty especially for determination of the LM screw entry points and in the design of laminoplasty implants.

The present study only evaluated BMD in the posterior wall of the LM under the assumption that the cortical shell

most contributes to the fixation strength of the miniscrew. However, if the miniscrew tips reach the subchondral bone area of the opposing facet joint, high BMD in the subchondral bone of the facet joint may also contribute to the fixation strength of the miniscrew, especially in the caudal region of the posterior wall.⁴ Since penetration of the miniscrew into the facet joint may cause screw loosening due to micromotion, further causing facet joint arthrosis,¹⁷ appropriate selection of miniscrew length and insertion angle is additional important factors for stable miniscrew fixation. In addition to measuring BMD on the anatomical bony surfaces, CT-OAM enables the measurement of BMD on the surface of the implants placed in the bones, either in real or virtually.^{18,19} Future studies using CT-OAM should be conducted on investigating the measurement of BMD on the surfaces and adjacent areas of the miniscrew virtually placed in the LM so that BMD around the entire thread of the miniscrew can be used to seek the best insertion location and orientation of miniscrew fixation for cervical laminoplasty.

In the present study, we measured bone density within 3.0-mm depth from the surface of the lateral mass (LM) including the cortical portion of the LM which appears to contribute to the strength of miniscrew fixation. Future studies will also measure bone density distribution within the cancellous bone portion of the LM to be used for preoperative planning of longer screw fixation in the LM.

Table 1 Mean bone mineral density by level and zone

| | Zone 1 | Zone 2 | Zone 3 | Zone 4 | Zone 5 | Zone 6 | Zone 7 | Zone 8 | Zone 9 | Total |
|-------|-------------|-------------|-------------|-------------|-------------|-------------|-------------|-------------|-------------|-------------|
| C3 | 1,292 (490) | 1,345 (479) | 1,343 (363) | 1,205 (464) | 1,400 (466) | 1,514 (399) | 995 (263) | 1,016 (316) | 1,043 (346) | 1,239 (435) |
| C4 | 1,414 (501) | 1,483 (358) | 1,467 (391) | 1,160 (464) | 1,450 (493) | 1,649 (437) | 1,130 (378) | 1,240 (465) | 1,293 (431) | 1,365 (459) |
| C5 | 978 (368) | 1,064 (402) | 1,254 (499) | 891 (376) | 954 (381) | 1,391 (458) | 860 (259) | 897 (341) | 1,118 (394) | 1,042 (420) |
| C6 | 805 (267) | 773 (340) | 1,068 (335) | 822 (311) | 794 (340) | 1,092 (372) | 819 (243) | 841 (368) | 922 (307) | 881 (336) |
| C7 | 881 (300) | 962 (299) | 998 (251) | 803 (213) | 925 (263) | 1,137 (282) | 804 (253) | 853 (273) | 981 (317) | 931 (288) |
| Total | 1,074 (457) | 1,125 (455) | 1,226 (408) | 1,000 (410) | 1,104 (474) | 1,357 (443) | 924 (306) | 969 (383) | 1,067 (379) | 1,092 (433) |

Note: Unit used—Hounsfield unit, mean (standard deviation).

Conclusion

BMD distribution in the posterior wall of the LM measured on clinical CT revealed higher BMD at the C4–C5 levels and medial–center and medial–cranial regions. These results indicate that the medial center to the cranial regions is suitable for miniscrew fixation for cervical laminoplasty in terms of bone density. However, BMD in the medial–caudal region had lower BMD than the cranial regions in the medial LM. Furthermore, lower BMD in the lower levels, the BMD in the medial–caudal region in C7, was only 59% of the highest BMD, which was found in the medial–center region at C4. These biomechanical findings would be useful in the preoperative planning of laminoplasty especially for determination of the LM screw entry points and in the design of laminoplasty implants.

Ethical Approval

The Institutional Review Board of Shin Yurigaoka General Hospital approved this study (no. 20230227-2).

Funding

None.

Conflict of Interest

None declared.

References

- Liu G, Buchowski JM, Riew KD. Screw back-out following “open-door” cervical laminoplasty: a review of 165 plates. *Asian Spine J* 2015;9(06):849–854
- Anderst WJ, Thorhauer ED, Lee JY, Donaldson WF, Kang JD. Cervical spine bone mineral density as a function of vertebral level and anatomic location. *Spine J* 2011;11(07):659–667
- Müller-Gerbl M, Putz R, Hodapp N, Schulte E, Wimmer B. Computed tomography-osteodensitometry for assessing the density distribution of subchondral bone as a measure of long-term mechanical adaptation in individual joints. *Skeletal Radiol* 1989; 18(07):507–512
- Pan CC, Simon P, Espinoza Orías AA, et al. Lumbar facet joint subchondral bone density in low back pain and asymptomatic subjects. *Skeletal Radiol* 2020;49(04):571–576
- Hara T, Ohara Y, Abe E, et al. Cervical endplate bone density distribution measured by CT osteodensitometry and direct comparison with mechanical properties of the endplate. *Eur Spine J* 2021;30(09):2557–2564
- Irie TY, Irie T, Espinoza Orías AA, et al. Three-dimensional distribution of CT attenuation in the lumbar spine pedicle wall. *Sci Rep* 2021;11(01):1709
- Morishita Y, Hida S, Miyazaki M, et al. The effects of the degenerative changes in the functional spinal unit on the kinematics of the cervical spine. *Spine* 2008;33(06):E178–E182
- Kim MK, Cho HJ, Kwak DS, You SH. Characteristics of regional bone quality in cervical vertebrae considering BMD: determining a safe trajectory for cervical pedicle screw fixation. *J Orthop Res* 2018; 36(01):217–223
- Briski DC, Goel VK, Waddell BS, et al. Does spanning a lateral lumbar interbody cage across the vertebral ring apophysis increase loads required for failure and mitigate endplate violation. *Spine* 2017;42(20):E1158–E1164
- Segami K, Espinoza Orías AA, Miyamoto H, Kanzaki K, An HS, Inoue N. Regional distribution of computed tomography attenuation across the lumbar endplate. *PLoS One* 2021;16(10):e0259001

- 11 Zavras AG, Dandu N, Espinoza-Orias AA, et al. Computed tomography osteoabsorptiometry evaluation of cervical endplate subchondral bone mineral density. *Global Spine J* 2023;13(07):1803–1811
- 12 Okuyama K, Abe E, Suzuki T, Tamura Y, Chiba M, Sato K. Can insertional torque predict screw loosening and related failures? An in vivo study of pedicle screw fixation augmenting posterior lumbar interbody fusion. *Spine* 2000;25(07):858–864
- 13 Kuklo TR, Lehman RA Jr. Effect of various tapping diameters on insertion of thoracic pedicle screws: a biomechanical analysis. *Spine* 2003;28(18):2066–2071
- 14 Kanematsu R, Hanakita J, Takahashi T, Minami M, Inoue T, Honda F. Risk factor analysis of facet fusion following cervical lateral mass screw fixation with a minimum 1-year follow-up: assessment of maximal insertional screw torque and incidence of loosening. *Neurol Med Chir (Tokyo)* 2021;61(01):40–46
- 15 Heller JG, Estes BT, Zaouali M, Diop A. Biomechanical study of screws in the lateral masses: variables affecting pull-out resistance. *J Bone Joint Surg Am* 1996;78(09):1315–1321
- 16 Hostin RA, Wu C, Perra JH, Polly DW, Akesen B, Wroblewski JM. A biomechanical evaluation of three revision screw strategies for failed lateral mass fixation. *Spine* 2008;33(22):2415–2421
- 17 Heller JG, Silcox DH III, Sutterlin CE III. Complications of posterior cervical plating. *Spine* 1995;20(22):2442–2448
- 18 Chahla J, Liu JN, Manderle B, et al. Bony ingrowth of coil-type open-architecture anchors compared with screw-type PEEK anchors for the medial row in rotator cuff repair: a randomized controlled trial. *Arthroscopy* 2020;36(04):952–961
- 19 Orías AAE, Sheha E, Zavras A, et al. CT osteoabsorptiometry assessment of subchondral bone density predicts intervertebral implant subsidence in a human ACDF cadaver model. *Global Spine J* 2023;13(05):1374–1383