



# Clinical Outcome and Surgical Outcome of Moyamoya Disease after Combined Revascularization Performed at the Neurological Institute of Thailand

Sarunya Yuthagovit<sup>1</sup> Punjama Lertbutsayanuku<sup>2</sup> Wuttipong Tirakotai<sup>1</sup>

<sup>1</sup>Department of Neurosurgery, Neurological Institute of Thailand, Bangkok, Thailand

<sup>2</sup>Department of Neuroradiology, Neurological Institute of Thailand, Bangkok, Thailand

Address for correspondence Wuttipong Tirakotai, MD, MSc, Dr.Med, Neurological Institute of Thailand, Rajchavithi Road, Ratchathewee, Bangkok 10400, Thailand (e-mail: tirakotai.w@nit.go.th).

Asian J Neurosurg 2025;20:75–81.

## Abstract

**Objective** Moyamoya disease is a chronic, progressive, intracranial steno-occlusive disease. Cerebral revascularization has proved that it is more beneficial than medical therapy for prevention of recurrent stroke. We aimed to report clinical and surgical outcome of moyamoya disease after combined revascularization in Thai population.

**Materials and Methods** From October 2015 to March 2023, patients diagnosed with moyamoya disease and were operated with combined revascularization were included. Patients were evaluated for hemodynamic state with preoperative and postoperative blood oxygenation level-dependent magnetic resonance (BOLD MR) imaging. Demographic data, serial imaging, surgical outcome, and clinical outcome were analyzed. Morbidity and mortality rates of surgery were reported. For clinical outcome evaluation, modified Rankin Scale (mRS) scores were compared between preoperative and postoperative outcome. The mRS score of 0 to 2 signify good outcome after surgery.

**Results** There were a total of 55 patients. Ischemic stroke was the most common presentation (87.3%). Based on the Suzuki's classification, most of the patients were stage 3 and 4. Clinical outcome measured with mRS score had good outcome, 100% (mRS score 0–2). For surgical outcome, overall graft patency was 94.8%, overall complication rate was 6.5%, and mortality rate was zero. Mean follow-up duration was  $44.5 \pm 25.1$  months. Recurrent stroke occurred in 1.3%, which was recurrent ischemic stroke.

**Conclusion** Combined revascularization in moyamoya disease in the Thai population has a good clinical outcome, an acceptable risk of complication, and a reduced recurrent rate of stroke. Clinical and surgical outcome should be studied in the long term with the use of BOLD MR with carbon dioxide stimuli for the evaluation of cerebral blood flow in the patient.

## Keywords

- ▶ BOLD MR
- ▶ clinical outcome
- ▶ combined revascularization
- ▶ moyamoya disease
- ▶ surgical outcome
- ▶ Thai population

article published online  
November 28, 2024

DOI <https://doi.org/10.1055/s-0044-1792159>.  
ISSN 2248-9614.

© 2024. Asian Congress of Neurological Surgeons. All rights reserved.

This is an open access article published by Thieme under the terms of the Creative Commons Attribution-NonDerivative-NonCommercial-License, permitting copying and reproduction so long as the original work is given appropriate credit. Contents may not be used for commercial purposes, or adapted, remixed, transformed or built upon. (<https://creativecommons.org/licenses/by-nc-nd/4.0/>)

Thieme Medical and Scientific Publishers Pvt. Ltd., A-12, 2nd Floor, Sector 2, Noida-201301 UP, India

## Introduction

Moyamoya disease (MMD) is characterized by idiopathic, chronic, progressive steno-occlusion of the internal carotid artery at the level of its terminal bifurcation and an abnormal vascular network at the base of the brain.<sup>1</sup> The condition tends to occur bilaterally, and although it is an uncommon illness, it is known to be an etiologic factor for stroke. Demographic studies indicate that the Asian population has a higher prevalence of this illness than American and European population.<sup>2</sup> The pathophysiology of MMD is progressive stenoses of large vessel and increased amounts and diameters of microvascular at basal and cortical vessels that represent to compensatory mechanisms for reduced cerebral blood flow (CBF) and neovascularization. The patients have symptoms and impaired cerebrovascular hemodynamic state, which indicates cerebral revascularization.

According to research,<sup>3-5</sup> surgical revascularization is more beneficial than medical therapy in the management of MMD, as it reduces the risk of ischemic and hemorrhagic stroke recurrence because cerebral revascularization can restore blood flow to the brain for stabilized cerebrovascular hemodynamic and decrease amount of fragile Moyamoya vessels. There are three types of surgical revascularization: direct, indirect, and combined. Direct bypass offers more advantages than indirect revascularization, but it produces results that are similar to those of combined revascularization.<sup>2,3,6-13</sup> Few reports are available on the effectiveness of MMD treatment in Thailand and the present study aims to determine the clinical and surgical results of combined revascularization for MMD in the Thai population.

## Materials and Methods

### Study Population

The study was a retrospective study of data on 55 patients managed for MMD by combined revascularization in 77 hemispheres, performed by a single surgeon (S.Y.) between October 2015 and June 2022. The study population included 9 pediatric patients (age < 18 years) and 46 adult patients (age > 18 years).

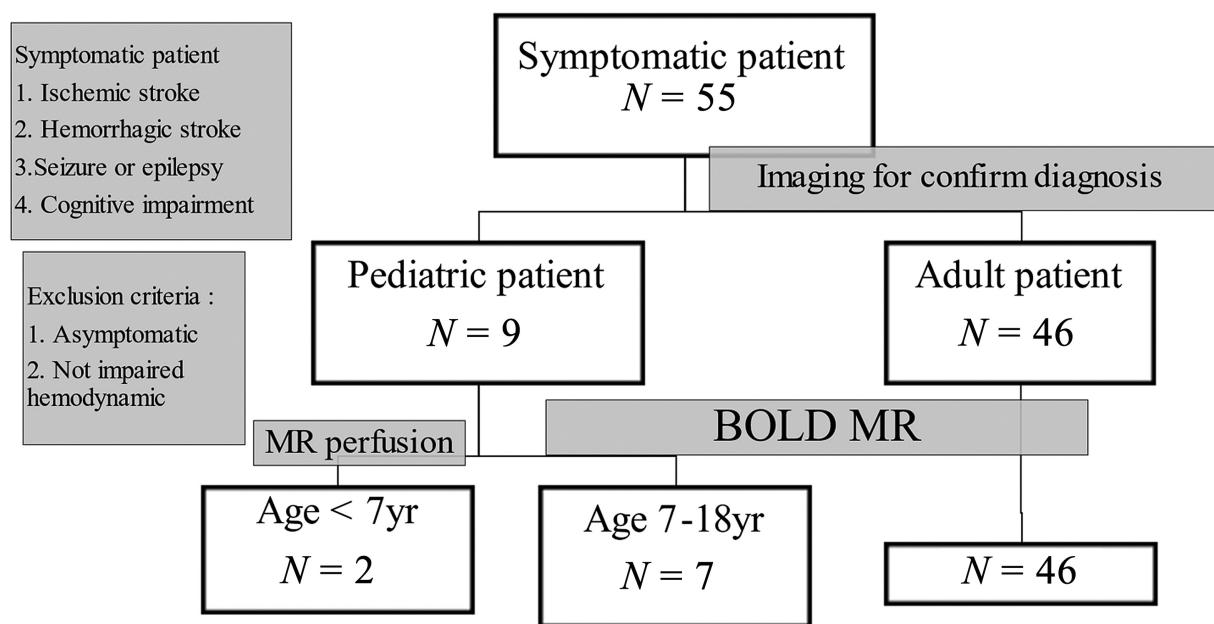
The diagnostic criteria for MMD were based on guidelines reported in 1995 by Fukui<sup>14</sup>:

- (1) stenosis or occlusion of the internal carotid arteries and the proximal middle and anterior cerebral arteries; and
- (2) unilateral or bilateral involvement.

Medical data was gathered for the assessment of clinical presentation and surgical information, including complications and clinical outcome, up until the most recent follow-up (end of March 2023). Three factors served as the basis for the inclusion criteria for surgical therapy, as follows

(► Fig. 1):

- (1) The patient had signs of ischemia (infarction or transient ischemic attack), hemorrhage, seizure, headache, or cognitive impairment (symptomatic patient).
- (2) A cerebral angiography, or magnetic resonance angiography (MRA), of the brain verified the diagnosis.
- (3) Blood oxygenation level-dependent (BOLD) magnetic resonance imaging (MRI) with carbon dioxide stimuli was used as a hemodynamic investigation to determine the condition of the cerebrovascular reactivity



**Fig. 1** Flow chart demonstrates number of population in each group of patients that may use the different techniques of MRI.

(CVR), which refers to the change in CBF in response to vasoactive stimuli. In patients with decreased CBF, the BOLD MR of the patient demonstrates decreased CVR. For the follow-up during the postoperative period, clinical visits were scheduled every 1, 3, 6, and 12 months following surgery. Patients were followed up with MRA and BOLD MR for 3 to 6 months and then annually. Follow-up following revascularization on both sides was done using cerebral angiography.

### Surgical Technique

The surgical revascularization consisted of direct revascularization (superficial temporal artery to middle cerebral artery [STA-MCA] bypass) and indirect revascularization (encephalo-duro-arterio-synangiosis [EDAS] or encephalo-duro-arterio-myo-synangiosis [EDAMS]). Between 2015 and 2019, EDAS was performed, and from 2020 to the present, EDAMS was performed. An incision was made over the STA. Either the frontal branch or the parietal branch was selected, depending on whether it was larger than the other by imaging. The STA was harvested under a microscope. The dissection of the temporalis muscle was tailored to decrease the CVR area. A craniotomy was performed over the Sylvian fissure. Dura was open in a C-shaped fashion that corresponded to the direction of the temporalis muscle. After bypass, the dura was inverted into the subdural space. For the anastomosis, an appropriate M4 was selected and prepared for the recipient artery. A triangular-shaped piece of a blue surgical glove was placed as a background. A temporary clip was applied to the proximal and distal parts of the M4 branch. The distal and proximal parts of the M4 were occluded with a temporary clip, and the arteriotomy of the STA was done in a fish-mouth pattern. With a marking pen, the donor and recipient vessels were made more visible. A tear drop pattern of the arteriotomy was made on the side of the M4 branch, and an anastomosis was made using a round, noncutting 10–0 nylon suture under a high-power microscope. About 14 to 18 interrupted stitches were applied to each anastomosis. The temporary clips were removed. Intraoperative Doppler and indocyanine green video angiography were employed to access the patency of bypass. Perioperative complications occurring within 14 days after surgery included a new stroke and cerebral hyperperfusion syndrome (CHS) defined as new focal neurological deficit or new symptom in concordance with imaging in this period.

### BOLD MR Protocol

The MRI, MRA of the brain, and CVR maps of the patients were obtained on a 3-T MRI scanner (MAGNETOM Skyra TIM; Siemens Medical Solution). A 20-channel head coil was used. The anatomic imaging included fast spin echo T2-weighted, fluid-attenuated inversion recovery, diffusion-weighted, susceptibility-weighted, and high-resolution three-dimensional magnetization-prepared rapid acquisition with gradient echo. An 11.49-minute paradigm was the cyclic pattern of alternating control and active conditions. Normocapnia was considered the control condition, and hypercapnia was considered the active condition. With the

patient wearing a face mask connected to the brain circuit. 15 L/min of oxygen (O<sub>2</sub>) and 15 L/min of carbogen (5% CO<sub>2</sub> + 95% O<sub>2</sub>) were administered during normocapnia and hypercapnia, respectively. The end-tidal (ET) was monitored via a sampling line at the nostril, aiming for an increase in ET-CO<sub>2</sub> to approximately 20% of the patient's baseline. This procedure was controlled by an anesthesiologist. Continuous monitoring of the patient's vital signs, including blood pressure, pulse, and oxygen saturation, was performed. The findings demonstrated CVR in normocapnia as compared with hypercapnia states. When CVR was increased, imaging displayed orange or white color, but when CVR was decreased, imaging displayed green or blue color. The blue color is indicated a steal phenomenon (→ Fig. 2). In the comparison between preoperative and postoperative CVR, the definition of improvement was a change of color from negative to positive, that is, change of color from a green or blue color to an orange color in at least 50% of the same area. A change of color is less than 50% of the area, indicated no improvement.

### Clinical Outcome

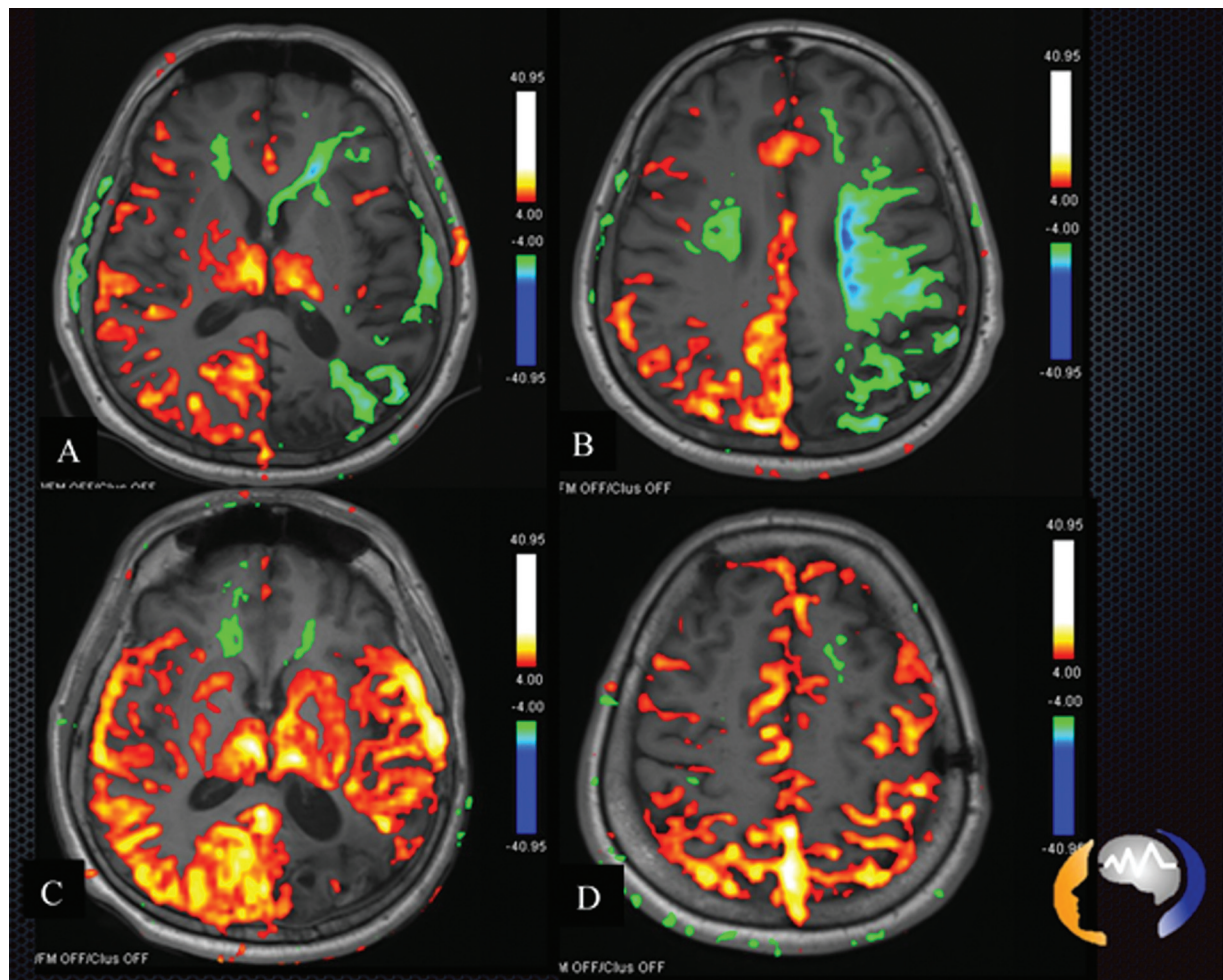
The modified Rankin Scale (mRS) score was used to evaluate clinical status before surgery, clinical outcome after surgery, and during follow-up period. After surgery, for at least 6 months, the improved mRS score as compared with before operation, was reduced to a scale that was more than or equal to 1. As per the meta-analysis,<sup>15</sup> good clinical outcomes referred to mRS scores less than or equal to 2 (mRS = 0–2).

The demographic data including underlying disease, age, presentation symptom, Suzuki's classification, and surgical outcome were presented as percentage and mean. Clinical outcome including recurrent stroke, improved mRS score, and improving CVR in BOLD MR were presented as percentage. Follow-up time duration was demonstrated as mean and standard deviation. The comparison of preoperative and postoperative mRS score was shown as Fisher's exact test and level of significance was set at *p*-value < 0.05. Statistical analyses were performed using SPSS for Windows version 16.0 (SPSS Inc., Chicago, Illinois, United States).

## Results

### Patient Characteristics (→ Table 1)

There were a total of 55 patients. There were 9 patients in the pediatric group (age < 18 years) and 46 patients in the adult group (age > 18 years). Overall, the mean age was 32.3 years (5–59 years). The gender ratio (female-to-male ratio) of the patients was 39:16 (2.5:1). There was no familial occurrence and almost all the adults in the study population had an underlying medical illness, such as hypertension (36.4%), diabetes mellitus (16.4%), and dyslipidemia (54.5%). Hyperthyroidism, that is Graves' disease, was associated with 10.9% (6/55) of the cases. Ischemic stroke was the common presentation, seen in 87.3% of cases (48/55), while 12.7% presented with hemorrhagic stroke, 7.3% with seizure, and 7.3% with headache. Note that 38.2% of all patients



**Fig. 2** (A and B) blood oxygenation level-dependent magnetic resonance (BOLD MR) showing decrease cerebrovascular reactivity (CVR) before surgical revascularization. (C and D) Showing increase after revascularization. The scale beside the picture showing an orange or white color indicated that cerebral blood flow (CBF) was positive, while a green or blue color indicated a decrease in CBF until the steal phenomenon.

had cognitive impairment. There was no hemorrhagic stroke in the pediatric group. Based on Suzuki's classification of MMD, majority of the patients had stage 3 (35.5%) and stage 4 (37.3%) MMD.

### Surgical Outcome (► Table 2)

Of all the cases included in the study, 35 patients underwent unilateral revascularization, and 21 patients underwent bilateral revascularization, adding up to total of 77 revascularization operations performed. Prior to 2020, EDAS, the first form of indirect revascularization, accounted for 55.8% (43/77) of instances, whereas EDMAS, which was developed and implemented after 2020, accounted for 44.2% (34/77). Note that 43.8% (7/16) of the pediatric group underwent EDMAS and 47.5% (29/61) of the adult group had EDMAS.

The overall patency rate achieved was 94.8% (73/77) with 93.8% (15/16) in the pediatric group and 95.1% (58/61) in the adult group, respectively. The mean follow-up time was 44.5 months.

Overall surgical complication rate was seen in 6.5% (5/77), and there were no complications in the pediatric group. The complications that occurred were one acute subdural hematoma, two postoperative seizures, one graft occlusion, and

one superficial wound infection. Acute subdural hematoma was treated using wide craniectomy due to brain swelling after removal of blood clot. Postoperatively, the patient fully recovered in 2 months. Postoperative seizure occurred in one patient, with a previous history of seizures. Another postoperative seizure was treated using the technique of indirect revascularization with EDMAS. One patient had a postoperative stroke, which took place on the sixth postoperative day. The MRI and MRA of the patients showed graft occlusion and a small new infarct in the left frontal cortex. Emergency reexploration with reanastomosis of STA-MCA was performed, following which the patient clinically recovered fully after 3 months.

The mortality rate from surgical intervention was 0.

### Clinical Outcome

The average duration of follow-up time was 44.5 months (8–98 months). The patients' mRS scores at the preoperative evaluation and at the latest follow-up are listed in ► Table 3. Of the 55 patients, there was no death and no severe neurological deficit (mRS 3–6). All the patients had good outcomes (mRS = 0–2). Note that 92.7% (51/55) of all the patients had an improved mRS score. After surgery, CVR in

**Table 1** Clinical manifestation and Suzuki’s classification of MMD patients

	Patient (N=55)
Age, mean (range, y)	32.42 ± 13.28 (5–59)
Female:male	39:16
Underlying disease (%)	36.4
1. Hypertension	16.4
2. Diabetes mellitus	54.5
3. Dyslipidemia	10.9
4. Hyperthyroid (Graves’ disease)	7.3
5. Epilepsy	
Presentation (%)	87.3
1. Infarct or TIA	12.7
2. Hemorrhage	7.3
3. Headache	7.3
4. Epilepsy	38.2
5. Cognitive impairment	
Suzuki’s classification (%)	3.6
1	15.5
2	35.5
3	37.3
4	8.2
5	0
6	
Operation	77

Abbreviations: MMD, moyamoya disease; TIA, transient ischemic attack.

**Table 2** Surgical outcome, morbidity, and mortality rate

	Patient (N=55)
Operation (hemisphere)	77
1. Bilateral	21
2. Unilateral	35
Graft patency (%)	94.8 (73/77)
Complication (%)	6.5 (5)
1. Subdural hematoma	1.3
2. Postoperative seizure	2.6
3. Graft occlusion	1.3
4. Wound complication	1.3
Postoperative stroke (%)	1.3
Mortality rate (%)	0

BOLD MR demonstrated an increase in CBF in almost all patients, as shown in **Fig. 1**. The improvement in CVR that was compared between before and after surgery was 93% (67/71).

**Discussion**

MMD is a chronic, progressive vascular stenosis that affects cerebral perfusion, especially in the long period.<sup>1</sup> It has been documented that cerebral revascularization guarantees more benefits than medical treatment, and that direct or combined revascularization has a better outcome than indirect revascularization, but the morbidity of direct revascularization is higher than that of indirect revascularization,<sup>2–4,6,7,11,12</sup>

and these operations require a high level of experience of the surgeon.

This study was conducted in Thailand, which is a part of Southeast Asia, and there were no reported results of combined revascularization for MMD. Our study had a follow-up period of at least 6 months, and there was a follow-up period of more than 5 years. According to demographic data, this study demonstrated that the gender ratio was similar in Japan and Korea, approximately 2:1, with females more frequently affected. It was found that ischemic symptoms are the most common presentation in pediatric and adults.

For the underlying disease, there are diabetes mellitus, hypertension, and dyslipidemia that are risk factor for stroke. In this study, patients had hyperthyroidism before diagnosis of MMD, approximately 10.9% (6/55). Existing literatures<sup>15,16</sup> on the subject suggest that Graves’ disease is associated with aggressive symptoms in MMD. According to Hiruma et al,<sup>16</sup> the mechanisms involved damage to blood vessel walls due to increased cerebral oxygen consumption and CBF; second is sympathetic regulation causing cerebral vascular stenosis; and the third is vascular abnormalities resulting from immune stimulation of the thyroid gland being involved in T cell function. Thyroid dysfunction may affect the onset of MMD and the manifestation of its symptoms. In Japan, the diagnosis of MMD with Graves’ disease often occurs within 1 year after the onset of Graves’ disease. This literature suggests that uncontrolled hyperthyroidism with MMD should be consulted with a neurosurgeon because the pathophysiology may induce the progression of MMD. In this study, hyperthyroidism due to Graves’ disease was associated with MMD, approximately 10.9% (6/55). Three patients swallowed iodine radiation before surgery due to uncontrolled thyroid hormone. Two patients took high-dose antithyroid drugs, and after surgery, two patients stepped down from the medication until it was stopped. In Thailand, uncontrolled hyperthyroidism, especially Graves’ disease, was treated by an endocrinologist. Patients control thyroid disease with medication for a few years or more. The last treatment option is surgery or swallowing iodine radiation with Eltroxin supplement. Patients were not examined for vasculopathy in the brain until symptoms of stroke appeared. In MMD, some patients may be misdiagnosed as impaired cognitive function and did not receive further investigation nor proper treatment for MMD. This topic is interested in early diagnosis and treatment for reduced morbidity. In the future, the authors intend to initiate early investigation and treatment in this group, especially those with uncontrolled hyperthyroidism, as after revascularization, this group has good control of thyroid function.

Based on meta-analysis of clinical outcome data,<sup>17,18</sup> the clinical outcome of MMD after combined revascularization shows good outcome of 0.92 (95% confidence interval, 0.89–0.96) with a follow-up time of at least 6 months. This study had a good outcome (100%), as observed through mRS less than or equal to 2. The improved mRS score after revascularization was 92.7% (p=0.002), which was a decrease of at least 1 score.

**Table 3** Follow-up time and mRS scores at preoperative evaluation and last follow-up in group

	Patient	p-Value
Follow-up duration (mean ± SD, mo)	44.5 ± 25.1	
Preoperative mRS 1. No significant disability 2. Slightly disability 3. Moderate disability	40 25.5 34.5	
Postoperative mRS 0 - No symptom 1 - No significant disability 2 - Slightly disability	63.6 27.3 9.1	0.002 (Fisher's exact test)
Recurrent stroke	1/77 (1.3%)	
Improving CVR in BOLD MR	66/71 (93%)	
Improved mRS	51/55 (92.7%)	

Abbreviations: CVR, cerebrovascular reactivity; BOLD MR, blood oxygenation level-dependent magnetic resonance; mRS, modified Rankin Scale; SD, standard deviation.

For surgical outcome, the patency rates of direct bypass reported are 88 to 100% in Asia,<sup>6,18,19</sup> 95.2% in North America,<sup>7</sup> and 94% in Germany.<sup>20</sup> The overall patency rate in this study is 94.8%, with 95.1% in the adult group and 93.8% in the pediatric group.

The complication of surgery is 0 to 12% worldwide,<sup>8,9,18,19</sup> while this study had 6.5% (5/77) of all complications. According to Schubert et al,<sup>21</sup> postoperative infarction is related to graft occlusion. It almost occurs in the first 24 hours but can also appear in the first week after operation.<sup>19,21</sup> Rate of postoperative ischemia in MMD patients after revascularization varies from 1.5 to 11.4%.<sup>4,7,19,22,23</sup> In this study, 1.3% (1/77) had a postoperative stroke due to graft occlusion. The patient had a new hemiparesis and MRI brain scans showed an infarct in the right frontal area and bypass graft occlusion on postoperative day 6. The patient had a reoperation and reanastomosis. The patient improved to near-normal after 3 months. Other complications were one subdural hematoma, two seizure, and one wound problem.

For recurrent stroke after direct or combined revascularization, new ischemic stroke was 0.0 to 1.6%.<sup>4,6</sup> This study had approximately 1.3% new stroke after revascularization.

While the documented mortality rate is 0 to 2.3% worldwide,<sup>4,6,7</sup> there was no mortality rate in this study.

This study reveals that combined revascularization in MMD had good clinical outcome and low complication compared with the world. In the first period, the study used EDAS for indirect revascularization due to its ease and early era. The authors had complication after EDAMS technique. In the next era, the literature suggested that the EDAMS technique can increase flow and good outcomes more than the EDAS technique,<sup>20,24,25</sup> which led to the change in the indirect revascularization technique used. Our future work plans to look into the details of CVR and postoperative clinical outcomes using different techniques of indirect revascularization in MMD.

Liu et al<sup>8</sup> suggest that the group of patients with hemorrhagic stroke had more aggressive symptoms than the ische-

mic group because rebleeding and mortality rates are higher than those of ischemic MMD. Surgical revascularization can prevent rebleeding in this group. There is a report of hemorrhage recurrence of 1.9% at 2-year follow-up after direct revascularization in adult patients.<sup>3</sup> After follow-up, this study had no recurrent hemorrhagic stroke but recurrent ischemic stroke of 1.3%. This study demonstrates improved clinical outcome and prevention of recurrent stroke. Nevertheless, this article has limitations. The duration of the long-term follow-up should exceed 5 years. Second, the analysis makes no mention of CHS. The literature reports a prevalence of CHS between 18 and 27.5%.<sup>18,23</sup> The authors believe that the condition may be underdiagnosed because it was asymptomatic and there may be only one anastomosis. Third, BOLD MR with carbon dioxide is a useful technique due to its near-normal physiology, repeatability due to the absence of gadolinium, and absence of radiation, but it requires patient participation in accordance with the technique's protocol. This technique could not be used on all patients because some pediatric patients, particularly those younger than 7 years old, were unable to undergo BOLD MR. Occasionally, the adult group also cannot collaborate.

For the evaluation of cerebral perfusion, a positron emission tomography (PET) scan with an acetazolamide (ACZ) challenge is a predictive instrument. However, this device is expensive, scarce, and necessitates ACZ injection and radiation exposure.<sup>26</sup> Comparing PET and single-photon emission computed tomography with CO<sub>2</sub>-triggered BOLD MR before and after cerebral revascularization has been validated in the literature.<sup>26,27</sup> In this study, we utilized BOLD MR in preoperative, postoperative, and follow-up contexts to assess the CVR in adult and pediatric patients older than 7 years. This publication uses BOLD MR with carbon dioxide stimuli in pre- and postoperation. We observed an increase in CVR following surgery (93.0% with distinct colors), a stable CVR of approximately 7%, and no decrease in CVR. In the future, the authors hope to demonstrate a correlation between an increase in CVR and clinical outcome.

## Conclusion

Combined revascularization in MMD in the Thai population has a good clinical outcome, an acceptable risk of complication, and a reduced recurrent rate of stroke. Clinical and surgical outcome should be studied in the long term with use of BOLD MR with carbon dioxide stimuli for the evaluation of CBF in the patients.

### Conflict of Interest

None declared.

## References

- Wanebo JKN, Zabramski J, Spetzler R, eds. *Moyamoya Disease: Diagnosis and Treatment*. 1st ed. New York: Thieme
- Kim DS, Huh PW, Kim HS, et al. Surgical treatment of moyamoya disease in adults: combined direct and indirect vs. indirect bypass surgery. *Neurol Med Chir (Tokyo)* 2012;52(05):333–338
- Jiang H, Ni W, Xu B, et al. Outcome in adult patients with hemorrhagic moyamoya disease after combined extracranial-intracranial bypass. *J Neurosurg* 2014;121(05):1048–1055
- Kim T, Oh CW, Kwon OK, et al. Stroke prevention by direct revascularization for patients with adult-onset moyamoya disease presenting with ischemia. *J Neurosurg* 2016;124(06):1788–1793
- Cheung AH, Lam AK, Ho WW, et al. Surgical outcome for moyamoya disease: clinical and perfusion computed tomography correlation. *World Neurosurg* 2017;98:81–88
- Cho WS, Kim JE, Kim CH, et al. Long-term outcomes after combined revascularization surgery in adult moyamoya disease. *Stroke* 2014;45(10):3025–3031
- Guzman R, Lee M, Achrol A, et al. Clinical outcome after 450 revascularization procedures for moyamoya disease. *Clinical article. J Neurosurg* 2009;111(05):927–935
- Liu XJ, Zhang D, Wang S, et al. Clinical features and long-term outcomes of moyamoya disease: a single-center experience with 528 cases in China. *J Neurosurg* 2015;122(02):392–399
- Deng X, Gao F, Zhang D, et al. Effects of different surgical modalities on the clinical outcome of patients with moyamoya disease: a prospective cohort study. *J Neurosurg* 2018;128(05):1327–1337
- Zhang M, Tang J, Liu N, Xue Y, Ren X, Fu J. Postoperative functional outcomes and prognostic factors in two types of adult moyamoya diseases. *J Stroke Cerebrovasc Dis* 2020;29(08):104846
- Matsushima T, Inoue T, Suzuki SO, Fujii K, Fukui M, Hasuo K. Surgical treatment of moyamoya disease in pediatric patients—comparison between the results of indirect and direct revascularization procedures. *Neurosurgery* 1992;31(03):401–405
- Rashad S, Fujimura M, Niizuma K, Endo H, Tominaga T. Long-term follow-up of pediatric moyamoya disease treated by combined direct-indirect revascularization surgery: single institute experience with surgical and perioperative management. *Neurosurg Rev* 2016;39(04):615–623
- Zheng J, Yu LB, Dai KF, Zhang Y, Wang R, Zhang D. Clinical features, surgical treatment, and long-term outcome of a multicenter cohort of pediatric moyamoya. *Front Neurol* 2019;10:14
- Fukui M. Guidelines for the diagnosis and treatment of spontaneous occlusion of the circle of Willis ('moyamoya' disease). Research Committee on Spontaneous Occlusion of the Circle of Willis (Moyamoya Disease) of the Ministry of Health and Welfare, Japan. *Clin Neurol Neurosurg* 1997;99(suppl 2):S238–S240
- Chen J-B, Lei D, He M, et al. Clinical features and disease progression in moyamoya disease patients with Graves disease. *J Neurosurg* 2015;123(04):848–855
- Hiruma M, Watanabe N, Mitsumatsu T, et al. Clinical features of moyamoya disease with Graves' disease: a retrospective study of 394,422 patients with thyroid disease. *Endocr J* 2023;70(02):141–148
- Yao Z, You C. Effect of surgery on the long-term functional outcome of moyamoya disease: a meta-analysis. *Turk Neurosurg* 2019;29(02):171–179
- Li L, Wang A, Wang C, et al. Superficial temporal artery-middle cerebral artery bypass in combination with encephalo-myo-synangiosis in Chinese adult patients with moyamoya disease. *Front Surg* 2023;10:1100901
- Yu J, Shi L, Guo Y, Xu B, Xu K. Progress on complications of direct bypass for moyamoya disease. *Int J Med Sci* 2016;13(08):578–587
- Acker G, Fekonja L, Vajkoczy P. Surgical management of moyamoya disease. *Stroke* 2018;49(02):476–482
- Schubert GA, Biermann P, Weiss C, et al. Risk profile in extracranial/intracranial bypass surgery—the role of antiplatelet agents, disease pathology, and surgical technique in 168 direct revascularization procedures. *World Neurosurg* 2014;82(05):672–677
- Okuyama T, Kawabori M, Ito M, Sugiyama T, Kazumata K, Fujimura M. Outcomes of combined revascularization surgery for moyamoya disease without preoperative cerebral angiography. *World Neurosurg* 2022;165:e446–e451
- Kazumata K, Ito M, Tokairin K, et al. The frequency of postoperative stroke in moyamoya disease following combined revascularization: a single-university series and systematic review. *J Neurosurg* 2014;121(02):432–440
- Xu B, Song DL, Mao Y, et al. Superficial temporal artery-middle cerebral artery bypass combined with encephalo-duro-myo-synangiosis in treating moyamoya disease: surgical techniques, indications and midterm follow-up results. *Chin Med J (Engl)* 2012;125(24):4398–4405
- Fujimura M, Tominaga T. Lessons learned from moyamoya disease: outcome of direct/indirect revascularization surgery for 150 affected hemispheres. *Neurol Med Chir (Tokyo)* 2012;52(05):327–332
- Hauser TK, Seeger A, Bender B, et al. Hypercapnic BOLD MRI compared to H<sub>2</sub><sup>15</sup>O PET/CT for the hemodynamic evaluation of patients with moyamoya disease. *Neuroimage Clin* 2019;22:101713
- Roder C, Klose U, Hurth H, et al. Longitudinal reproducibility of CO<sub>2</sub>-triggered BOLD MRI for the hemodynamic evaluation of adult patients with moyamoya angiopathy. *Cerebrovasc Dis* 2021;50(03):332–338