



Assessment of the Prospective Protection of Quercetin on Irradiated Submandibular Salivary Gland in Mice

Nadia A. Radi¹ Doaa A. Habba^{1,2} Seham I. Halloom³ Hanaa M. Abd Elsamia⁴

¹Department of Oral and Dental Pathology, Faculty of Dental Medicine for Girls, Al Azhar University, Cairo, Egypt

²Department of Oral and Maxillofacial Surgery and Diagnostic Sciences, Faculty of Dentistry, Najran University, Saudi Arabia

³Department of Oral and Dental Biology, Faculty of Dental Medicine for Girls, Al Azhar University, Cairo, Egypt

⁴Department of Oral and Dental Pathology, Faculty of Oral and Maxillofacial Surgery, Zagazig University, Zagazig, Egypt

Address for correspondence Doaa Adel Habba, Department of Oral and Maxillofacial Surgery and Diagnostic Sciences, College of Dentistry, Najran University, Street King Khalid street 8383, Najran, Zip/Post code: 66252, Saudi Arabia Department of Oral and Dental Pathology, Faculty of Dental Medicine for Girls, Al Azhar University Cairo, Egypt (e-mail: doaahabba50@gmail.com).

Eur J Gen Dent 2025;14:171–177.

Abstract

Objectives This study aimed to assess the prospective protection of quercetin on irradiated submandibular salivary gland in mice histologically and immunohistochemically.

Material and Methods Four groups of male mice were included in the study. *Group I* included 10 mice that will not be subjected to gamma radiation, *group II* included 10 mice that will receive quercetin 50 mg/kg body weight (BW) for 30 days, *group III* included 10 irradiated mice that will receive a dose of only 15 Gy, and *group IV* included 10 irradiated mice that will be given quercetin 50 mg/kg BW for 30 days prior to radiotherapy.

Results The analysis of variance (ANOVA) test revealed that the difference between all groups was extremely statistically significant ($p < 0.000$). Turkey's post hoc test revealed that there were no statistically significant differences between groups I and II but both groups showed statistically significant differences with groups III and IV. Also, there were statistically significant differences between groups III and IV.

Conclusion Quercetin possesses the ability to protect against radiation-induced cellular damage and maintain tissue integrity, so it holds promise as a protective agent for salivary glands against radiation-induced damage. Quercetin has promising potential therapeutic benefits for individuals undergoing radiation therapy.

Keywords

- ▶ PCNA
- ▶ quercetin
- ▶ ROS

Introduction

Salivary glands are exocrine glands that are responsible for the production and secretion of saliva. Its structural components include the stroma and parenchymal cells, which

include ductal, acinar, and myoepithelial cells. In addition to these epithelial cells, the salivary gland also hosts progenitor cells that are responsible for self-renewal and differentiation into adult cells in response to stress or injury.¹ Patients with head and neck cancer who undergo radiation therapy (RT) as part of their treatment may be severely affected by radiation-induced damage to healthy tissue. Early adverse

* This study was performed at the Faculty of Dental Medicine for Girls, Al Azhar University, Cairo, Egypt.

effects of RT, including dermatitis and oral mucositis, may happen during or soon after RT and could lead to treatment interruption. Furthermore, late adverse effects from RT may significantly lower the patient's quality of life, such as osteoradionecrosis, tissue fibrosis, and salivary gland hypofunction.²

Salivary gland hypofunction is caused by damage to highly radiosensitive acinar salivary gland cells. It is anticipated that the salivary glands will be unresponsive to radiation due to the slow turnover rate of their cells (60–120 days); however, the glands respond rapidly, which leads to changes in the composition and production of saliva.³ Ionizing radiation (IR) commonly leads to the overproduction of reactive oxygen species (ROS). When ROS levels increase in cells, they produce harmful effects on important cellular structures like organelles, lipids, proteins, and nucleic acids, which can ultimately lead to cell death.⁴ Radiation-induced tissue damage can be minimized by the use of antioxidant agents that neutralize and restrict ROS action. Earlier studies have reported that a polyphenol can effectively prevent radiation-induced damage to the salivary glands. One type of polyphenol that is widely distributed and plentiful in nature is quercetin.⁵

Quercetin is a natural flavonoid found in common food species including apples, tea, onions, nuts, berries, cauliflower, cabbage, and many others. It is recognized for its antioxidant, and anti-inflammatory properties both *in vivo* and *in vitro*. The ability of quercetin to scavenge free radicals protects it against a number of age-related disorders. Numerous clinical studies show that quercetin supplementation is used to treat and prevent various chronic diseases.⁶ Accurate deoxyribonucleic acid (DNA) replication is necessary for proper cell division. Human cells suffer from many types of “stress” at the replication fork, where the stress arises from replication obstacles and damage sources. Oncogene activation, misregulated origin licensing, nucleotide depletion, and re-replication are the replication obstacles. IR, ultraviolet (UV), and ROS are some of the damaging sources. Proliferating cell nuclear antigen (PCNA) is crucial in DNA synthesis and DNA damage tolerance. It is essential for regulating DNA replication activity and preserving integrity of genome. It acts as a hub for proteins included in cell-cycle control, DNA synthesis, and DNA damage response and repair. Additionally, PCNA undergoes a variety of posttranslational changes, such as ubiquitination, which aids in the coordination of DNA replication and resistance to genotoxic damage.⁷ So, this study aimed to assess the prospective protection of quercetin on irradiated submandibular salivary gland in mice histologically (hematoxylin and eosin [H&E] staining) and immunohistochemically by PCNA

Materials and Methods

Treatment and Animals

Quercetin was purchased from Sigma Chemical Co. (St. Louis, MO, United States). In this research, 40 adult male mice between the ages of 8 and 12 weeks with weights between 18 and 25 g were utilized. For 30 days, 50 mg/kg of quercetin

was taken orally after being dissolved in distilled water. During the trial period, quercetin was given on alternate days. The facilities, food, and scarification technique were all carried out in accordance with the guidelines established by the ethical committee for animal experiments. The Ethics Committee of the Faculty of Dental Medicine at Al-Azhar University provided the study's ethical code and approval (code no.: P-PD-PD-24-17).

Irradiation Process

At the end of 30 days, thiopental sodium (Egyptian Pharmaceutical International Company [EPICO], purchased from the local market), an exceptionally short-acting barbiturate (60 mg/kg), was given intraperitoneally to anaesthetize 20 adult male mice in groups III and IV. The mouse's head and neck were then exposed to 15 Gy of gamma radiation, with the rest of its body being shielded by a lead shield.⁸

Experimental Groups

Group I (normal control) included 10 mice that were not subjected to gamma radiation.

Group II (positive control) included 10 mice that received quercetin 50 mg/kg body weight (BW) on alternate days for 30 days.

Group III included 10 irradiated mice that received 15 Gy of gamma radiation.

Group IV included 10 irradiated mice that received quercetin + IR (was given quercetin 50 mg/kg BW on alternate days for 30 days prior to radiotherapy).

Specimen's Collection

Mice from each group were anaesthetized and individually slaughtered by cervical dislocation on day 7 after radiation. A vertical incision was made in the neck, and the skin was carefully pulled back to reveal the submandibular gland. The submandibular glands were extracted and then preserved in 10% formalin buffer. Regular dehydration, clearing, and paraffin wax embedding were performed for the specimens.

Specimen's Preparation

For Histological Examination

Slices of 4- μ m thickness were cut, stained with H&E stain, and examined under a light microscope with a magnification of $\times 200$.

For immunohistochemical staining, paraffin sections of 4- μ m thickness were cut and mounted on a positively charged glass slide. Sections were deparaffinized with xylene, rehydrated, and washed with phosphate-buffered saline (PBS). For 10 minutes, sections were incubated in 0.3% H₂O₂ to inhibit endogenous peroxidase activity. After immersing the slides in a citrate buffer solution at pH of approximately 6, they were subjected to three 5-minute microwave bursts at 95°C before being cleaned with PBS to extract antigen. Sections were then treated with the indicated primary antibody, PCNA mouse monoclonal antibody (Dako lab). After this, the sections were washed several times with PBS. The sections were incubated with secondary biotin-coupled antibody for 5 to 10 minutes at

room temperature, washed several times with PBS, and immunolabeled with diaminobenzidine (DAB).⁹ The tissues were inspected using $\times 200$ magnification light microscopy.

Histomorphometric Analysis

To determine the location of immunostaining within the tissue and the prevalence of positive cases, the immunostained sections were inspected using a light microscope. If tumor cells showed nuclear staining, they were regarded as PCNA positive. Computerized image analysis using a Leica image analyzer (Germany) was used. The percentage of immunostained cells relative to the area was used to estimate the immunoreactivity of PCNA. To convert the measurement units (pixels) produced by the image analyzer program into actual micrometer units, the image analyzer was automatically modified. The percentage of positive immune reactive region of PCNA was computed with respect to a reference measuring frame of $11,434.9 \mu\text{m}^2$ using magnification ($\times 100$). From each slide, five fields were obtained in turn for the purpose of histomorphometric

analysis. Next, each specimen's mean values were determined.

Statistical Analysis

The mean and standard deviation (SD) values were used to present the data. The different groups were compared using a one-way analysis of variance (ANOVA). When the ANOVA test was significant, Tukey's post hoc test was employed to compare the groups in pairs. At $p \leq 0.05$, the significance level was established. IBM SPSS Statistics version 20 for Windows was used for the statistical analysis.

Result

Histological Results

Histological changes in salivary glands are shown by H&E staining. The control and quercetin groups had normal ductal and acinar cells with well-defined lobules (\rightarrow Fig. 1A, and B, respectively). In the IR group, acinar atrophy and shrinkage with concomitant increase in interacinar as well as interlob-

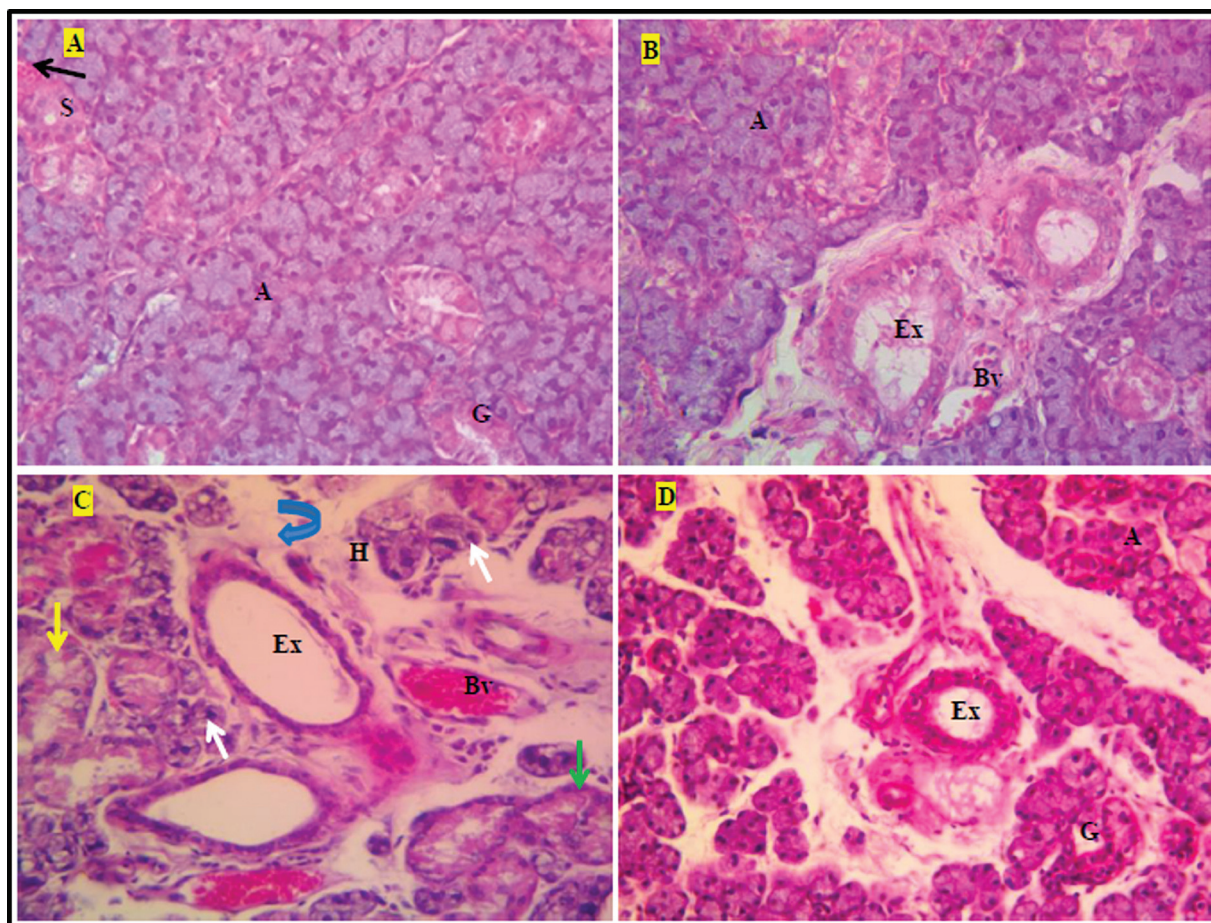


Fig. 1 Photomicrographs of the submandibular salivary glands of (A) group I showing normal gland architecture and structure, striated duct (S), blood vessel (Bv), acini (A), and granular convoluted tubules (G); (B) group II showing relatively normal gland architecture and structure similar to group I; (C) group III showing severely destructed glands with loss of acinar and ductal architecture, vacuolated acinar and ductal cells (blue and green arrows), cell lysis and cell remnants (white and yellow arrows), extremely wide interlobular space with excretory duct had dilated lumen and reduction in the height of its lining cells (Ex), severe hyalinization of the supporting stroma (H), and congested blood vessel (Bv) with abnormally thickened wall and degenerated endothelial lining; and (D) group IV showing greatly more preserved acinar and ductal architecture and cell lining in addition to connective tissue stroma compared with group III (hematoxylin and eosin [H&E], $\times 200$).

ular spaces were observed. The acini lacked their normal architecture and lost their compact arrangement with generalized cytoplasmic vacuolization. The nuclei of the acinar cells exhibited variations in size and shape with a great number of pyknotic nuclei observed. Acinar lysis and cellular remnants were also noted scattered throughout the gland. Also, there was acinar and ductal lysis and cell death. The connective tissue stroma appeared infiltrated with inflammatory cells. Hyalinized collagen fiber bundles adjacent to dilated blood vessels could also be detected. The dilated blood vessels were more obviously related to the excretory ducts and filled with red blood cells (RBCs; ►Fig. 1C).

The quercetin-treated groups had fewer vacuoles, clearer lobular structures, and more zymogen granules than the IR group. Also, vascular dilatation and congestion were not significant. These results suggest that quercetin preserves salivary gland function without detrimental effects on overall structure following radiation (►Fig. 1D).

Immunohistochemical Results

The PCNA expression in normal salivary gland mucosa (control group) was randomly distributed in acinar and ductal cells. The number of PCNA-positive cells had sharply decreased in the irradiated group. The PCNA expression level

in quercetin-pretreated mice was nearly similar to that of the nonirradiated control group. These results demonstrated that quercetin pretreatment significantly reduced radiation-induced damage of the salivary gland mucosa. In addition, quercetin also maintained the proliferative activity of the salivary gland stem cells and enhanced their repair after irradiation that was detected by PCNA expression (►Fig. 2).

Statistical Results

The ANOVA test revealed that the difference between all groups was extremely statistically significant ($p < 0.000$). Turkey's post hoc test revealed that there were no statistically significant differences between groups I and II, but both groups showed statistically significant differences with groups III and IV. Also, there were statistically significant differences between groups III and IV (►Table 1, ►Fig. 3).

Discussion

It has been demonstrated that IR interacts with the biological systems during radiotherapy to produce excessive ROS. ROS production is thought to be a major factor in tissue damage caused by radiation. Moreover, ROS lower the intracellular antioxidant concentration. Based on these premises, identi-

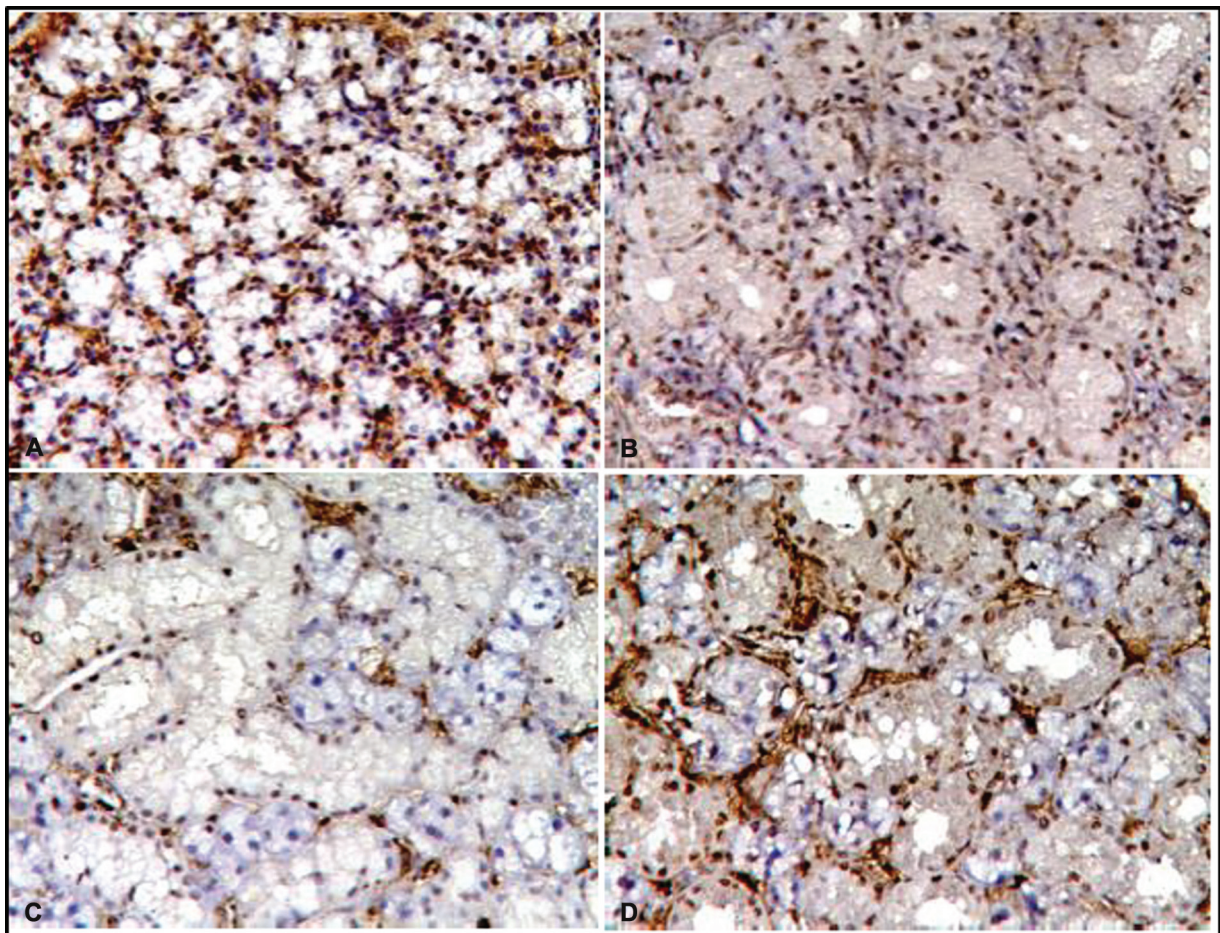


Fig. 2 Photomicrographs of proliferating cell nuclear antigen (PCNA) expressions in different groups showing the +ve immunoreaction for PCNA was confined to nuclei of the acinar and ductal cells of all groups ($\times 200$).

Table 1 Comparison of proliferating cell nuclear antigen (PCNA) mean area percentage between all groups

Groups	Mean	Standard deviation	Standard error	95% confidence interval for mean		Minimum	Maximum
				Lower bound	Upper bound		
Normal control (group I)	7.5800 ^a	0.85264	0.38131	6.5213	8.6387	6.30	8.50
Quercetin group (group II)	7.9200 ^a	0.85264	0.38131	6.4446	9.3954	6.50	9.70
Radiation group (group III)	2.6800 ^b	1.18828	0.53141	1.9278	3.4322	2.00	3.50
Radiation + quercetin group (group IV)	5.7200 ^c	0.60581	0.27092	4.4195	7.0205	4.50	7.20

Note: Significance at $p \leq 0.05$. Tukey's post hoc test: means with different superscript letters are statistically significantly different.

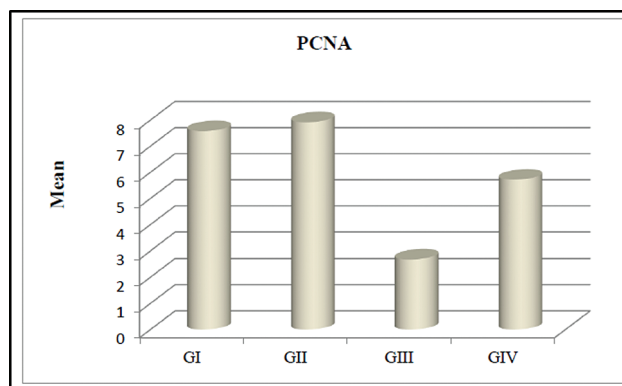


Fig. 3 Column chart showing the proliferating cell nuclear antigen (PCNA) mean area percentage in different groups. GI, group I; GII, group II; GIII, group III; GIV, group IV.

fyng natural novel molecules capable of counteracting oxidative stress is highly significant, drawing interest from scientists worldwide.^{10,11}

The foregoing study revealed marked degenerative changes in the submandibular glands of the irradiated animals, by histological examination of the H&E-stained sections. These include acinar atrophy and shrinkage with concomitant increase in interacinar as well as interlobular spaces. These findings were consistent with previous studies.^{12,13} The noticed increase in the interacinar and interlobular spaces as well as the dispersed acini occurred mainly due to acinar shrinkage and accumulation of edema fluid. In a previous study, the acinar atrophy and shrinkage resulted from radiation-induced disturbance in tissue homeostasis and death via apoptosis. In the acute postradiation phase, a drop in cell proliferation occurred.¹³

Moreover, the accumulation of edema fluid could be explained by radiation-induced generation of ROS that caused apoptosis and loss of endothelial cells via superoxide (O_2^-). This damage was manifested by microvascular dysfunction, increased capillary permeability, local inflammation, and a decrease in microvessel density.^{8,14} Furthermore, the results of this study showed generalized cytoplasmic vacuolization in the acinar and ductal cells. This finding closely agreed with previous studies that reported the presence of round to ovoid vacuoles widely distributed in the irradiated gland parenchyma.^{3,15} This vacuolization could be explained by radiation-induced free radical generation, which targeted the plasma membrane phospholipids causing membrane damage, including damage to muscarinic receptors, which stimulate watery secretion, and plasma membrane channels, aquaporins. This led to a reduction in water secretion, which accumulated within the cytoplasmic vacuoles.^{16,17}

The obtained results also showed nuclear atypia of acinar cells in the form of anisonucleosis and poikilonucleosis with nuclear pyknosis. This finding confirmed the previous report that stated that nuclear atypia of epithelial cells, including surface epithelium, glands, and ducts, may occur following IR.¹⁸ In addition, acinar and ductal lysis and cellular

remnants were noted scattered throughout the gland, similarly as previous studies.^{13,19} Radiation-induced cellular DNA damage and ROS generation may be the cause of apoptosis, which results in ductal and acinar lysis and cell death. ROS induce lipid peroxidation and serous granules lysis, releasing free radicals and their proteolytic enzymes into the cytoplasm of the cell near the nucleus.⁴

The presence of inflammatory cell infiltrates within the connective tissue stroma, in the present study, is also consistent with previous studies that reported the presence of inflammatory reaction in the early postradiation phase, which begins within hours after radiation and continues later on as chronic inflammation that persists.^{20,21} Hyalinized collagen fiber bundles adjacent to dilated congested blood vessels could also be observed in this study, which is in agreement with a previous study that reported the presence of hyaluronic acid in the interstitial tissue as a smooth thin staining.²² Several studies also confirmed postradiation dilatation and congestion of blood vessels.^{23,24}

In contrast, in the current study, the quercetin group had normal ductal and acinar cells with well-defined lobules. In addition, IR + quercetin-treated group had fewer vacuoles, clearer lobular structures, and more zymogen granules than the IR group. Also, vascular dilatation and congestion were not significant. These results suggest that quercetin maintains salivary gland function without detrimental effects on overall structure after radiation. In addition, the PCNA expression level in the quercetin-pretreated mice was nearly similar to that of the nonirradiated control group, in this study. These results demonstrate that quercetin pretreatment significantly reduced radiation-induced damage of salivary gland mucosa. In addition, quercetin also maintains the proliferative activity of salivary gland stem cells and enhance their repair after irradiation, which is detected by the PCNA expression.

This can be explained by the fact that quercetin exhibits antioxidant activity by controlling the expression levels and activity of antioxidant enzymes, such as superoxide dismutase (SOD), Nicotinamide Adenine Dinucleotide (Phosphate) (NAD(P)H) oxidase and catalase (CAT), glutathione S-transferase (GSH), and oxidoreductase. These effects of quercetin could overcome the IR-induced damage of the salivary gland cells, since quercetin pretreatment reduced IR-induced cellular ROS generation and oxidative stress.²⁵

Moreover, quercetin has strong anti-inflammatory and immunomodulatory effects. It has been demonstrated that quercetin can inhibit the synthesis of proinflammatory cytokines, including interleukin-1 (IL-1), IL-4, IL-6, and tumor necrosis factor- α (TNF- α). It can also decrease the production of inflammatory molecules such as cyclooxygenase-2 (COX-2), nuclear factor-kappa B (NF- κ B), activator protein 1 (AP-1), mitogen-activated protein kinase (MAPK), reactive nitric oxide synthase (NOS), and C-reactive protein (CRP). Since the proinflammatory stimuli and cytokines have a negative effect on the endothelial cell activity, quercetin has a protective effect on the vascular endothelium.^{26,27} Quercetin, being a natural compound with antioxidant properties, may offer a nontoxic

alternative to synthetic radioprotective agents. So, it significantly improves the quality of life for patients undergoing radiotherapy by reducing radiation-induced damage to salivary glands, thus alleviating symptoms like xerostomia. These benefits underscore the importance of continued research in this area, with the aim of translating promising preclinical findings into real-world therapeutic applications. However, the importance of using animal models in the preclinical studies, the genetic background of the mice used, housing conditions, and handling can introduce confounding factors that affect the study outcomes.

Conclusion

The results of the current study show that quercetin possesses the ability to protect against radiation-induced cellular damage and maintains tissue integrity. Therefore, it holds promise as a protective agent for salivary glands against radiation-induced damage, offering potential therapeutic benefits for individuals undergoing RT.

Funding
None.

Conflict of Interest
None declared.

References

- Pillai S, Munguia-Lopez JG, Tran SD. Hydrogels for salivary gland tissue engineering. *Gels* 2022;8(11):730
- Juvkam IS, Zlygosteva O, Arous D, et al. A preclinical model to investigate normal tissue damage following fractionated radiotherapy to the head and neck. *J Radiat Res* 2023;64(05):857
- Liu Z, Dong L, Zheng Z, et al. Mechanism, prevention, and treatment of radiation-induced salivary gland injury related to oxidative stress. *Antioxidants* 2021;10(11):1666
- Juan CA, Pérez de la Lastra JM, Plou FJ, Pérez-Lebeña E. The chemistry of reactive oxygen species (ROS) revisited: outlining their role in biological macromolecules (DNA, lipids and proteins) and induced pathologies. *Int J Mol Sci* 2021;22(09):4642
- Prades-Sagarra È, Yaromina A, Dubois LJ. Polyphenols as potential protectors against radiation-induced adverse effects in patients with thoracic cancer. *Cancers (Basel)* 2023;15(09):2412
- Al-Khayri JM, Sahana GR, Nagella P, Joseph BV, Alessa FM, Al-Mssallem MQ. Flavonoids as potential anti-inflammatory molecules: a review. *Molecules* 2022;27(09):2901
- Zhang S, Zhou T, Wang Z, et al. Post-translational modifications of PCNA in control of DNA synthesis and DNA damage tolerance—the implications in carcinogenesis. *Int J Biol Sci* 2021;17(14):4047–4059
- Mizrachi A, Cotrim AP, Katabi N, Mitchell JB, Verheij M, Haimovitz-Friedman A. Radiation-induced microvascular injury as a mechanism of salivary gland hypofunction and potential target for radioprotectors. *Radiat Res* 2016;186(02):189–195
- Soleimanpour H, Shirian S, Oryan A, Daneshbod K, Bagheri N, Daneshbod Y. Cytologic, immunocytologic, histopathologic and immunohistologic diagnosis of the poorly differentiated Sertoli-Leydig cell tumor. *Acta Cytol* 2011;55(04):382–386
- Nuszkiewicz J, Woźniak A, Szewczyk-Golec K. Ionizing radiation as a source of oxidative stress—the protective role of melatonin and vitamin D. *Int J Mol Sci* 2020;21(16):5804

- 11 Jomova K, Raptova R, Alomar SY, et al. Reactive oxygen species, toxicity, oxidative stress, and antioxidants: chronic diseases and aging. *Arch Toxicol* 2023;97(10):2499–2574
- 12 Krishnan M, Tennavan A, Saraswathy S, Sekhri T, Singh AK, Nair V. Acute radiation-induced changes in Sprague-Dawley rat submandibular glands: a histomorphometric analysis. *World J Oncol* 2017;8(02):45–52
- 13 Bralic M, Muhvic-Urek M, Stemberga V, et al. Cell death and cell proliferation in mouse submandibular gland during early post-irradiation phase. *Acta Med Okayama* 2005;59(04):153–159
- 14 Cotrim AP, Sowers A, Mitchell JB, Baum BJ. Prevention of irradiation-induced salivary hypofunction by microvessel protection in mouse salivary glands. *Mol Ther* 2007;15(12):2101–2106
- 15 Li Z, Zhao D, Gong B, et al. Decreased saliva secretion and down-regulation of AQP5 in submandibular gland in irradiated rats. *Radiat Res* 2006;165(06):678–687
- 16 Coppes RP, Meter A, Latumalea SP, Roffel AF, Kampinga HH. Defects in muscarinic receptor-coupled signal transduction in isolated parotid gland cells after in vivo irradiation: evidence for a non-DNA target of radiation. *Br J Cancer* 2005;92(03):539–546
- 17 Konings AW, Coppes RP, Vissink A. On the mechanism of salivary gland radiosensitivity. *Int J Radiat Oncol Biol Phys* 2006;64(01):330
- 18 Fajardo LF. The pathology of ionizing radiation as defined by morphologic patterns. *Acta Oncol* 2005;44(01):13–22
- 19 Urek MM, Bralic M, Tomac J, et al. Early and late effects of X-irradiation on submandibular gland: a morphological study in mice. *Arch Med Res* 2005;36(04):339–343
- 20 Marmary Y, Adar R, Gaska S, et al. Correction: radiation-induced loss of salivary gland function is driven by cellular senescence and prevented by IL6 modulation. *Cancer Res* 2016;76(09):2846
- 21 O'Connell AC. Natural history and prevention of radiation injury. *Adv Dent Res* 2000;14:57–61
- 22 Henriksson R, Fröjd O, Gustafsson H, et al. Increase in mast cells and hyaluronic acid correlates to radiation-induced damage and loss of serous acinar cells in salivary glands: the parotid and submandibular glands differ in radiation sensitivity. *Br J Cancer* 1994;69(02):320–326
- 23 Stramandinoli-Zanicotti RT, Sassi LM, Schussel JL, et al. Effect of fractionated radiotherapy on the parotid gland: an experimental study in Brazilian minipigs. *Int Arch Otorhinolaryngol* 2013;17(02):163–167
- 24 Lombaert IM, Brunsting JF, Wierenga PK, Kampinga HH, de Haan G, Coppes RP. Cytokine treatment improves parenchymal and vascular damage of salivary glands after irradiation. *Clin Cancer Res* 2008;14(23):7741–7750
- 25 Aghababaei F, Hadidi M. Recent advances in potential health benefits of quercetin. *Pharmaceuticals (Basel)* 2023;16(07):1020
- 26 Saeedi-Boroujeni A, Mahmoudian-Sani MR. Anti-inflammatory potential of quercetin in COVID-19 treatment. *J Inflamm (Lond)* 2021;18(01):3
- 27 Ozyel B, Le Gall G, Needs PW, Kroon PA. Anti-inflammatory effects of quercetin on high-glucose and pro-inflammatory cytokine challenged vascular endothelial cell metabolism. *Mol Nutr Food Res* 2021;65(06):e2000777