










The Effect of Magnification on the Quality of Direct Posterior Composite Restorations and the Adjacent Sound Enamel: An *In Vitro* Study

Hemant Ramesh Chourasia¹  Kulashekar Reddy Nandalur²  Arwa Daghrely¹ 
Thilla Sekar Vinothkumar¹  Yazeed Khormi³  Abdullah Ibrahim Tawhari³  Waleed Hassan Kariri³ 

¹Department of Restorative Dental Sciences, College of Dentistry, Jazan University, Jazan, Saudi Arabia

²Department of Prosthetic Dental Sciences, College of Dentistry, Jazan University, Jazan, Saudi Arabia

³College of Dentistry, Jazan University, Jazan, Saudi Arabia

Address for correspondence Hemant Ramesh Chourasia, BDS, MDS, Department of Restorative Dental Sciences, College of Dentistry, Jazan University, Jazan 45142, Saudi Arabia (e-mail: drhemantrchourasia@gmail.com).

Eur J Gen Dent 2025;14:154–160.

Abstract

Objective This study aimed at comparatively assessing the effect of different magnification levels on the immediate postoperative quality of class I direct posterior composite restorations and the adjacent sound enamel.

Materials and Methods Following the modified Consolidated Standards of Reporting Trails (CONSORT) guidelines for *in vitro* studies, 30 noncarious maxillary human molars were selected. Standardized class I tooth preparation was done in all the teeth. They were randomly divided into three groups: unaided vision, magnifying loupe (3× magnification), and dental operating microscope (7.5× magnification). Each group underwent direct composite restoration, and the restored samples were evaluated for anatomic contour, surface texture, marginal integrity, excess material, and scratching of the adjacent sound enamel.

Statistical analysis The non-parametric Kruskal-Wallis test, followed by the post-hoc Mann-Whitney test were employed.

Results Statistical analysis revealed no significant differences in anatomic contour, surface texture, marginal integrity, or excess material among the three groups. However, a notable difference was observed in the scratching of adjacent sound enamel, with the unaided vision group exhibiting significantly higher levels than the microscope group ($p = 0.022$).

Conclusion Direct composite restorations performed without magnification resulted in significantly higher adjacent sound enamel scratching than microscope-assisted procedures. The use of a dental operating microscope may minimize this risk, emphasizing its potential benefits in composite restorations.

Keywords

- ▶ direct composite restorations
- ▶ dental loupes
- ▶ dental operating microscope
- ▶ magnification

Introduction

Dental caries remains a prevalent oral health issue globally, affecting individuals of all ages.¹ Caries polarization is a global phenomenon, characterized by a decrease in prevalence in developed nations and an increase in less-developed countries. Moreover, this trend is reaching epidemic proportions in

countries with emerging economies.² The management of dental caries often involves the use of restorative materials to repair and restore the affected teeth to their normal function and aesthetics.³ Among the various restorative options available, direct composite restorations (DCRs) have gained widespread acceptance because of their aesthetic appeal, conservative nature, and adhesive properties.⁴

article published online
October 4, 2024

DOI <https://doi.org/10.1055/s-0044-1791792>.
ISSN 2320-4753.

© 2024. The Author(s).

This is an open access article published by Thieme under the terms of the Creative Commons Attribution License, permitting unrestricted use, distribution, and reproduction so long as the original work is properly cited. (<https://creativecommons.org/licenses/by/4.0/>)

Thieme Medical and Scientific Publishers Pvt. Ltd., A-12, 2nd Floor, Sector 2, Noida-201301 UP, India

Composite resins represent the most commonly utilized direct tooth-colored restorative materials, with their application in posterior teeth expanding due to advancements in mechanical performance and enhanced wear resistance.⁵ DCRs involve the placement of tooth-colored resin-based materials directly onto the tooth surface to restore form, function, and aesthetics.⁴ The success and longevity of DCRs are influenced by several factors including restoration quality, marginal adaptation, surface texture (ST), and anatomic contour (AC).⁶ Achieving optimal outcomes in DCRs requires meticulous attention to detail, precise techniques, and adherence to established clinical protocols.⁷

In recent years, there has been growing interest in the use of magnification aids, such as dental loupes and operating microscopes in restorative dentistry.⁸ Magnification aids, such as loupes and microscopes, offer clinicians enhanced visualization of the operative field, enabling them to perform procedures with greater precision and accuracy.⁹ By magnifying the operative field, these devices allow for better identification of tooth structures, carious lesions, and other clinical landmarks, facilitating more conservative and minimally invasive treatment approaches.¹⁰ The use of magnification loupes influences restoration in all its aspects and greatly reduces cavity marginal and surface irregularities.¹¹ Consequently, constant and sustained use of these instruments in clinical practice yields excellent results.

Despite the potential benefits of magnification in restorative dentistry, limited research has been conducted to evaluate its effect on the quality and outcomes of DCRs, particularly in a comparative context. While anecdotal evidence suggests that magnification aids may improve procedural efficiency and clinical outcomes, empirical data supporting these claims are scarce.¹² Therefore, there is a need for well-designed studies to assess the efficacy of magnification in enhancing the quality of DCRs and to compare their effectiveness with traditional unaided vision techniques.

The purpose of this study was to comparatively evaluate the effect of magnifications on the quality of class I DCRs. Specifically, the study aimed to assess and compare the outcomes of DCRs performed under unaided vision, a magnifying loupe at 3× magnification, and a dental operating microscope at 7.5× magnification. The evaluation parameters included AC, ST, marginal integrity (MI), excess material (EM), and scratching of the adjacent sound enamel (ASE).

The rationale for comparing different magnification levels lies in the need to identify the optimal magnification setting that provides the greatest benefits in terms of restoration quality. By systematically evaluating the outcomes of DCRs performed under different magnification conditions, this study sought to provide evidence-based guidance to clinicians regarding the use of magnification aids in restorative dentistry.

Materials and Methods

The present study used the modified Consolidated Standards of Reporting Trials (CONSORT) guidelines specifically tailored

for *in vitro* investigations. Ethical approval for the study protocol was obtained from the Scientific Research Unit of the College of Dentistry, Jazan University (reference number: CODJU-23271). The sample comprised 30 noncarious maxillary human molars extracted for periodontal or surgical reasons, which were carefully selected for inclusion. The sample size determination was guided by a prior reference article, wherein an effect size of 1.4141 was calculated, considering an α error probability of 5% and a power requirement of 80%. A minimum sample size of 10 teeth per group was established to achieve adequate statistical power, with the power analysis conducted at a 95% confidence interval using the G Power software.

After extraction, the teeth were thoroughly cleaned and sterilized before being mounted in plaster blocks for experimental purposes. The standard class I tooth preparation was done using an air turbine high-speed handpiece (LUX E25L; EXPERTmatic, Kavo, Biberach, Germany) at 300,000 rpm under copious air–water coolant spray and straight cylindrical (835–014M) medium grit diamond abrasive (SS White Dental, New Jersey, United States). Notably, cavity preparation entailed extending half of each cusp, encompassing the oblique ridge, while preserving a 2-mm healthy marginal ridge and ensuring a minimum occlusal depth of 2 mm (→Fig. 1A). Following preparation, the teeth were stratified into three distinct groups, each comprising 10 specimens:

- Group I: DCRs performed with unaided vision.
- Group II: DCRs performed under 3× magnifying loupe.
- Group III: DCRs performed under the dental operating microscope at a magnification of 7.5 × .

Group I

The prepared cavities underwent a standardized treatment regimen, beginning with the application of etching gel (Scotch bond Universal etchant, 3M ESPE, St. Paul, MN, United States), containing 32% phosphoric acid. Etching was performed for 30 seconds in the enamel and 15 seconds in the dentin. Subsequently, the etchant was meticulously rinsed with water for 20 seconds and air dried. Following etching, two coats of bonding agent (Adper Single Bond, 3M ESPE) was uniformly applied using a micro-brush for 20 seconds, followed by gentle air drying for 5 seconds, and light curing for 10 seconds. The cavities were restored using a universal restorative composite (Filtek Z250, 3M ESPE), employing the oblique layering technique (two layers, each on buccal and lingual wall) facilitated by hand instruments designed for composite material manipulation (LM-Arte Complete Set, LM Dental, Finland). Light curing was conducted for 5 seconds between each composite increment with a final curing duration of 20 seconds. Sufficient care was exercised to avoid any excess flash of composite on the ASE. The restorations were initially contoured using a flame-shaped superfine diamond bur (368–016 SF-FG) from the composite finishing kit (NTI-Kahla GmbH, Kahla, Germany), followed by meticulous finishing and polishing using silicon carbide and aluminum oxide stones sourced from the composite finishing and polishing kit (Shofu Dental Corporation, Kyoto, Japan). The

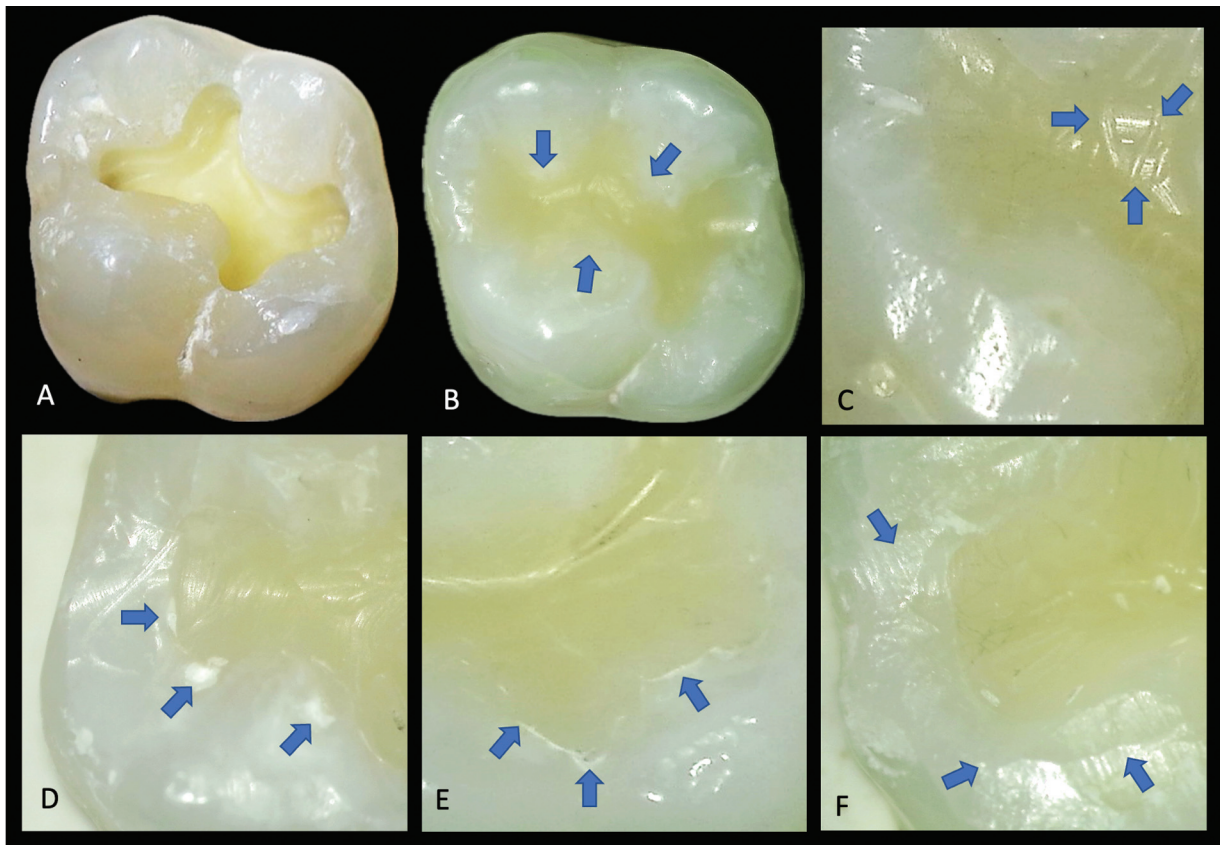


Fig. 1 Representative sample images. (A) Class I cavity preparation. (B) Anatomic contour score 1. (C) Surface texture score 2. (D) Marginal integrity score 2. (E) Excess material score 2. (F) Adjacent sound enamel score 2.

finishing and polishing were kept to a minimum to avoid any inadvertent damage to the adjacent enamel and margins.

Group II

The entire restorative procedure including finishing and polishing was done under 3× magnifying loupe (Zumax Medical Co., Ltd. China) following the same protocol as in group I.

Group III

The restorative procedure including finishing and polishing was completed under the dental operating microscope (Zeiss OPMI pico, Carl Zeiss Meditec AG, Jena, Germany) at a magnification of 7.5× following the same protocol as in group I. An orange light (blue light filtered) was used to prevent the light curing of composite resin during adaptation, compaction and contouring of resin composite.

Each tooth was restored within 30 minutes at elbow height similar to the average distance between patient and clinician in clinics. The entire tooth preparation, restoration, finishing, and polishing procedure was performed by a single operator (H.R.C.) with experience in restorative dentistry for more than 20 years and handling microscope and magnification loupe for 15 years.

Evaluation of samples: The evaluation of samples involved a systematic process overseen by the principal investigator. Sequential coding was applied to the prepared samples, ensuring the concealment of the allocation sequence from the observers. A panel of five experienced

faculty members specializing in restorative dental sciences, excluding the principal investigator, participated as blinded observers in evaluating the prepared samples. Before commencing the evaluation, the principal investigator conducted a thorough review of the evaluation guidelines with each observer, ensuring consensus on criteria, scoring parameters, and evaluation characteristics. Subsequently, each sample underwent independent evaluation by the observers, and the resulting assessments were meticulously tabulated with the assistance of a dental assistant.

Evaluation parameters: The evaluation process encompassed five distinct criteria, with the initial three criteria—namely, “AC,” “ST,” and “MI”—adopted from the modified version of Ryge criteria for direct restoration evaluation. Additionally, the assessment of “EM” adhered to the criteria established by Bud et al.¹⁶ Furthermore, a novel criterion, “ASE,” was introduced to assess the inadvertent scratching of the enamel that might occur during the finishing and polishing stages of the restoration process. Each criterion was evaluated, with scores ranging from 1 to 3, as outlined in ►Table 1. The restored samples were examined using a sharp dental explorer under an operating microscope (Zeiss OPMI Pico; Carl Zeiss Meditec AG). A magnification level of 12.5× was employed for evaluating all criteria except for the ASE, for which a higher magnification of 20× was utilized (►Fig. 1B–1F).

Statistical analysis was conducted utilizing SPSS version 23.0 (SPSS, IBM Corp., Armonk, NY, United States), employing

Table 1 Modified scoring criteria for evaluating the quality of direct composite restorations and adjacent sound enamel

Criteria	Score	Characteristics
Anatomic contour (AC)	1	Restoration morphology accurately respects/continues with the tooth morphology
	2	Restoration morphology partially respects/continues with the tooth morphology
	3	Restoration morphology does not respect/continues with the tooth morphology
Surface texture (ST)	1	Smooth surface
	2	Slightly rough or pitted; can be refinished
	3	Deeply rough or pitted; cannot be refinished
Marginal integrity (MI)	1	Excellent continuity at resin–tooth interface; explorer does not catch
	2	Explorer catches; slight crevice margin; dentin not exposed
	3	Obvious crevice at margin; dentin exposed
Excess material (EM)	1	No excess material present outside the restoration
	2	Excess material present on less than half of the restoration contour
	3	Excess material present on more than half of the restoration contour
Adjacent sound enamel (ASE)	1	Completely intact with no scratching of enamel
	2	Slight scratching of enamel
	3	Extensive scratching of enamel

the nonparametric Kruskal–Wallis test, followed by the post hoc Mann–Whitney *U* test. A significance level of 95% was established, with $p < 0.05$ deemed statistically significant. Furthermore, inter-rater reliability was assessed by computing the intraclass correlation coefficient.

Results

► **Table 2** presents the comparison of dental restoration quality among three groups: group 1 (unaided vision), group 2 (magnifying loupe), and group 3 (microscope). The variables assessed include AC, ST, MI, EM, and scratching of ASE.

For AC, no significant differences were observed among the three groups ($p > 0.05$). Similarly, ST, MI, and EM also did not show significant differences between the groups ($p > 0.05$).

However, scratching of ASE exhibited a significant difference between the groups ($p = 0.022$). Specifically, the unaided vision group (group 1) had significantly higher scratching of ASE compared with the microscope group (group 3; $p = 0.022$). No significant differences were observed between the unaided vision group and the magnifying loupe group (group 2), nor between the magnifying loupe and microscope group ($p > 0.05$).

The median scores of evaluated samples for AC were similar for all three groups (► **Fig. 2**). Regarding ST, group III showed better median scores than groups I and II (► **Fig. 3**). In terms of MI, group II reported better median scores than groups I and III (► **Fig. 4**). Concerning EM, group III showed better median scores than groups II and I, and group II was better than group I (► **Fig. 5**). The median scores for ASE were similar for groups II and III, which were better than group I (► **Fig. 6**).

The intraclass correlation coefficient showed moderate agreement between the raters for AC and EM, whereas there was good agreement for ST, MI, and ASE (► **Table 3**).

Discussion

The term “restoration” refers to the process of replacing the structure and functionality of a damaged tooth with a restorative material. Achieving optimal form and function involves preparing the tooth to accommodate the placement of the restorative material or materials.¹³ The present study compared the outcome of DCRs performed under unaided vision, 3× magnifying loupe, and dental operating microscope at a magnification of 7.5× on extracted teeth. The standardized class I cavities were prepared, and the restorative procedure was performed within the specified time duration for all three groups. During evaluation, a single-blind study protocol was implemented to remove the possibility of bias. Five experienced observers independently evaluated the prepared samples according to the modified Ryge criteria and an additional evaluation criterion to examine the ASE was introduced.

According to the results of the present study, no significant differences were noted between the three groups in terms of AC, ST, MI, and EM. Hence, the null hypothesis that magnification may improve the outcome of DCR has been rejected. However, a notable difference was found regarding scratching of ASE. Specifically, the unaided vision group exhibited significantly higher scratching compared with the microscope group ($p = 0.022$). This disparity underscores the potential benefit of utilizing magnification, particularly a dental operating microscope, to minimize inadvertent damage to adjacent enamel during restoration procedures. The reduced scratching observed in the microscope group can be attributed to several factors facilitated by higher magnification. First, enhanced visibility provided by the microscope enables clinicians to precisely control instrument movements, leading to more accurate restoration procedures with minimal enamel abrasion.¹⁴ Additionally, the increased

Table 2 Showing the median, range, and standard deviation of the three groups and their comparative analysis

Variable	Group 1 (n = 10)			Group 2 (n = 10)			Group 3 (n = 10)			p value [§]	Group 1 vs. 2 p value ^b	Group 1 vs. 3 p value ^b	Group 2 vs. 3 p value ^b
	Median	Range	Mean ±SD	Median	Range	Mean ±SD	Median	Range	Mean ±SD				
AC	1	1-2	1.40 0.516	1	1-2	1.30 0.483	1	1-2	1.10 0.316	0.316	0.131	0.276	
ST	2	1-2	1.60 0.516	2	1-2	1.60 0.516	1	1-2	1.30 0.483	0.313	0.189	0.189	
MI	2	1-2	1.70 0.483	1.5	1-2	1.50 0.527	2	1-2	1.60 0.516	0.668	0.648	0.661	
EM	2	1-2	1.60 0.516	1.5	1-2	1.50 0.527	1	1-2	1.20 0.422	0.182	0.075	0.170	
ASE	2	1-2	1.60 0.516	1	1-2	1.40 0.516	1	1-2	1.10 0.316	0.072	0.022 ^c	0.131	

Abbreviations: AC, anatomic contour; ASE, adjacent sound enamel; EM, excess material; MI, marginal integrity; ST, surface texture.

^aKruskal-Wallis test.

^bMann-Whitney U test; p > 0.05; not significant.

^cp < 0.05; significant.

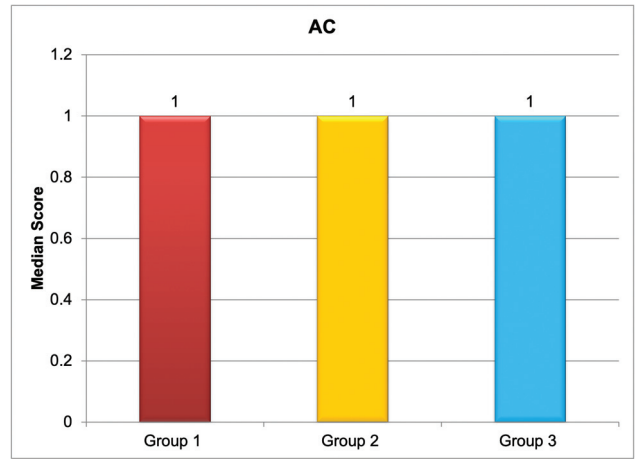


Fig. 2 Median score values of the anatomic counter (AC).

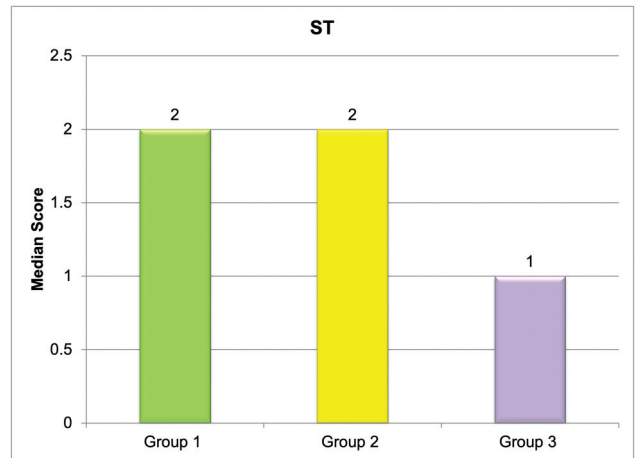


Fig. 3 Median score values of surface texture (ST).

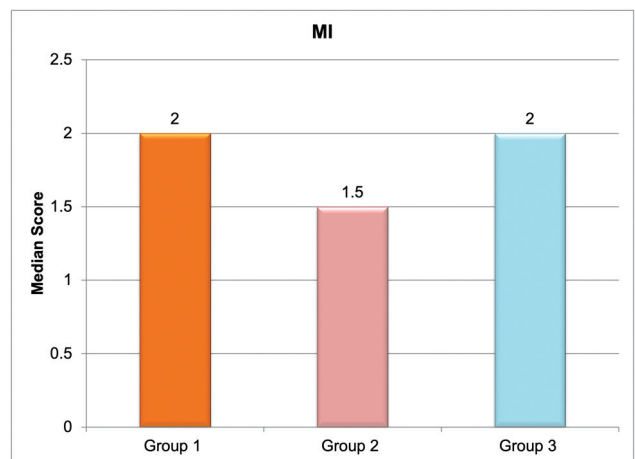


Fig. 4 Median score values of marginal integrity (MI).

magnification allows for better discrimination between sound enamel and composite material, reducing the likelihood of unintentional enamel scratches.¹⁵ Furthermore, the ergonomic design of dental operating microscopes promotes optimal working posture, minimizing hand fatigue and

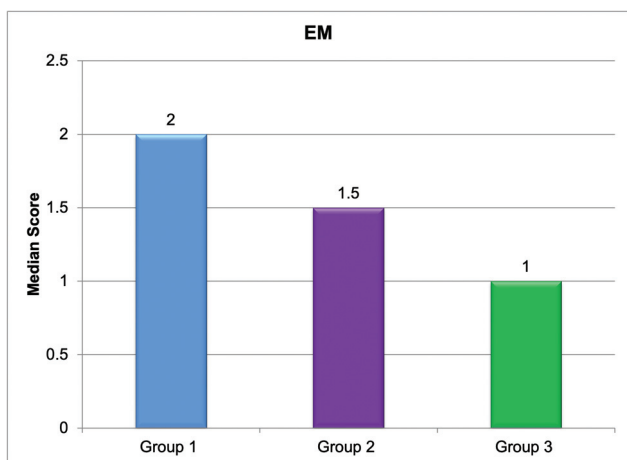


Fig. 5 Median score values of excess material (EM).

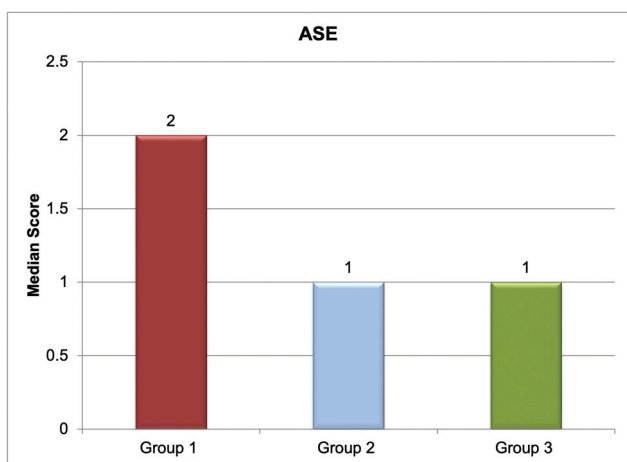


Fig. 6 Median score values of adjacent sound enamel (ASE).

tremors, which can contribute to procedural precision and reduced enamel damage.⁹

Our study, investigating the impact of different magnification levels on DCRs, aligns with findings from a study by Bud et al. Both studies highlight the benefits of magnification, particularly dental operating microscopes, in improving restoration quality. While our study found significantly lower scratching of adjacent enamel with microscope use, Bud et al observed improvements in “marginal adaptation integrity” and “EM” with magnification. Despite slight differences in outcomes, there is consensus that the integration of

magnification aids in routine clinical practice to enhance restoration outcomes. Future research could explore nuances in magnification levels and associated practical considerations.¹⁶ Mamoun reported that the use of 6× to 8× magnification by binocular surgical loupes or the operating microscope resulted in a composite restoration that was perfect at the initial placement and free of secondary caries or marginal staining at follow-up visits.¹⁷

The differences in the findings of the previous studies and the present research may be attributed to the methodology, particularly operating time. The present study used a standardized time duration of 30 minutes in all three groups, which may not be sufficient while working with an operating microscope. Additionally, during sample evaluation a single-blind protocol was implemented, avoiding the biased observations.

Overall, the findings of this study align with previous research highlighting the benefits of magnification aids in restorative dentistry. For instance, a systematic review by Low et al emphasized the positive impact of dental loupes and operating microscopes on clinical outcomes, including improved cavity preparation, restoration placement, and marginal adaptation.⁸ Similarly, a review by Bud et al demonstrated superior marginal adaptation and surface finish of composite restorations performed under magnification compared with those done with unaided vision.⁹ Thus, the current study adds to the existing body of evidence supporting the efficacy of magnification in enhancing the quality of dental restorations.

Moreover, the observed lack of significant differences in AC, ST, MI, and EM among the three groups underscores the high level of proficiency and technique sensitivity required for successful DCRs, regardless of magnification level. It suggests that, while magnification aids can enhance procedural precision and reduce enamel damage, they may not necessarily lead to superior outcomes in all aspects of restoration. Factors such as operator experience, material selection, and technique mastery remain crucial determinants of restoration quality.¹⁸

The present study introduced a new parameter “ASE” while evaluating DCR. The literature search revealed no published research on the effect of magnification on the ASE; thus, the present research is unique in its kind. The results of the current study reported significantly higher scratching of ASE in the unaided vision group compared with the operating microscope group. The scratches on the ASE

Table 3 Intraclass correlation coefficient (ICC) and inter-observers agreement

Variable	ICC	95% CI	p value	Agreement
AC	0.716	0.518–0.849	<0.001	Moderate
ST	0.829	0.711–0.909	<0.001	Good
MI	0.844	0.736–0.917	<0.001	Good
EM	0.691	0.481–0.835	<0.001	Moderate
ASE	0.794	0.652–0.891	<0.001	Good

Abbreviations: AC, anatomic contour; ASE, adjacent sound enamel; EM, excess material; MI, marginal integrity; ST, surface texture; CI, confidence interval.

may favor plaque and food accumulation, which can lead to recurrent caries and an ultimate failure in the restoration.^{19,20} Thus, recommendations are made to use the operating microscope during composite restoration to avoid/minimize undue scratching of the ASE.

Strengths: The present study used sequential coding and the allocated sequences were concealed from the observers, thus strengthening the validity of the findings by minimizing bias and allowing for direct comparison between different magnification levels. Furthermore, adherence to the modified CONSORT guidelines for *in vitro* studies enhances the transparency and reproducibility of the research methodology.²¹

Limitations: First, the study utilized extracted human molars, which may not fully replicate the clinical conditions encountered *in vivo*, potentially limiting the generalizability of the findings. Second, the sample size of 30 teeth, while sufficient for detecting significant differences, may still be relatively small, necessitating cautious interpretation of the results. Additionally, the evaluation of restoration outcomes by five experienced observers introduces the possibility of inter-observer variability, albeit efforts were made to mitigate this through pre-evaluation training and consensus building.

Future research in this area could focus on expanding the sample size, selecting large class I and other types of cavities, and including other types of teeth to enhance the generalizability of the findings. Longitudinal studies tracking the performance of DCRs over time under different magnification levels could provide valuable insights into the long-term durability and clinical outcomes of restorations. Moreover, investigations into the cost-effectiveness of incorporating magnification aids into routine clinical practice could inform decision-making among dental practitioners.

Conclusion

Within the limitations of the study, it can be concluded that DCRs performed with unaided vision showed significantly higher scratching of ASE compared with those under the dental operating microscope at a magnification. This study contributes to the growing body of evidence supporting the beneficial effects of magnification aids, particularly dental operating microscopes, on the quality of DCRs. The findings underscore the importance of utilizing magnification to minimize enamel damage and optimize clinical outcomes in restorative dentistry. Incorporating magnification aids into routine clinical practice has the potential to enhance the precision, efficacy, and longevity of dental restorations, ultimately benefiting patient care and satisfaction.

Funding

None.

Conflict of Interest

None declared.

References

- Miglani S. Burden of dental caries in India: current scenario and future strategies. *Int J Clin Pediatr Dent* 2020;13(02):155–159
- Bhardwaj VK, Negi N, Fotedar S, Kaundal JR. Does the nature of diet consumed have an association with the prevalence of dental caries? *Eur J Gen Dent* 2013;2(03):332
- Warreth A. Dental caries and its management. *Int J Dent* 2023;2023:9365845
- Chandrasekhar V, Rudrapati L, Badami V, Tummala M. Incremental techniques in direct composite restoration. *J Conserv Dent* 2017;20(06):386–391
- Reddy P, Jain V, Kaushik M, et al. Assessment of marginal integrity of proximal composite resin restorations performed with or without magnification. *J Clin Diagn Res* 2017;11(12):ZC01–ZC04
- Lutz F, Krejci I, Barbakow F. Quality and durability of marginal adaptation in bonded composite restorations. *Dent Mater* 1991;7(02):107–113
- Lempel E, Lovász BV, Bihari E, et al. Long-term clinical evaluation of direct resin composite restorations in vital vs. endodontically treated posterior teeth: retrospective study up to 13 years. *Dent Mater* 2019;35(09):1308–1318
- Low JF, Dom TNM, Baharin SA. Magnification in endodontics: a review of its application and acceptance among dental practitioners. *Eur J Dent* 2018;12(04):610–616
- Bud MG, Pop OD, Cîmpean S. Benefits of using magnification in dental specialties - a narrative review. *Med Pharm Rep* 2023;96(03):254–257
- Blumer S, Zidani S, Peretz B, et al. Dental loupe's role in detection of caries of molars in children by student and dentists. *Children (Basel)* 2023;10(06):1050
- Lo Giudice G, Lo Giudice R, Matarese G, et al. Evaluation of magnification systems in restorative dentistry. An *in-vitro* study. *Dent Cadmos* 2015;83:296–305
- Aldosari MA. Dental magnification loupes: an update of the evidence. *J Contemp Dent Pract* 2021;22(03):310–315
- Bansal K, Gupta S, Nikhil V, Jaiswal S, Jain A, Aggarwal N. Effect of different finishing and polishing systems on the surface roughness of resin composite and enamel: An *In vitro* profilometric and scanning electron microscopy study. *Int J Appl Basic Med Res* 2019;9(03):154–158
- Yu H, Zhao Y, Li J, et al. Minimal invasive microscopic tooth preparation in esthetic restoration: a specialist consensus. *Int J Oral Sci* 2019;11(03):31
- Neuhaus KW, Jost F, Perrin P, Lussi A. Impact of different magnification levels on visual caries detection with ICDAS. *J Dent* 2015;43(12):1559–1564
- Bud M, Zlávog M, Jitaru Ş, Korkut B, Spataru S, Delean A. The outcome of direct composite restorations using the dental operating microscope. *Med Pharm Rep* 2021;94(04):477–482
- Mamoun J. Preparing and restoring composite resin restorations. The advantage of high magnification loupes or the dental surgical operating microscope. *N Y State Dent J* 2015;81(04):18–23
- Peumans M, Van Meerbeek B, Lambrechts P, Vanherle G. The 5-year clinical performance of direct composite additions to correct tooth form and position. I. Esthetic qualities. *Clin Oral Investig* 1997;1(01):12–18
- Sarafopoulou S, Zafeiriadis AA, Tsolakis AI. Enamel defects during orthodontic treatment. *Balk J Dent Med* 2018;22(03):64–73
- Kandikatla P, Polinetti P, Ushasree R, Chiluvuri PK. Materials and methods used for adhesive remnant removal and polishing of enamel after orthodontic treatment: a review. *Int J Dent Mater* 2022;04(03):62–68
- Schulz KF, Altman DG, Moher DCONSORT Group. CONSORT 2010 statement: updated guidelines for reporting parallel group randomised trials. *BMJ* 2010;340:c332