



# Is Trochlear Dysplasia Associated with a High Prevalence of Repaired Anterior Medial Portal Lesions in Anterior Cruciate Ligament-Deficient Knees?

Naveen Kumar<sup>1</sup> Pradip Ghimire<sup>1</sup> Shrikant Shukla<sup>1</sup> Pradeep Kumar Meena<sup>2</sup> Sudhir Saxena<sup>3</sup>  
Sonal Saran<sup>1</sup>

<sup>1</sup>Department of Diagnostic and Interventional Radiology, All India Institute of Medical Sciences Rishikesh, Rishikesh, Uttarakhand, India

<sup>2</sup>Department of Orthopedics, All India Institute of Medical Sciences Rishikesh, Rishikesh, Uttarakhand, India

<sup>3</sup>Department of Radiology, Graphic Era Institute of Medical Sciences, Dehradun, Uttarakhand, India

Address for correspondence Sonal Saran, MD, Department of Diagnostic and Interventional Radiology, All India Institute of Medical Sciences Rishikesh, Rishikesh, Uttarakhand 249203, India (e-mail: sonalsaranmalik@gmail.com).

Indian J Radiol Imaging 2025;35:272–279.

## Abstract

**Introduction** Meniscal tears, especially in the medial meniscus, are common in anterior cruciate ligament (ACL) injuries. Repaired anterior medial portal (RAMP) lesions, specific meniscal injuries associated with ACL ruptures, affect the peripheral attachment of the posterior horn of the medial meniscus. While the relationship between femoral trochlear morphology and ACL tears is established, its association with RAMP lesions remains unexplored. This study investigates the association between femoral trochlear morphology and RAMP lesions in ACL-deficient knees using magnetic resonance imaging (MRI) and evaluates MRI's accuracy against arthroscopy. **Materials and Methods** This hospital-based, cross-sectional observational study was conducted in a tertiary care center over 18 months. It included 126 adult patients who underwent arthroscopic ACL reconstruction and had preoperative MRI. Variables included age, gender, body mass index, trauma nature, and various MRI parameters, including femoral trochlear morphology and presence of RAMP lesions. MRI findings were compared to arthroscopic findings to evaluate diagnostic accuracy.

## Keywords

- ▶ RAMP lesions
- ▶ ACL deficiency
- ▶ femoral trochlear morphology
- ▶ medial tibial slope
- ▶ MRI
- ▶ arthroscopy

**Results** RAMP lesions were detected in 21 participants (16.7%) via MRI and 28 participants (22.2%) via arthroscopy. MRI showed 71.4% sensitivity and 99.0% specificity for detecting RAMP lesions. No significant association was found between femoral trochlear morphology and RAMP lesions. However, medial tibial slope (TS) and posterior medial tibial bone edema (PMTBE) were significantly associated with RAMP lesions. The agreement between MRI and arthroscopy was high (Cohen's kappa = 0.773,  $p < 0.001$ ).

article published online  
October 7, 2024

DOI <https://doi.org/10.1055/s-0044-1791565>.  
ISSN 0971-3026.

© 2024. Indian Radiological Association. All rights reserved.  
This is an open access article published by Thieme under the terms of the Creative Commons Attribution-NonDerivative-NonCommercial-License, permitting copying and reproduction so long as the original work is given appropriate credit. Contents may not be used for commercial purposes, or adapted, remixed, transformed or built upon. (<https://creativecommons.org/licenses/by-nc-nd/4.0/>)  
Thieme Medical and Scientific Publishers Pvt. Ltd., A-12, 2nd Floor, Sector 2, Noida-201301 UP, India

**Conclusion** This study found no significant association between femoral trochlear morphology and RAMP lesions in ACL-deficient knees. Instead, medial TS and PMTBE were significant predictors. MRI proved to have high specificity but moderate sensitivity compared to arthroscopy.

## Introduction

The medial and lateral meniscus are key components of the knee joint, essential for stability, load distribution, and reducing friction during movement. The crescent-shaped medial meniscus, made of fibrocartilaginous tissue, lies between the femur and tibia, optimizing contact mechanics and joint stability. It helps control excessive joint movement but is prone to injuries and degeneration. Meniscal tears and degeneration can cause various symptoms and impairments, necessitating careful clinical management.<sup>1</sup> In 1988, Strobel identified a specific meniscal injury associated with anterior cruciate ligament (ACL) rupture, termed the repaired anterior medial portal (RAMP) lesion. This injury affects the “peripheral attachment of the posterior horn of the medial meniscus (PHMM)” and features longitudinal vertical/oblique peripheral tears, potentially resulting in meniscocapsular or meniscotibial disruption. In 2016, Thauinat et al categorized RAMP lesions into five types: “meniscocapsular tear, partial superior tear, partial inferior tear, complete tear, and double tear.” Recently, Greif et al proposed modifications to Thauinat et al’s original arthroscopic classification.<sup>2–4</sup>

The posterior segment of the medial meniscus acts as a secondary stabilizer for anterior tibial translation and external rotational stability. The healing of this segment, particularly in RAMP lesions, influences anterior knee stability following ACL reconstruction, potentially preventing degenerative changes like osteoarthritis and reducing the risk of ACL graft failure. Although the need for surgical repair of meniscal RAMP lesions is debated, identifying and repairing these lesions are crucial because ACL reconstructions without addressing them may not fully restore normal knee joint mechanics.<sup>5</sup>

Standard knee arthroscopy utilizes anterolateral and anteromedial portals to avoid the neurovascular structures in the popliteal fossa, which present a higher risk of injury and complications. However, these portals may leave the posteromedial compartment of the knee as a potential blind spot. To thoroughly assess meniscal RAMP lesions, a systematic approach is required, including history, clinical examination, magnetic resonance imaging (MRI), and arthroscopic exploration of the posteromedial compartment using a transnotch approach.<sup>6–9</sup>

RAMP lesions frequently occur alongside ACL injuries, with prevalence rates ranging from 9 to 42%.<sup>10</sup> Previous studies have identified various risk factors for RAMP lesions in ACL tear patients, like chronicity, posterior medial tibial bone edema (PMTBE), “steeper medial tibial and meniscal

slopes,” and “gradual lateral tibial slope (TS).”<sup>11–13</sup> Additionally, studies have shown associations between ACL tears and femoral trochlear morphology parameters such as “trochlear depth, facet asymmetry, trochlear sulcal angle, and lateral inclination angle.”<sup>14–17</sup> However, no research has previously explored the relationship between femoral trochlear morphology factors and RAMP lesions. In this study, we aimed to investigate the association between femoral trochlear morphology parameters and RAMP lesions in ACL-deficient knees on MRI. Additionally, we aimed to identify other anthropometric factors associated with RAMP lesions on MRI and to evaluate the accuracy of MRI in identifying RAMP lesions by comparing it to arthroscopy. We hypothesized that trochlear dysplasia is significantly associated with the presence of RAMP lesions in ACL-deficient knees.

## Materials and Methods

### Study Design

Hospital-based, cross-sectional observational study.

### Study Setting

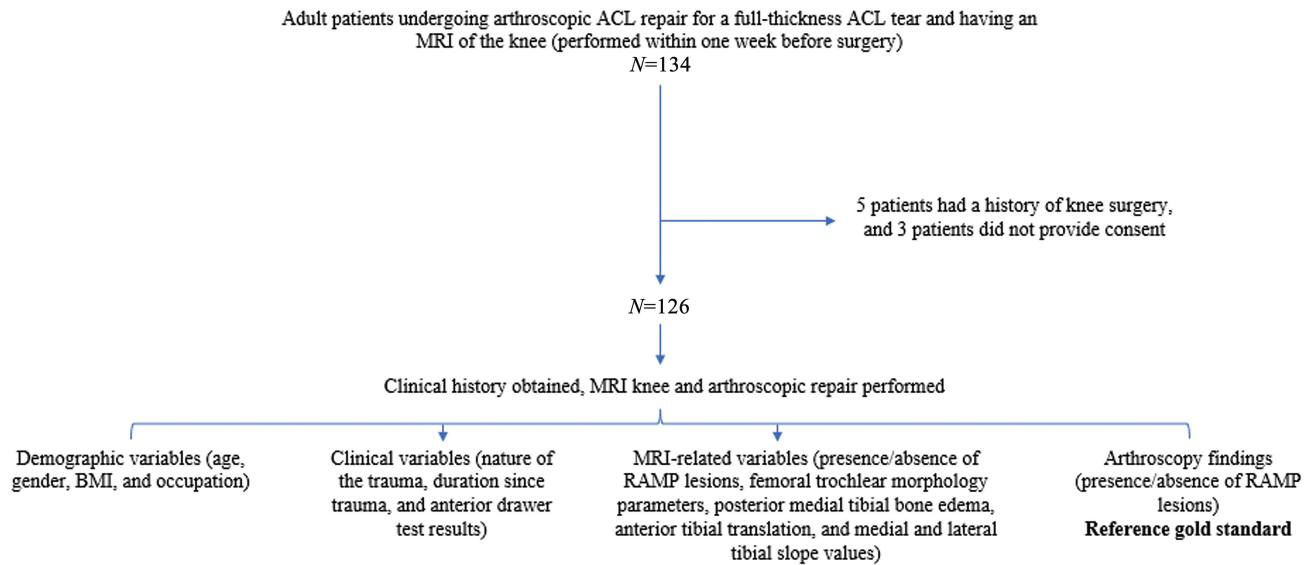
This prospective study was conducted in the department of diagnostic and interventional radiology in collaboration with the department of orthopedics at a tertiary care referral center over 18 months (April 2022–October 2023) following approval from the institute’s research and ethics committee.

### Participants

All adult patients who underwent arthroscopic ACL reconstruction for a full-thickness ACL tear at the institute and had an MRI of the knee (performed within 1 week before surgery) were recruited for the study. Exclusion criteria included patients who did not consent to participate and those with a previous history of knee surgery. During the study period, 134 consecutive adult patients had arthroscopic ACL reconstruction and MRI of the knee. However, 5 patients were excluded due to a history of knee surgery, and 3 patients did not provide consent, resulting in a final sample size of 126 patients.

### Variables

All scans were performed using a 3.0 T GE Discovery 750 W or a 1.5 T Magnetom AERA system with an extremity coil. Imaging sequences included “turbo spin-echo (TSE) proton density-weighted (PDWI), TSE fat-saturated T2-weighted (T2WI), and T1-weighted imaging” in various planes. Repetition times were 3,000 to 4,000 ms (PDWI) and 3,000 to 5,000 ms (T2WI), with echo times of 10 to 30 and 100 ms,



**Fig. 1** Flow diagram depicting study methodology.

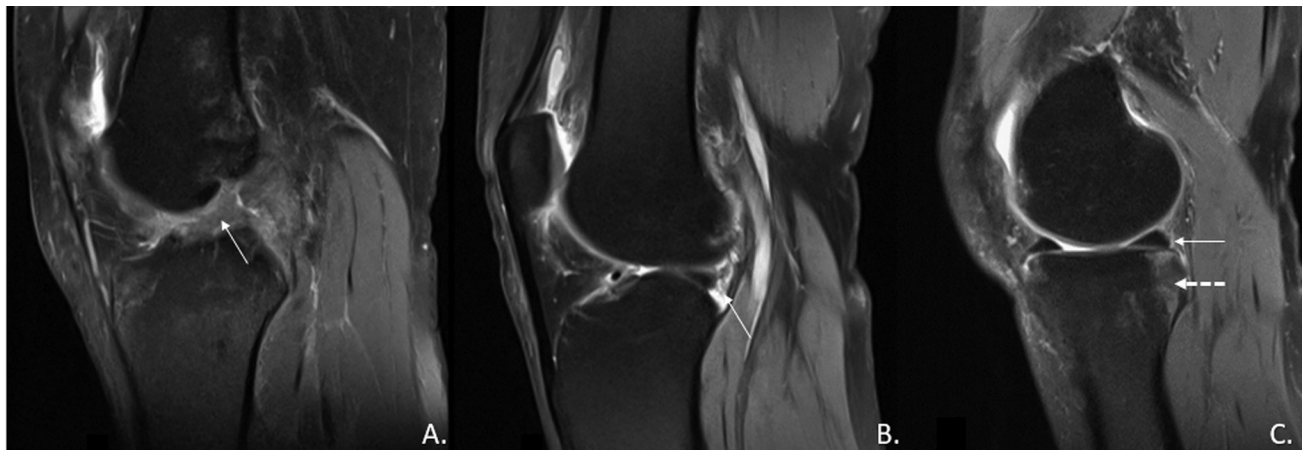
respectively. Other parameters included matrix sizes of  $384 \times 384$  (axial),  $448 \times 448$  (coronal),  $320 \times 320$  (sagittal), a 16-cm field of view, 1.5 mm slice thickness with no spacing, and an acquisition number of 1.

The MRI scans were initially interpreted by a resident (N.K.) and verified by a musculoskeletal radiologist (S.S.) with 10 years of experience in reading knee MRIs. The readers were blinded to the patients' clinical and demographic information, eliminating bias from arthroscopic findings as the MRI reports were finalized beforehand. Demographic variables included age, gender, body mass index (BMI), and occupation. Clinical variables included the nature of the trauma (contact vs. noncontact), duration since trauma, and anterior drawer test results. MRI-related variables included the presence/absence of RAMP lesions, femoral trochlear morphology parameters (depth, facet asymmetry, sulcal angle, lateral inclination angle), PMTBE, anterior tibial translation, and medial and lateral TS values. During arthroscopic ACL reconstruction, the

presence/absence of RAMP lesions was documented as the reference standard (**Fig. 1**).

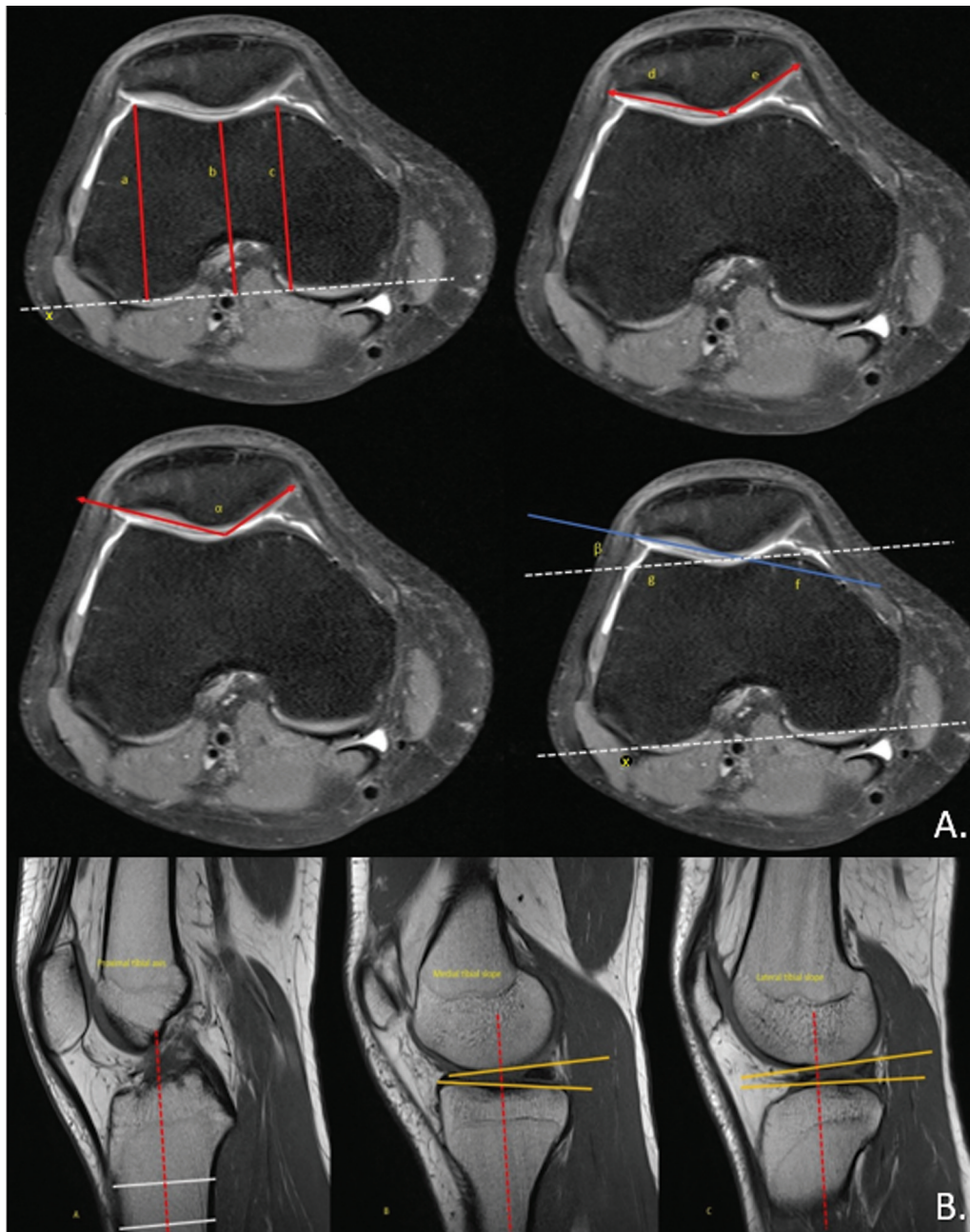
#### Data Sources/Measurement

The MRI criteria for diagnosing RAMP lesions included identifying high signal intensity at the capsular margin or separation at the meniscocapsular junction of the PHMM on sagittal images (**Fig. 2**). Knee arthroscopy was then performed using standard anterolateral and anteromedial portals, with systematic inspection of the posteromedial compartment via direct visualization through the intercondylar notch. The MRI findings were correlated with arthroscopic findings. Methods for measuring medial and lateral TS and femoral trochlear morphology parameters were adapted from previously published literature (**Fig. 3**).<sup>18,19</sup> RAMP lesions on arthroscopy were correlated for any potential association with demographic, clinical, and MRI-related variables.



**Fig. 2** Magnetic resonance imaging (MRI) of the knee (proton density fat-saturated [PDFS] sequence) in sagittal plane showing full-thickness anterior cruciate ligament (ACL) tear (arrow in A), repaired anterior medial portal (RAMP) lesion (arrows in B and C), and edema in posteromedial tibial plateau (dashed arrow in C).





**Fig. 3** The magnetic resonance imaging (MRI) of the knee utilized specific techniques to acquire femoral trochlear morphology parameters (A) and the medial and lateral tibial slope (TS) (B). (A) In the first step, the “posterior condylar axis” (line x) is established, followed by drawing “perpendicular lines from the highest points of the medial (line a) and lateral (line c) facets, as well as from the deepest point (line b) of the trochlear groove.” Subsequently, the “trochlear sulcus depth” is computed as “[ $(a + c) / 2$ ] - b.” Two parallel lines are then drawn: one along the “lateral facet of the trochlea” (line d) and the other along the “medial facet of the trochlea” (line e). The ratio of the distance between line d and line e is calculated to assess “trochlear facet asymmetry.” The angle ( $\alpha$ ) between these lines is measured to determine the “trochlear sulcus angle.” Additionally, the “lateral trochlear inclination angle” ( $\beta$ ) is determined by measuring “the angle between the lateral trochlear slope (line f) and the posterior condylar axis (line g).” (B) The measurement of medial TS and lateral TS was conducted using sagittal plane. The slopes were characterized as the angle formed between a 90-degree line intersecting the proximal tibial anatomic axis (highlighted by a red line) and a tangent line drawn along either plateau (indicated by a yellow line). To determine the anatomic axis of the tibia, two perpendicular lines encompassing the entire tibial cortex were measured (depicted by white horizontal lines). The anatomic axis was then defined as the line passing through the midpoint of these perpendicular lines (highlighted by a red dashed line).

### Statistical Methods

The data were input into an MS Excel sheet and analyzed using SPSS software, Version 27.0 for Windows. Descriptive statistics for continuous variables were presented as “means and standard deviations (SDs) or medians and interquartile

ranges (IQRs),” while “frequencies and percentages” were used for categorical variables. Comparisons between groups for continuous data were conducted using the “independent sample *t*-test for two groups” and “one-way analysis of variance for more than two groups,” followed by “Tukey’s

honestly significant difference test for post hoc analysis.” For nonnormally distributed data, nonparametric tests like the “Wilcoxon test or Kruskal–Wallis test” were employed. The “chi-squared test” was used to compare categorical data, with “Fisher’s exact test” applied when expected frequencies were low. Linear correlations between continuous variables were assessed using “Pearson’s correlation” for normally distributed data and “Spearman’s correlation” for nonnormally distributed data. The diagnostic performance of various predictors was determined by plotting the “receiver operating characteristic (ROC) curves.” Statistical significance was considered at  $p < 0.05$ .

## Results

A total of 126 adult patients meeting the eligibility criteria were recruited during the study period. In terms of RAMP lesions detected by MRI, 21 participants (16.7%; 95% confidence interval [CI]: 10.8–24.6%) tested positive, while 105 participants (83.3%; 95% CI: 75.4–89.2%) tested negative. In terms of RAMP lesions detected by arthroscopy, 28 participants (22.2%; 95% CI: 15.5–30.7%) tested positive, while 98 participants (77.8%; 95% CI: 69.3–84.5%) tested negative. The two methods agreed in 92.9% of the cases and disagreed in 7.1% of the cases. There was a statistically significant agreement between the two methods (Cohen’s kappa = 0.773,  $p \leq 0.001$ ). The sensitivity and specificity of MRI with reference to arthroscopy in detecting RAMP lesions were 71.4% (95% CI: 51–87%) and 99.0% (95% CI: 94–100%), respectively.

The cohort included 103 males (81.7%; 95% CI: 73.7–87.8%) and 23 females (18.3%; 95% CI: 12.2–26.3%) and the gender did not have any statistically significant association with RAMP lesion ( $p = 0.29$ ). The mean age of the patients was 32.19 years (SD = 10.39), with ages ranging from 14 to 61 years. Within the RAMP lesion-positive group, the mean age ( $27.96 \pm 7.74$ ) was lower than the RAMP lesion-negative group ( $33.40 \pm 10.76$ ). However, this difference did not demonstrate any statistical significance ( $p = 0.25$ ).

Among the participants, 43.7% were students, 19.8% were farmers, 15.9% were office workers, 12.7% were daily wage workers, and 7.9% were athletes. The mean BMI of the participants was 22.35 (SD = 1.98), with a median of 22.50 (IQR: 20.8–23.85) and a range of 18.16 to 26.63. Regarding injury mechanisms, 23.8% of participants experienced contact injuries, while 76.2% had noncontact injuries. For the anterior drawer test, 40.5% of participants tested positive, while 59.5% tested negative, with a mean anterior drawer value of 8.99 mm (SD = 2.09). None of the above-described variables demonstrated any statistically significant association with RAMP lesion.

The mean duration of symptoms was 54.69 days (SD = 42.73), with a median of 40.00 days (IQR: 21.25–75.75) and a range of 2 to 180 days. The duration was higher in the RAMP lesion-positive group ( $69.04 \pm 51.03$  days) than the RAMP lesion-negative group ( $50.59 \pm 39.39$  days). However, there was no statistically significant association ( $p = 0.10$ ).

The distribution of femoral trochlear morphology and other anthropometric parameters, anterior tibial translation,

and PMTBE, along with their association with RAMP lesions, are presented in ►Table 1. The variables medial TS and PMTBE were significantly associated ( $p < 0.05$ ) with RAMP lesion on arthroscopy. Other parameters, including any of the femoral trochlear morphology parameters, did not show any significant association with RAMP lesion on arthroscopy.

A comparison of the diagnostic performance of various predictors in predicting RAMP lesions is shown in ►Table 2. Medial TS significantly predicted RAMP lesions in terms of area under the ROC curve (AUROC) and diagnostic accuracy.

## Discussion

In this study, we investigated the association between femoral trochlear morphology parameters and RAMP lesions in ACL-deficient knees on MRI. Additionally, we investigated other anthropometric factors potentially associated with RAMP lesions on MRI and evaluated the accuracy of MRI in identifying RAMP lesions by comparing it to arthroscopy. Our study yielded insightful results. Though there are some published studies that identified trochlear dysplasia as a risk factor for ACL tears, no research has previously explored the relationship between femoral trochlear morphology factors and RAMP lesions. In this study, we did not find any significant association between femoral trochlear morphology parameters and RAMP lesions.

In this study, among other anthropometric parameters, such as medial TS and lateral TS values, only the variable medial TS was significantly associated with RAMP lesion on arthroscopy. Among all predictors, medial TS significantly predicted RAMP lesions in terms of AUROC and diagnostic accuracy. Tang et al identified that specific bony anatomical characteristics of the knee, particularly the morphology of the medial tibia plateau, are additional risk factors for developing RAMP lesions in ACL ruptures. D’Ambrosi et al reported an unusually high prevalence (78.1%) of RAMP lesions in ACL-deficient knees and found that the mean medial and lateral TS were both  $4.0 \pm 2.7$  and  $4.0 \pm 3.1$  degrees, respectively, and that these slopes significantly correlated with the presence of RAMP lesions. Jiang et al, in their systematic review, determined that an increased lateral posterior TS is associated with a higher risk of lateral meniscal tears and lateral meniscal posterior root tears. Similarly, an increased medial meniscal slope was linked to a higher risk of RAMP lesions. These studies collectively highlight the importance of knee morphology, particularly the TS, in the risk and occurrence of meniscal injuries, including RAMP lesions, in the context of ACL injuries.<sup>20–22</sup>

We observed that the duration of symptoms was longer in the RAMP lesion-positive group compared to the RAMP lesion-negative group, although this difference was not statistically significant. In contrast, Mahmood et al found in their study that the time from injury to surgery was significantly longer for patients with RAMP lesions than for those without.<sup>23</sup>

In this study, the presence of the anterior drawer test, anterior tibial translation, and their value did not yield any significant association with RAMP lesion. Familiari et al, in

**Table 1** Distribution of different MRI variables and their association with RAMP lesions

Variable	Parameter	RAMP lesion (arthroscopy)		Difference (95% CI)	Significance
		Positive (n = 28)	Negative (n = 98)		
Anterior tibial translation	Present	25 (89.29%)	73 (74.49%)	14.80% (-100.00% to 29.14%)	Chi-square = 1.969, p = 0.124 <sup>a</sup>
	Absent	3 (10.71%)	25 (25.51%)	-14.80% (-100.00% to -0.45%)	Chi-square = 1.969, p = 0.124 <sup>a</sup>
Anterior tibial translation value (mm)	Mean ± SD	9.96 ± 1.62	9.66 ± 1.69	0.30 (-0.46 to 1.07)	W = 1014.000, p = 0.408 <sup>b</sup>
	Median (IQR)	9.50 (8.90-10.60)	9.30 (8.90-10.00)		
Medial TS	Mean ± SD	12.62 ± 2.94	10.39 ± 1.35	2.22 (1.06-3.39)	W = 1957.500, p ≤ 0.001 <sup>b</sup>
	Median (IQR)	13.05 (10.18-14.48)	10.05 (9.40-11.38)		
Lateral TS	Mean ± SD	8.71 ± 1.25	9.13 ± 1.34	-0.42 (-0.96 to 0.13)	W = 1117.500, p = 0.136 <sup>b</sup>
	Median (IQR)	8.38 (8.02-9.45)	8.80 (8.18-10.10)		
TD (mm)	Mean ± SD	6.89 ± 1.13	7.15 ± 1.26	-0.27 (-0.77 to 0.24)	t = -1.065, p = 0.292 <sup>c</sup>
	Median (IQR)	6.85 (6.18-7.53)	7.10 (6.32-8.00)		
Facet asymmetry	Mean ± SD	0.61 ± 0.07	0.63 ± 0.08	-0.01 (-0.04 to 0.02)	W = 1259.000, p = 0.509 <sup>b</sup>
	Median (IQR)	0.61 (0.57-0.65)	0.62 (0.56-0.68)		
Trochlear sulcal angle	Mean ± SD	126.54 ± 8.96	128.86 ± 8.82	-2.32 (-6.18 to 1.54)	W = 1166.000, p = 0.227 <sup>b</sup>
	Median (IQR)	126.50 (117.75-133.25)	129.00 (124.00-135.00)		
Lateral inclination angle	Mean ± SD	19.36 ± 3.72	19.01 ± 4.73	0.36 (-1.35 to 2.06)	W = 1508.500, p = 0.373 <sup>b</sup>
	Median (IQR)	19.00 (17.00-21.85)	18.00 (15.00-21.10)		
Posterior medial tibial bone edema	Present	24 (85.71%)	26 (26.53%)	59.18% (-100.00% to 74.82%)	Chi-square = 29.445, p ≤ 0.001 <sup>a</sup>
	Absent	4 (14.29%)	72 (73.47%)	-59.18% (-100.00% to -43.55%)	Chi-square = 29.445, p ≤ 0.001 <sup>a</sup>

Abbreviations: CI, confidence interval; IQR, interquartile range; MRI, magnetic resonance imaging; RAMP, repaired anterior medial portal; SD, standard deviation; TD, trochlear depth; TS, tibial slope.

<sup>a</sup>Fisher's exact test.

<sup>b</sup>Mann-Whitney U test.

<sup>c</sup>t-Test.

**Table 2** Comparison of the diagnostic performance of various predictors in predicting RAMP lesion

Predictor	AUROC	95% CI	<i>p</i>	Sn	Sp	PPV	NPV	DA
				%				
Age (y)	0.640	0.533–0.746	0.025	79	57	34	90	62
BMI	0.562	0.453–0.67	0.323	93	32	28	94	45
Duration of symptoms (d)	0.602	0.471–0.732	0.102	54	74	38	85	70
Anterior drawer value (mm)	0.530	0.364–0.695	0.749	93	28	35	91	47
Anterior tibial translation value (mm)	0.556	0.424–0.687	0.408	44	68	32	78	62
Medial TS	0.713	0.575–0.851	0.001	57	93	70	88	85
Lateral TS	0.593	0.473–0.713	0.136	43	76	33	82	68
TD (mm)	0.575	0.457–0.693	0.228	68	52	29	85	56
Facet asymmetry	0.541	0.425–0.658	0.509	100	12	25	100	32
Trochlear sulcal angle	0.575	0.45–0.7	0.227	29	89	42	81	75
Lateral inclination angle	0.555	0.443–0.668	0.373	79	37	26	86	46

Abbreviations: AUROC, area under ROC curve; BMI, body mass index; CI, confidence interval; DA, diagnostic accuracy; NPV, negative predictive value; PPV, positive predictive value; RAMP, repaired anterior medial portal; ROC, receiver operating characteristic; Sn, sensitivity; Sp, specificity; TS, tibial slope.

their study, discovered a high prevalence (34.4%) of RAMP lesions and identified a strong association between high-grade Lachman's exam and male sex with the presence of RAMP lesions. However, there were no significant differences in posterior TS between patients with and without RAMP lesions.<sup>24</sup>

In this study, the PMTBE was significantly associated ( $p < 0.05$ ) with RAMP lesion on arthroscopy. Green et al in their study, found similar results.<sup>25</sup> There was a statistically significant agreement between MRI and arthroscopy in regard to RAMP lesions in our study. The sensitivity and specificity of MRI with reference to arthroscopy in detecting RAMP lesions was 71.4% (95% CI: 51–87%) and 99.0% (95% CI: 94–100%), respectively. Moteshekereh et al conducted a systematic review and meta-analysis on MRI's diagnostic performance for RAMP lesions in ACL-deficient knees. They found pooled sensitivity and specificity to be 0.70 and 0.88, respectively. D'Ambrosi et al reviewed MRI sensitivity, specificity, and accuracy for detecting RAMP lesions in ACL-deficient children and adolescents. They noted a similar prevalence to adults, with MRI showing low sensitivity but good specificity. Laurens et al assessed MRI accuracy for RAMP lesions in acute ACL injury patients. Among various pathological signs, only complete fluid filling between the capsule and the PHMM was a significant indicator, with moderate accuracy.<sup>26–28</sup>

This study has several limitations that should be considered when interpreting the results. First, the small sample size of 126 patients limits the generalizability of the findings to broader populations. Additionally, the study was conducted at a single tertiary care referral center, potentially introducing selection bias and limiting the applicability of the results to different clinical settings or populations. Second, while the MRI scans were interpreted by experienced radiologists, there is inherent variability in imaging interpretation, which could affect the consistency of RAMP

lesion detection. The blinding of radiologists to clinical and demographic information aimed to reduce bias, but interobserver variability was not specifically measured, which could influence the study's diagnostic accuracy findings. Third, the cross-sectional design of the study limits the ability to establish causal relationships between the identified risk factors and the development of RAMP lesions. Longitudinal studies would be necessary to better understand the temporal sequence and causality of these associations. Lastly, the study's reliance on MRI and arthroscopy as diagnostic tools introduces potential measurement biases. While arthroscopy is considered the gold standard, it is still operator-dependent and may miss small or subtle lesions. The study did not account for potential differences in diagnostic performance between different surgeons or radiologists.

## Conclusion

This study explored the relationship between femoral trochlear morphology and RAMP lesions in ACL-deficient knees using MRI, alongside other anthropometric factors, and the diagnostic accuracy of MRI compared to arthroscopy. Despite the hypothesis that femoral trochlear morphology could be linked to RAMP lesions, no significant association was found. Instead, the medial TS and PMTBE emerged as significant predictors for RAMP lesions. MRI proved to be a reliable diagnostic tool, demonstrating high specificity but moderate sensitivity when referenced against arthroscopy.

Future research should address the above limitations by including larger, more diverse populations, utilizing standardized imaging interpretation protocols, and incorporating longitudinal designs to better understand the progression and causality of RAMP lesions. Additionally, multicenter studies could help to validate and generalize the findings across different clinical settings and patient demographics. A future investigation that includes both



ACL rupture cases and intact ACL cases will allow to assess the prevalence of RAMP lesions and their association with trochlear dysplasia across a broader population.

#### Ethical Approval

All procedures performed in studies involving human participants were in accordance with the ethical standards of the institutional and/or national research committee and with the 1964 Helsinki Declaration and its later amendments or comparable ethical standards.

#### Patients' Consent

Informed consent was obtained from all individual participants included in the study.

#### Funding

None.

#### Conflict of Interest

None declared.

#### References

- Fischer W. Update Meniskus. [Meniscus update] *Radiologie (Heidelberg)* 2024;64(04):254–260
- Strobel MJ. Menisci. In: Fett HM, Flechtner P, eds. *Manual of Arthroscopic Surgery*. New York: Springer; 1988:171–178
- Thaunat M, Fayard JM, Guimaraes TM, Jan N, Murphy CG, Sonnery-Cottet B. Classification and surgical repair of ramp lesions of the medial meniscus. *Arthrosc Tech* 2016;5(04):e871–e875
- Greif DN, Baraga MG, Rizzo MG, et al. MRI appearance of the different meniscal ramp lesion types, with clinical and arthroscopic correlation. *Skeletal Radiol* 2020;49(05):677–689
- Tomsan H, Gorbachova T, Fritz RC, et al. Knee MRI: meniscus roots, ramps, repairs, and repercussions. *Radiographics* 2023;43(07):e220208
- Mostafa Zaky Abdelrazek BH, Waly MR, Abdel Aziz MA, Abdel Aziz A. Different techniques for the management of meniscal ramp lesions using standard anterior portals. *Arthrosc Tech* 2019;9(01):e39–e44
- Cristiani R, van de Bunt F, Kvist J, Stålmán A. High prevalence of meniscal ramp lesions in anterior cruciate ligament injuries. *Knee Surg Sports Traumatol Arthrosc* 2023;31(01):316–324
- Yasuma S, Kobayashi M, Kawanishi Y, et al. Diagnosis of medial meniscal ramp lesion is difficult by pre-operative magnetic resonance imaging evaluation and needs a methodical arthroscopic exploration. *J Orthop Sci* 2022;27(06):1271–1277
- Kinugasa T, Mutsuzaki H, Taniguchi Y, Sato Y, Watanabe A, Ikeda K. Utility of axial magnetic resonance images for detecting meniscal ramp lesions associated with anterior cruciate ligament injuries. *Asia Pac J Sports Med Arthrosc Rehabil Technol* 2022;30:32–35
- Brophy RH, Steinmetz RG, Smith MV, Matava MJ. Meniscal ramp lesions: anatomy, epidemiology, diagnosis, and treatment. *J Am Acad Orthop Surg* 2022;30(06):255–262
- Beel W, Mouton C, Tradati D, Nührenbörger C, Seil R. Ramp lesions are six times more likely to be observed in the presence of a posterior medial tibial bone bruise in ACL-injured patients. *Knee Surg Sports Traumatol Arthrosc* 2022;30(01):184–191
- Kunze KN, Wright-Chisem J, Polce EM, DePhillipo NN, LaPrade RF, Chahla J. Risk factors for ramp lesions of the medial meniscus: a systematic review and meta-analysis. *Am J Sports Med* 2021;49(13):3749–3757
- Kim SH, Lee SH, Kim KI, Yang JW. Diagnostic accuracy of sequential arthroscopic approach for ramp lesions of the posterior horn of the medial meniscus in anterior cruciate ligament-deficient knee. *Arthroscopy* 2018;34(05):1582–1589
- Akgün AS, Agirman M. Associations between anterior cruciate ligament injuries and patella alta and trochlear dysplasia in adults using magnetic resonance imaging. *J Knee Surg* 2021;34(11):1220–1226
- Ntigiopoulos PG, Bonin N, Sonnery-Cottet B, Badet R, Dejour D. The incidence of trochlear dysplasia in anterior cruciate ligament tears. *Int Orthop* 2014;38(06):1269–1275
- Botchu R, Obaid H, Rennie WJ. Correlation between trochlear dysplasia and anterior cruciate ligament injury. *J Orthop Surg (Hong Kong)* 2013;21(02):185–188
- Isıklar S, Ozdemir ST, Gokalp G. An association between femoral trochlear morphology and non-contact anterior cruciate ligament total rupture: a retrospective MRI study. *Skeletal Radiol* 2021;50(07):1441–1454
- Song GY, Liu X, Zhang H, et al. Increased medial meniscal slope is associated with greater risk of ramp lesion in noncontact anterior cruciate ligament injury. *Am J Sports Med* 2016;44(08):2039–2046
- Elias DA, White LM. Imaging of patellofemoral disorders. *Clin Radiol* 2004;59(07):543–557
- Tang Z, Luo Y, Liu D, et al. Investigation of the anatomic risk factors in acute anterior cruciate ligament ruptures to develop ramp lesions of the medial meniscus by quantitative MRI. *Insights Imaging* 2024;15(01):133
- D'Ambrosi R, Sconfienza LM, Albano D, et al. High incidence of RAMP lesions and a nonnegligible incidence of anterolateral ligament and posterior oblique ligament rupture in acute ACL injury. *Knee Surg Sports Traumatol Arthrosc* 2024;32(08):1992–2002
- Jiang J, Liu Z, Wang X, Xia Y, Wu M. Increased posterior tibial slope and meniscal slope could be risk factors for meniscal injuries: a systematic review. *Arthroscopy* 2022;38(07):2331–2341
- Mahmood A, Mlv SK, Garika SS, Mittal R, Digge VK, Gamanagatti S. Ramp lesions in chronic anterior cruciate ligament injuries. *Cureus* 2022;14(08):e28450
- Familiari F, Tollefson LV, Izzo A, Mercurio M, LaPrade RF, Di Vico G. A high-grade Lachman's exam predicts a ramp tear of the medial meniscus in patients with anterior cruciate ligament tear: a prospective clinical and radiological evaluation. *J Clin Med* 2024;13(03):683
- Green JS, Moran J, Marcel A, et al. Posteromedial tibial plateau bone bruises are associated with medial meniscal ramp lesions in patients with concomitant anterior cruciate ligament ruptures: a systematic review & meta-analysis. *Phys Sportsmed* 2023;51(06):531–538
- Moteshakereh SM, Zarei H, Nosratpour M, et al. Evaluating the diagnostic performance of MRI for identification of meniscal ramp lesions in ACL-deficient knees: a systematic review and meta-analysis. *J Bone Joint Surg Am* 2024;106(12):1117–1127
- D'Ambrosi R, Di Maria F, Ursino C, et al. Magnetic resonance imaging shows low sensitivity but good specificity in detecting ramp lesions in children and adolescents with ACL injury: a systematic review. *J ISAKOS* 2024;9(03):371–377
- Laurens M, Cavaignac E, Fayolle H, et al. The accuracy of MRI for the diagnosis of ramp lesions. *Skeletal Radiol* 2022;51(03):525–533