




The Role of Helmet Therapy in Craniosynostosis: A Systematic Review

Fatima Suleman¹  Ayesha Sohail¹ Gohar Javed¹ Syeda Sana Samar²

¹Department of Neurosurgery, Aga Khan University Hospital, Karachi, Pakistan

²Department of Neurosurgery, Jinnah Sindh Medical University, Karachi, Pakistan

Address for correspondence Gohar Javed, MBBS, FCPS, Department of Neurosurgery, Aga Khan University Hospital, Karachi 74800, Pakistan (e-mail: gohar.javed@aku.edu).

Asian J Neurosurg 2024;19:610–617.

Abstract

The aim of this study was to determine the impact of helmet therapy (HT) as a treatment for craniosynostosis, with a focus on the outcomes of skull morphology, reoperation rate, complications of HT, and quality of life of patients who receive it. A systematic literature review was conducted following the Preferred Reporting Items for Systematic Reviews and Meta-Analyses (PRISMA) guidelines. The review utilized the PICO format: Does HT following strip craniectomy (SC) improve outcomes (outcome) compared to SC alone (comparison) in patients undergoing craniosynostosis correction (intervention)? Searches were performed from January 1, 2000 to December 31, 2022, using PubMed, Cochrane Library, and Ovid Medline databases. Study quality was evaluated using the National Heart, Lung, and Blood Institute (NHLBI) quality assessment scale. Fourteen studies meeting the inclusion criteria were identified. Among these, 438 patients underwent SC-HT, while 104 patients underwent SC without HT. The preoperative cephalic indices for sagittal craniosynostosis in the HT and non-HT groups were 66.8 and 67.8, respectively, which improved postoperatively to 75 and 76.2, respectively. Limited long-term follow-up hindered a definitive assessment of reoperation rates. Complication rates related to HT were low at approximately 2.9%, primarily consisting of skin irritation. Parental satisfaction was high, correlating with a strong compliance rate. Existing literature does not demonstrate a clear superiority between SC with or without HT for treating nonsyndromic sagittal craniosynostosis. Outcomes appear comparable, but evidence is constrained by the predominance of single-center retrospective studies with limited methodological rigor. There is a pressing need for international multicenter trials to furnish more robust and generalizable findings.

Keywords

- ▶ craniofacial
- ▶ craniosynostosis
- ▶ cranial sutures
- ▶ morphology

Introduction

Craniosynostosis is the premature fusion of one or more calvarial sutures resulting in an abnormal head shape. It is

typically mild at birth, and gets diagnosed as a cranial deformity in the first few months of life.¹ Although several genetic factors have been identified as playing a role in syndromic craniosynostosis, the etiology of isolated

article published online
September 30, 2024

DOI <https://doi.org/10.1055/s-0044-1791228>.
ISSN 2248-9614.

© 2024. Asian Congress of Neurological Surgeons. All rights reserved.

This is an open access article published by Thieme under the terms of the Creative Commons Attribution-NonDerivative-NonCommercial-License, permitting copying and reproduction so long as the original work is given appropriate credit. Contents may not be used for commercial purposes, or adapted, remixed, transformed or built upon. (<https://creativecommons.org/licenses/by-nc-nd/4.0/>)

Thieme Medical and Scientific Publishers Pvt. Ltd., A-12, 2nd Floor, Sector 2, Noida-201301 UP, India

craniosynostosis remains unknown.² Concerns regarding restricted brain growth, increased intracranial pressure, and cosmesis necessitate the need of repair of these pathologically fused bones.³ Understanding the principles governing the brain and cranial growth in children, as well as the effects of synostosis on this growth has resulted in advances in the surgical management of the condition.⁴ The best management option is determined by the patient's age, type, and severity of craniosynostosis, and thus remains a point of contention in neurosurgery. The aim is to achieve the best cosmetic and neurodevelopmental outcomes by the least invasive approach.⁵ The surgical treatment has evolved over years from simple strip craniectomy (SC) to the "pi" procedure to cranial vault remodeling.⁶ Recently, endoscopic suture release with postoperative molding helmet therapy (HT) has been found quite promising. Few studies have also mentioned the use of helmets after open surgeries.

The molding helmet wraps around the cranium and influences three-dimensional cranial growth through modifications at certain pressure points. Because of its noninvasive complementary addition after surgery to prevent refusion and improve outcomes, it has seen a surge in use in craniosynostosis.⁷ Despite the fact that many studies have described its postoperative role in craniectomies, no large-scale literature review has focused on evaluating these studies to establish its definitive role. The aim of this study is to review the outcomes of HT in patients with craniosynostosis as well as its effects on the infant's quality of life and parental satisfaction.

Materials and Methods

Literature Search Strategy

The Preferred Reporting Items for Systematic Reviews and Meta-Analyses (PRISMA) guidelines were followed for our systematic review.⁸ The PICO format was used to design the literature search strategy: Is there a difference in clinical and surgical outcomes (outcome) between patients who received HT (population of interest) and patients who did not receive HT (comparison) after SC for craniosynostosis correction? (intervention). The review was registered with PROSPERO International Prospective Register of Systematic Reviews (CRD42022374986). PubMed, Cochrane Central Register of Control Trials, Cochrane Database of Systematic Reviews, and OVID Medline were used for electronic searches. The search was restricted to the time period from January, 2000 to December, 2022. Advanced search of title/abstract/keywords was done by combining the search terms "helmet" AND "craniosynostosis," "craniectomy" AND "craniosynostosis," "suturectomy" AND "craniosynostosis," and "orthosis" AND "craniosynostosis," and in combinations (► **Supplementary Table 1**, available in the online version). In addition, for the same time period, an advanced ".ti" search was performed on Ovid Medline using the same keywords.

Selection criteria: Retrieved studies were assessed using the inclusion/exclusion criteria. We included all studies between January 1, 2000 and December 31, 2022 of strip craniectomy with helmet therapy (SC-HT) and SC for the

management of nonsyndromic craniosynostosis assessing the outcomes of interest.

Studies were excluded if (1) the study is on nonhuman subject; (2) not in the English language; (3) review articles, case reports (1–2 patient reports), editorials, abstracts, and dissertations; (4) no relevant results concerning the review outcomes were reported; (5) duplicated study; (6) outcomes are studied after the provision of preoperative HT; (7) HT used for cranial deformity other than craniosynostosis; (8) multisuture, or shunt-related craniosynostosis; (9) studies including patients undergoing cranial vault reconstruction, cranioplasty, barrel stave osteotomy, or wedge osteotomy; and (10) studies not mentioning any quantitative outcomes.

Data extraction process: The title, keywords, authors' names, journal name, and year of publication of the identified records from each database were exported to endnote. The last search was run on September 20, 2023. Two independent reviewers (F.S. and A.S.) screened the titles, abstracts, and full articles of the records independently, and any discrepancy was resolved by discussion to reach consensus. Primary outcomes of interest included (1) change in skull shape/morphology, (2) reoperations, and (3) complications of HT and quality of life.

We extracted the following information for each study: location, study design, cohort size, sex, and mean age at surgery. For studies with HT, we also extracted information regarding its time of provision postoperatively, total duration, and mean number of orthoses required per patient. We collected data on the following dichotomous variables: need for reoperation and complications. We collected summary data (mean or median) on the continuous variables reporting cranial morphological outcomes.

Methodological Quality Assessment

The quality of methodology and risk of bias in the selected studies was evaluated using the National Heart, Lung, and Blood Institute (NHLBI) Quality Assessment Tool for Observational Cohort and Cross-Sectional Studies. Quality of the studies was graded as poor (score of 0–4 out of 14), fair (score of 5–10 out of 14), and good (score of 11–14 out of 14); ► **Supplementary Table 2**, available in the online version).⁹

Results

Study characteristics: A total of 1,084 results were obtained. Nine articles were retrieved from Cochrane Central Register of Control Trials, none from Cochrane Database of Systematic Reviews, 222 from Ovid Medline, and 853 from PubMed. Out of these, 913 were selected for screening following deduplication. Following screening of the title and removing syndromic, shunt-related, multisuture craniosynostosis, positional head deformities, case reports, reviews, and editorials, 472 studies were obtained. After abstract screening, 85 articles were selected for full-text screening, and 14 were included in the review (► **Supplementary Table 3**, available in the online version; ► **Fig. 1**).^{10–23}

Cohort description: The cohort was divided into two groups. The first group underwent open/endoscopic SC-HT

Table 1 Summary of included studies

Study	Study design	Treatment type	Cohort size (no. of patients)	Types of synostoses	Mean age (mo)	Time of beginning of HT (no. of days post-op)	Duration of HT (mo)	Average no. of helmets per patient
Baumgartner et al ¹⁰	Retrospective review	SCHT	14	8 sagittal, 3 metopic, 1 unicoronal, 1 bicoronal, 1 bilateral lambdoid	2.6	7-10	2-3	1-3
Jimenez and Barone ¹¹	Retrospective review	SCHT	115	115 coronal	3.1	6	NA	NA
Erşahin ¹²	Retrospective review	SCHT	19	19 metopic	3.75	7-10	10-12	NA
Gociman et al ¹³	Retrospective review	SCHT	16	16 metopic	2.9	7	12	3
Lajthia et al ¹⁴	Retrospective review	SCHT	7	7 metopic	2.76	7-14	12-18	NA
Delye et al ¹⁵	Retrospective review	SCHT	111	64 sagittal 34 metopic 13 coronal	3.9	NA	10	NA
Persad et al ¹⁶	Retrospective review	SCHT	32	32 sagittal	12.5	Within 28	4.7	1-3
Hwang et al ¹⁷	Retrospective review	SCHT	7	7 combined unilateral coronalHambdoid	4	14	6-13	NA
Jimenez and Barone ¹⁸	Retrospective review	SCHT	100	50 metopic 50 coronal	3.94	5	10-12	1-3
Sauerhammer et al ¹⁹	Retrospective review	SCHT	17	17 coronal	2.5	7	10-12	1-2
Schouman et al ²⁰	Retrospective review	SC	12	12 bilateral coronal	6			
Gociman et al ²¹	Retrospective review	SC	46	46 sagittal	3.1			
Murray et al ²²	Retrospective review	SC	24	46 sagittal	3.1			
Bonfield et al ²³	Retrospective review	SC	182	22 sagittal	3.95			

Abbreviations: SC, strip craniectomy; SCHT, strip craniectomy with helmet therapy.

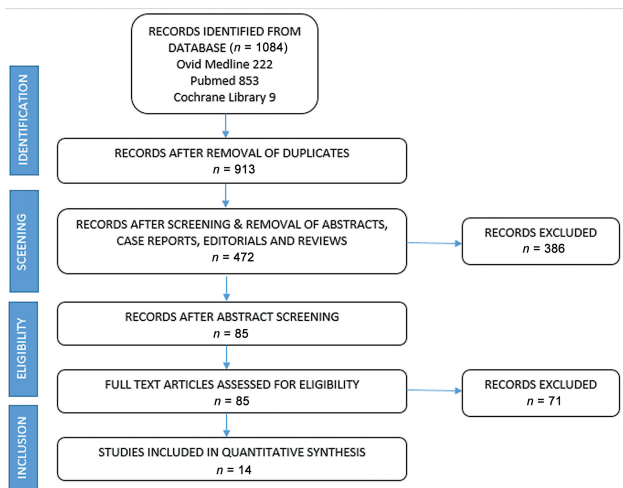


Fig. 1 Preferred Reporting Items for Systematic Reviews and Meta-Analyses (PRISMA) flow diagram.

and included 10 studies with 438 unique patients having metopic, unicoronal, bicoronal, unilateral lambdoid, sagittal, and combined unilateral coronal-lambdoid synostosis. The average age of patients in this group was 3 months.^{10–19} The second group included 104 patients from four studies who had undergone SC without HT. The average age of the patients in this group was also around 4.4 months^{20–23} (► **Table 1**).

Study Outcomes

Change in Cranial Morphology

Change in Cranial Morphology after Craniectomy with HT
Ten studies were retrospective analyses focusing on SC combined with HT.^{10–18} Eight of these studies reported quantitative changes in cranial morphology following SC + HT, with an average follow-up period of 28.3 months.^{10,12–17,19} These studies discussed how HT can aid in closing craniectomy gaps, correcting deformities, and decreasing the likelihood of recurrence and reoperations, ultimately leading to improved phenotypic outcomes.

Our review specifically addressed quantitative cranial morphological outcomes. Various indices were used to assess these outcomes, including head circumference, cephalic index, interfrontal divergence angle (IFDA), interzygomati-cofrontal (ZF-ZF) distance, and metopic and frontal angles. All the articles reported improvements in outcomes following HT. However, most studies did not compare the change in cranial morphology postoperatively or the percentage of improvement after HT. The longest mean follow-up was reported by Lajthia et al, with 43.1 months.¹⁴ Most studies initiated the use of orthosis within 1 week of surgery, continuing for 10 to 12 months postoperatively. Regular helmet fittings were conducted, with each patient using approximately one to three helmets.

During the article retrieval process, we encountered a study by Seymour-Dempsey et al, which was the only study comparing two groups (one with postsurgical band HT and

one without).⁷ The majority of patients underwent SC as the primary surgical procedure, while a few challenging cases required temporoparietal bone flap combined with occipital barrel stave osteotomies. This study was excluded from our review due to its different surgical approach. However, as it was the only study comparing postsurgical outcomes with and without HT, it is worth mentioning.

Seymour-Dempsey et al⁷ calculated the cranial index (CI) at three different points: preoperatively, postoperatively, and at follow-up visits approximately 4 to 12 months after surgery. A statistically significant change in CI was observed in patients treated with surgery and HT during both the preoperative–postoperative and preoperative–follow-up intervals. The median CI value increased significantly from 0.694 preoperatively to 0.767 postoperatively. A statistically significant change in CI was also observed in the non-HT group during the same intervals. However, no statistically significant differences in CI were observed between the postoperative and follow-up periods in either the banded or nonbanded groups. Although there was no statistically significant difference between the banded group's postoperative and follow-up values, the median CI did move closer to normal with a follow-up median of 0.753. This normalization trend was not present in the non-HT group.

Change in Cranial Morphology after Craniectomy without HT:

Four retrospective studies^{20–23} were included. All of them showed postoperative improvement in cranial indices on an average follow-up period of 72.1 months; however, three of the four studies showed some risk of reoperation.

The findings of the above-mentioned studies are summarized in ► **Table 2**. We sought to see if any one of the management strategies resulted in better outcomes. Cephalic index was the most common variable used to compute the outcomes in most of the studies. We, therefore, compared the mean cephalic index for sagittal craniosynostosis obtained by both the management strategies (SC + HT and SC), and found no significant difference in the outcomes, mentioned in ► **Table 3**. In the HT versus non-HT groups, the preoperative cephalic indices for sagittal craniosynostosis were 66.8 versus 67.8, respectively, which improved postoperatively to 75 versus 76.2.

Helmet Therapy Complication and Quality of Life

Only three of the included studies^{11,15,18} primarily evaluated the complications and quality of life of patients following HT. The complication rate was found to be very low, approximately 2.9% (► **Tables 4 and 5**).

Delye et al found that HT was well accepted by 74% of patients, with good patient compliance. Helmets had a positive social impact on children. Only 0.9% (1 out of 111 patients) developed a rash, and 6.3% (7 out of 111 patients) showed adverse responses to the helmet, including increased worry, stress, and problems with physical contact between child and parent, such as during cuddling. HT was interrupted for 1 day in 74% of patients, usually during summer or when the child had a fever.¹⁵

Table 2 Cranial morphology outcomes

Study	Treatment type	Type of synostosis	Cohort size	Follow-up (mo)	Outcome variable	Pre-op score	Post-op score	Post-HT score	Reoperation
Baumgartner et al ¹⁰	SC-HT	Sagittal	8	20.5	Cephalic index	66.5	-	78	NA
Delye et al ¹⁵	SC-HT	Sagittal	54	6	Cephalic index	67	-	72	3/111 (2.7%)
Persad et al ¹⁶	SC-HT	Sagittal	32	60	Cephalic index	67	-	75 (p < 0.001)	0/32
Baumgartner et al ¹⁰	SC-HT	Metopic	3	20.5	FTr-FTr FZr-FZr Tr-Tr	62 71 88	-	77 82 96	NA
Erşahin ¹²	SC-HT	Metopic	19	14.8	Frontal angle (degrees)	94.25	-	101.75	NA
Gociman et al ¹³	SC-HT	Metopic	16	12	Metopic angle (degrees)	104.9	-	114.9	0/16
Lajthia et al ¹⁴	SC-HT	Metopic	7	43.1	Head circumference (cm) Head circumference percentile (%) Interfrontal angle (degrees)	38.36 56 118.8	-	49.94 (p < 0.001) 46.43 (p = 0.49) 135.9 (p = 0.01)	0/7
Baumgartner et al ¹⁰	SC-HT	Unicoronal	1	20.5	Skull vault asymmetry Facial asymmetry	13 mm 5 mm	18 mm 3 mm	0 mm 0 mm	NA
Sauerhammer et al ¹⁹	SC-HT	Unicoronal	17	NA	NA	NA	NA	NA	1/17 (0.05%)
Baumgartner et al ¹⁰	SC-HT	Bicoronal	1	20.5	Cephalic index	97	-	86	NA
Baumgartner et al ¹⁰	SC-HT	Bilateral lambdoid	1	20.5	Posterior skull vault asymmetry	5 mm	2 mm	0 mm	NA
Hwang et al ¹⁷	SC-HT	Combined unilateral coronal-lambdoid	6	12-62	Orbital index asymmetry (cm) Nasal ridge deviation (degrees) Posterior skull base cant	0.11 7.04 6.29	-	0.05 1.79 3.55	1/6 (16.6%)
Schouman et al ²⁰	SC	Bilateral coronal	12	140	Cephalic index	91.6	83.9	NA	2/12 (16.6%)
Gociman et al ²¹	SC	Sagittal	46	12	Cephalic index	70	80 (p < 0.001)	-	0/46
Murray et al ²²	SC	Sagittal	24	96	Cephalic index	65.3	73.7	-	4/96 (16.6%)
Bonfield et al ²³	SC	Sagittal	22	40.7	Cephalic index Naso-frontal angle	68 127	75 (p < 0.001) 133 (p < 0.001)	-	5/182 (2.7%)

Abbreviations: FTr, left frontotemporal; FTr, right frontotemporal; FZr, left frontozygomaticus; FZr, right frontozygomaticus; SC, strip craniectomy; SC-HT, strip craniectomy with helmet therapy; Tr, left trigion; Tr, trigion.

Table 3 Summary of cranial morphology outcomes for sagittal craniosynostosis

Variable	SC-HT				SC			
	No. of studies	No. of patients	Overall mean estimate (pre-op)	Overall mean estimate (post-HT)	No. of studies	No. of patients	Overall mean estimate (pre-op)	Overall mean estimate (post-op)
Cephalic index ^{10,15,16,21-23}	3	94	66.8	75	3	92	67.8	76.2

Table 4 Complications of helmet therapy (HT)

Study	Total number of patients	Patients with complications	
		Skin irritation/breakdown	Parent inconvenience
Jimenez and Barone ¹⁸	100	3	–
Jimenez and Barone ¹¹	115	2	–
Delye et al ¹⁵	111	1	7

Table 5 Summary of reoperations and complications

Variable	SC-HT			SC		
	No. of studies	No. of patients	Total with outcome of interest	No. of studies	No. of patients	Total with outcome of interest
Reoperations ^{13-17,19-23}	6	132	5 (3.7%)	4	336	11 (3.2%)
HT complications ^{11,15,18}	3	437	13 (2.9%)	NA		

Abbreviations: HT, helmet therapy; NA, not applicable; SC, strip craniectomy.

Reoperation Rate

The reoperation rate was assessed in six studies involving SC-HT and in four studies involving just SC.^{13-17,19-23} Due to limited long-term follow-ups, a definitive conclusion could not be reached. In the SC-HT group, only two studies reported follow-ups longer than 2 years. Persad et al followed patients for approximately 5 years and found that none required reoperation for sagittal craniosynostosis.¹⁶ Lajthia et al followed patients with coronal craniosynostosis for about 4 years and similarly found no need for reoperation.¹⁴

In the SC group, Schouman et al²⁰ followed patients for more than 10 years and found that the reoperation rate was approximately 16.6% (2 out of 12 patients required reoperation) for bicoronal craniosynostosis. Murray et al²² and Bonfield et al²³ followed patients with sagittal craniosynostosis for about 8 and 4 years, respectively, finding reoperation rates of around 16.6 and 2.7%, respectively (– **Tables 2** and **5**).

Future Directions

This review identifies significant evidence and knowledge gaps regarding the appropriate indices for measuring changes in head morphology after treatment. It does not determine if any method of treatment holds superiority over another, as a meta-analysis is required to establish such conclusions. Furthermore, the review could be extended to assess cost differences between the treatment groups and the effectiveness in managing intracranial pressure.

Additional research is necessary to establish proper guidelines for the optimal duration of HT. Long-term follow-ups are essential to evaluate the child's cognitive function and intracranial pressure. More studies are also needed to assess parental satisfaction and anxiety associated with use of HT for craniosynostosis.

A notable limitation of this review is the absence of studies that compare helmet and nonhelmet strategies within the same population of patients to evaluate outcomes. Addressing these gaps will require comprehensive research and standardized guidelines.

Discussion

In this literature review, we included 10 studies advocating for HT following craniosynostosis surgery. The primary aim was to determine whether any approach (SC-HT or SC alone) demonstrates superiority over the other, a long-standing debate in neurosurgery. Proponents of HT argue for enhanced head protection, improved morphological outcomes, and reduced reoperation risks.^{2,8} Conversely, critics highlight the economic and lifestyle burdens associated with helmets, potentially impacting a child's quality of life with orthoses.

To address this question, we compared two sets of SC studies: those incorporating HT¹⁰⁻¹⁹ and those without.²⁰⁻²³ Helmets were utilized across various types of craniosynostosis, including metopic, unicoronal, bicoronal, unilateral

lambdoid, sagittal, and combined unilateral coronal–lambdoid synostosis, in 10 studies. Four studies did not employ helmets.

There was considerable variation among the indices used to assess pre- and posttreatment outcomes across studies. The cephalic index emerged as the most commonly used variable, particularly for sagittal craniosynostosis. We specifically analyzed the difference in cephalic index resulting from both management strategies. Surprisingly, we found no significant difference in posttreatment cephalic index between the SC-HT and SC groups. The pre- and postoperative cephalic indices in the SC-HT and SC groups were 66.8 and 67.8 and 75 and 76.2, respectively. The complication rate associated with HT was low, approximately 2.9%, predominantly consisting of skin irritation or breakdown. Overall, compliance with helmet use was reported to be high.

It is important to note that our data were aggregated from studies analyzing individual techniques, precluding a pairwise meta-analysis with odds ratios and mean difference calculations. Therefore, these findings should be interpreted cautiously and considered hypothesis generating. The literature comparing these techniques remains limited, with only one case series directly comparing the two surgical approaches.⁷ While both strategies improved cranial morphology outcomes, the review did not address a crucial factor—intracranial pressure.

Moreover, due to the short-term follow-up in the included studies, long-term anthropometric outcomes between the two techniques could not be compared effectively. Due to the limited follow-up, definitive conclusion regarding reoperation rate could not be generated.

Conclusion

This systematic review demonstrates that the current literature does not show superiority of either SC-HT or SC, and outcomes are broadly similar for the treatment of non-syndromic sagittal craniosynostosis. However, the evidence is limited by single-center retrospective studies of low methodological quality. Given clinical equipoise, there is a need for international multicenter trials to provide definitive and generalizable data. This review identifies the evidence and knowledge gaps in appropriate indicators for measuring changes in head shape after treatment. Long-term follow-ups are required to assess the child's cognitive function.

Authors' Contributions

F.S. contributed to conception of the study and writing of the manuscript draft, data collection and screening, and data analysis and interpretation, and gave final approval of the version to be published. A.S. contributed to data collection and screening and analysis and interpretation of data, and gave final approval of the version to be published. G.J. contributed to conception and design of the manuscript, critical revision of the manuscript, and analysis and interpretation of data, and gave final approval of the version to be published. S.S.S. contributed to

revision of the manuscript draft and gave final approval of the version to be published.

Funding

None.

Conflict of Interest

None declared.

References

- Kabbani H, Raghuvver TS. Craniosynostosis. *Am Fam Physician* 2004;69(12):2863–2870
- Arts S, Delye H, van Lindert EJ. Intraoperative and postoperative complications in the surgical treatment of craniosynostosis: minimally invasive versus open surgical procedures. *J Neurosurg Pediatr* 2018;21(02):112–118
- Riordan CP, Zurakowski D, Meier PM, et al. Minimally invasive endoscopic surgery for infantile craniosynostosis: a longitudinal cohort study. *J Pediatr* 2020;216:142–149.e2
- Mehta VA, Bettgowda C, Jallo GI, Ahn ES. The evolution of surgical management for craniosynostosis. *Neurosurg Focus* 2010;29(06):E5
- Yan H, Abel TJ, Alotaibi NM, et al. A systematic review of endoscopic versus open treatment of craniosynostosis. Part 2: the nonsagittal single sutures. *J Neurosurg Pediatr* 2018;22(04):361–368
- Lee HQ, Hutson JM, Wray AC, et al. Analysis of morbidity and mortality in surgical management of craniosynostosis. *J Craniofac Surg* 2012;23(05):1256–1261
- Seymour-Dempsey K, Baumgartner JE, Teichgraeber JF, Xia JJ, Waller AL, Gateno J. Molding helmet therapy in the management of sagittal synostosis. *J Craniofac Surg* 2002;13(05):631–635
- Checklist P. PRISMA: Transparent Reporting of Systematic Reviews and Meta-Analyses. Accessed September 19, 2024 at: <https://www.prisma-statement.org/>
- National Heart, Lung, and Blood Institute. Study Quality Assessment Tools. Bethesda, MD: National Heart, Lung, and Blood Institute; 2021
- Baumgartner JE, Teichgraeber JF, Waller AL, Grantcherova E, Gateno J, Xia JJ. Microscopic approach to craniosynostosis. *J Craniofac Surg* 2005;16(06):997–1005
- Jimenez DF, Barone CM. Early treatment of coronal synostosis with endoscopy-assisted craniectomy and postoperative cranial orthosis therapy: 16-year experience. *J Neurosurg Pediatr* 2013;12(03):207–219
- Erşahin Y. Endoscope-assisted repair of metopic synostosis. *Childs Nerv Syst* 2013;29(12):2195–2199
- Gociman B, Agko M, Blagg R, Garlick J, Kestle JR, Siddiqi F. Endoscopic-assisted correction of metopic synostosis. *J Craniofac Surg* 2013;24(03):763–768
- Lajthia O, Rogers GF, Tsering D, Keating RF, Magge SN. Quantitative outcomes of endoscopic strip craniectomy for metopic craniosynostosis in children with severe trigonocephaly. *Childs Nerv Syst* 2021;37(02):573–579
- Delye H, Arts S, Borstlap WA, et al. Endoscopically assisted craniosynostosis surgery (EACS): the craniofacial team Nijmegen experience. *J Craniomaxillofac Surg* 2016;44(08):1029–1036
- Persad A, Aronyk K, Beaudoin W, Mehta V. Long-term 3D CT follow-up after endoscopic sagittal craniosynostosis repair. *J Neurosurg Pediatr* 2019;25(03):291–297
- Hwang JH, Yang J, Kim KH, et al. Combined unilateral coronal–lambdoid suture synostosis: surgical outcome of sutulectomy and postoperative helmet therapy. *Childs Nerv Syst* 2021;37(01):277–286
- Jimenez DF, Barone CM. Early treatment of anterior calvarial craniosynostosis using endoscopic-assisted minimally invasive techniques. *Childs Nerv Syst* 2007;23(12):1411–1419
- Sauerhammer TM, Seruya M, Ropper AE, Oh AK, Proctor MR, Rogers GF. Craniectomy gap patency and neosuture formation

- following endoscopic suturectomy for unilateral coronal craniosynostosis. *Plast Reconstr Surg* 2014;134(01):81e–91e
- 20 Schouman T, Vinchon M, Ruhin-Coupet B, Pellerin P, Dhellemmes P. Isolated bilateral coronal synostosis: early treatment by perifronto-orbital craniectomy. *J Craniofac Surg* 2008;19(01):40–44
- 21 Gociman B, Marengo J, Ying J, Kestle JR, Siddiqi F. Minimally invasive strip craniectomy for sagittal synostosis. *J Craniofac Surg* 2012;23(03):825–828
- 22 Murray DJ, Kelleher MO, McGillivray A, Allcutt D, Earley MJ. Sagittal synostosis: a review of 53 cases of sagittal suturectomy in one unit. *J Plast Reconstr Aesthet Surg* 2007;60(09):991–997
- 23 Bonfield CM, Lee PS, Adamo MA, Pollack IF. Surgical treatment of sagittal synostosis by extended strip craniectomy: cranial index, nasofrontal angle, reoperation rate, and a review of the literature. *J Craniomaxillofac Surg* 2014;42(07):1095–1101