




# Thoracic and Lumbar Spinal Fractures and Luxations in 26 Dogs and 2 Cats—Stabilization by String of Pearls Locking Plates

Mei-Jyun Ciou<sup>1</sup>  Richard Jerram<sup>2</sup> Jason Syrcle<sup>3</sup> Andrew S. Levien<sup>4</sup> Dipak Kumar Sahoo<sup>1</sup> Karl Kraus<sup>1</sup>

<sup>1</sup>Department of Veterinary Clinical Sciences, College of Veterinary Medicine, Iowa State University, Ames, Iowa, United States

<sup>2</sup>Veterinary Specialists Aotearoa, Christchurch, New Zealand

<sup>3</sup>Department of Clinical Sciences and Advanced Medicine, University of Pennsylvania School of Veterinary Medicine, Philadelphia, Pennsylvania, United States

<sup>4</sup>Veterinary Specialists of Sydney, Sydney, New South Wales, Australia

**Address for correspondence** Mei-Jyun Ciou, DVM, Department of Veterinary Clinical Sciences, College of Veterinary Medicine, Iowa State University, Ames, IA 50010, United States (e-mail: mjciou@gmail.com).

VCOT Open 2024;7:e108–e113.

## Abstract

**Objective** To evaluate the use of String of Pearls (SOP) locking plates in thoracolumbar vertebral fractures and luxations in dogs and cats.

**Study design** Retrospective case series study.

**Methods** Clinical records of dogs and cats with thoracic and lumbar fractures treated in four veterinary surgical facilities were reviewed.

**Results** A total of 26 dogs and 2 cats were included. Median weight of dogs at surgery was 12.1 kg (range: 2.7–37.2 kg) and the median weight of cats was 6.0 kg (range: 3.0–8.9 kg). Deep pain perception was negative in 25% (7/28) of animals at presentation, and 85.7% (6/7) regained deep pain sensation at discharge. Neurological status at discharge ( $p < 0.05$ ) was significantly improved compared to neurological status at presentation. Complications were observed in 28.6% (8/28) of cases. Catastrophic and major complication rates were both 3.6% (1/28).

**Conclusion** In the reported cohort of 28 dogs and cats, SOP locking plates successfully stabilized traumatic thoracic and lumbar fractures or luxations, and the rate of complications was similar to those reported using other fixation methods.

## Keywords

- ▶ String of Pearls plates
- ▶ spinal fractures
- ▶ luxations
- ▶ dogs
- ▶ cats

## Introduction

Spinal fractures and luxations in small animals are most commonly caused by vehicular trauma and falls from heights.<sup>1,2</sup> Other frequent causes of spinal injury include animal attacks and gunshot wounds, as well as nontraumatic causes, such as neoplasia, infection, and metabolic disease.<sup>2</sup> The thoracic and lumbar spines are the most commonly affected regions of traumatic fractures and luxations.<sup>2–6</sup>

Multiple methods of spinal fixation have been described, including pins and/or screws with polymethylmethacrylate (PMMA), vertebral body plating, vertebral stapling, and external skeletal fixation.<sup>6–9</sup> No single method of fixation has been shown to be best for every situation.<sup>2,6</sup> There is a scarcity of scientific literature on the use of locking plates in canine and feline thoracic and lumbar vertebral fractures or luxations. In clinical patients, the description of the use of locking compression plates (LCPs) and String of Pearls (SOP)

received

February 9, 2024

accepted after revision

August 1, 2024

DOI <https://doi.org/>

10.1055/s-0044-1789252.

ISSN 2625-2325.

© 2024. The Author(s).

This is an open access article published by Thieme under the terms of the Creative Commons Attribution License, permitting unrestricted use, distribution, and reproduction so long as the original work is properly cited. (<https://creativecommons.org/licenses/by/4.0/>)

Georg Thieme Verlag KG, Rüdigerstraße 14, 70469 Stuttgart, Germany

locking plates for vertebral injuries is limited to a few case reports.<sup>10–12</sup>

The application of SOP locking plates in spinal trauma has gained attention in the recent decade due to its locking characteristics, while still allowing for flexibility in plate contouring to facilitate safe positioning of screws in vertebral bodies. A few reports focus on the use of SOP plates in stabilizing the cervical and lumbosacral regions of the spine.<sup>13,14</sup> To the best of the authors' knowledge, no comprehensive review is available regarding the application of SOP locking plates for thoracic and lumbar vertebral fractures or luxations in both dogs and cats.

The purpose of this study is to report implant configuration, clinical neurological outcome, and complication rates in a cohort of 28 dogs and cats with thoracic and lumbar fractures/luxations treated with SOP locking plates.

## Materials and Methods

### Case Selection and Data Collection

The medical records for dogs and cats diagnosed with traumatic spinal fractures or luxations and stabilized with SOP locking plates between 2010 and 2022 were reviewed at four animal hospitals. Data were collected regarding, age, sex, body weight, type and location of injury, implants, radiographic assessment, neurological status, and complications (► **Supplementary Table S1** (available online)).

### Preoperative Evaluation and Care

Before surgery, all animals were medically stabilized and radiographed. Analgesia was administered in-hospital and generally consisted of opioids such as hydromorphone (0.1–0.2 mg/kg, intravenously, every 4–6 hours), methadone (0.2 mg/kg intravenously, every 4 hours), or fentanyl (3–5 mcg/kg/h, constant rate infusion) and/or carprofen (2.2 mg/kg subcutaneously, every 12 hours). Complete blood count and serum chemistry were conducted in all patients preoperatively. Surgeries were performed by four board-certified surgeons in the reporting institutions. Animals underwent standard preparation for aseptic surgery and were positioned in sternal recumbency for a dorsal surgical approach.

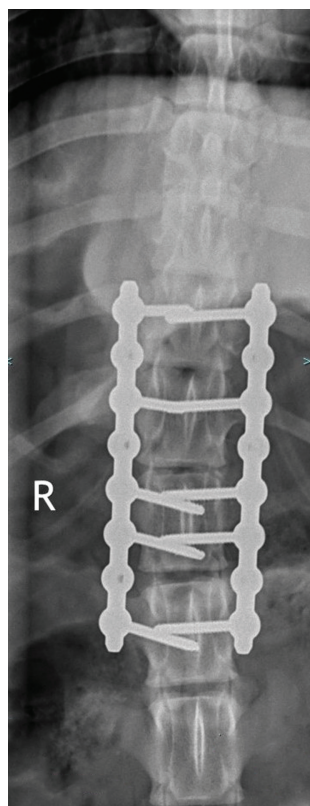
### Surgical Procedure

A dorsal approach to the spine was made by elevating epaxial musculature from the spinous processes, lamina, pedicles, and to the transverse process. The approach was bilateral for bilateral plating and unilateral with unilateral plating. In cases of vertebral displacement, articular facets were manually aligned and Kirschner wires (K-wires) were placed across one or both facets during placement of the SOP locking plates. In cases of spinal cord compression caused by bone fragments, bone fragments and hematoma were removed by means of a laminectomy or pediculectomy. If reduction of displaced vertebrae was deemed sufficient to decompress neurological structures, the vertebral canal was not approached. Intervertebral disks were identified and plates were placed between the level of

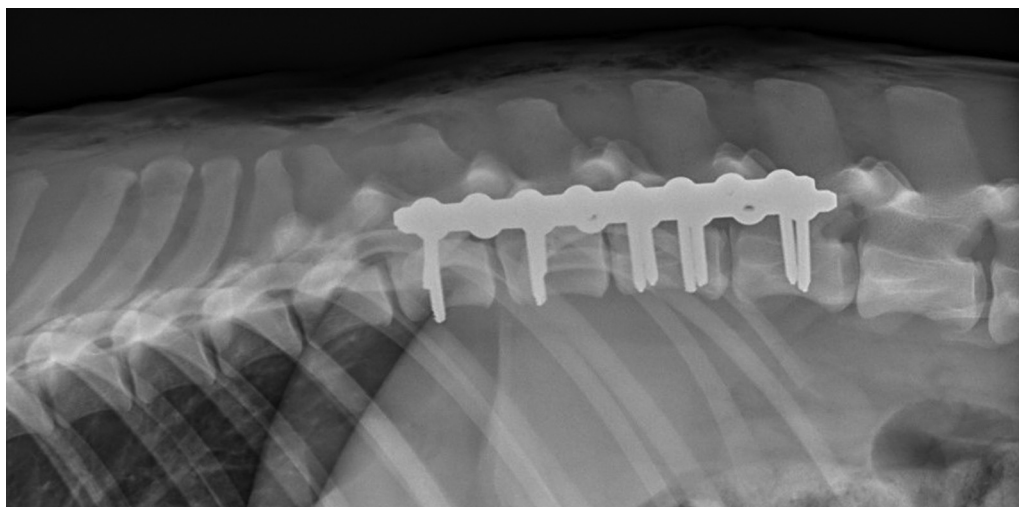
articular facets and transverse processes in the lumbar vertebrae and between the level of articular facets and rib heads in the thoracic area. Exposure of the intervertebral disks allowed the plates to be placed with screws in the vertebral bodies without engaging the disks. SOP locking plates (Orthomed UK Ltd, Halifax, United Kingdom) were placed along the vertebral column and spanned one to two vertebrae on each side of the injury. The extent of stabilization, unilateral or bilateral, was chosen at the surgeons' discretion. The SOP locking plates used were in three sizes (2.0, 2.7, and 3.5 mm) with conventional cortical screws; sizes depended on the animals' body weight, vertebral shape, and on measurements made on diagnostic images.<sup>15</sup> Screw placement angles were based on published recommendations, visual observation, and freehand probing technique.<sup>16</sup> The temporary reduction K-wires were removed before closure. Standard closure of epaxial fascia, subcutaneous tissue, and skin was performed. Orthogonal radiographic views were obtained following surgery (► **Figs. 1** and **2**).

### Neurological Assessment

Neurological status was assessed preoperatively, postoperatively within 24 hours, daily until hospital discharge (range: 3–11 days), and at recheck from 2 to 13 weeks postoperatively. The neurological status was graded using a 5-point scale adapted from Matthiesen (► **Table 1**).<sup>4</sup> Statistical analyses were performed using commercial statistical software (GraphPad Prism 9 Software). A comparison of neurologic



**Fig. 1** Dorsoventral radiographic views following surgery, T13-L1 subluxation and L1 fracture case 4.



**Fig. 2** Lateral radiographic views following surgery, T13-L1 subluxation and L1 fracture case 4.

status was performed between preoperatively and postoperatively within 24 hours and between preoperatively and at discharge by using the Kruskal–Wallis test followed by Dunn’s post-hoc test for multiple comparisons. A two-tailed value of  $p < 0.05$  was considered significant.

### Peri- and Postoperative Care

Patients remained hospitalized after surgery to closely monitor neurologic function and to provide intensive nursing care as needed. During this time, crystalloid fluids and injectable opioids and/or nonsteroid anti-inflammation pain medications were given. Nasal gastric feeding tubes were placed in cases of prolonged inappetence. Patients with decreased mobility were moved and turned every 4 to 6 hours to prevent pressure sores and respiratory problems. Animals with voluntary urination were carried outside three to four times daily. Those with impaired bladder function had a urinary catheter placed or assisted by applying of gentle pressure three to four times daily.

### Complications

Complications were recorded according to the severity defined as “catastrophic” when causing permanent dysfunction, or were directly relatable to death, or cause for euthanasia. Major complications were those that required

additional medical or surgical treatment to resolve. Minor complications were those that simply resolved spontaneously within a short time (e.g., bruising, seroma, minor incision problems, etc.).<sup>17</sup>

### Results

The medical records of a total number of 28 dogs and 2 cats diagnosed with spinal fracture or luxation from 2010 to 2022 were reviewed. All cases were stabilized with SOP plates. Of these 28 cases, 46.4% (13/28) were male and 53.6% (15/28) were female. Median body weight of all patients was 10.9 kg (range: 2.7–37.2 kg), and median body weight of all dogs was 12.1 kg (range: 2.7–37.2 kg). All fractures and luxations were traumatic, and occurred more frequently in dogs and cats at younger age (median: 2 years, range: 5 months–14 years). Motor vehicle accidents accounted for 67.9% (19/28) of injuries, while animal-related attacks accounted for 21.4% (6/28), and falling from height accounted for 10.7% (3/28). The location of the fracture or luxation ranged from T5 to L7.

In total, 82.1% (23/28) underwent bilateral spinal plating while 17.9% (5/28) underwent unilateral spinal plating (► **Table 2**). In cases with unilateral spinal plating (5/28), the median number of screws cranial to the lesion was 2 (range: 2–3), and the median number of screws caudal to the lesion was 3 (range: 2–4). In cases with bilateral spinal plating (23/28), the median number of screws cranial to the lesion was 4 (range: 2–8), and the median total number of screws caudal to the lesion with bilateral plating was 4 (range: 2–7).

At presentation, 25% (7/28) patients did not have deep pain perception. Deep pain perception was regained in 85.7% (6/7) of these cases at discharge. One case (case 16) was euthanized due to development of myelomalacia 3 days after surgery. The follow-up time varied between 2 and 13 weeks. Two cases (cases 5 and 8) were lost to follow-up after discharge. The three cases were excluded from the neurological status statistical analysis. Also, because the outcome in the two cats (low number, different species) could not be

**Table 1** Modified Matthiesen neurological assessment score

Grade	Neurological status
0	No spinal hyperesthesia and no neurological deficits
1	Hyperesthesia, no neurological deficits
2	Proprioceptive deficits and/or ataxia
3	Nonambulatory with purposeful movement
4	No purposeful movement with deep pain sensation
5	Loss of deep pain sensation

**Table 2** The SOP locking plate numbers and sizes' application in 26 dogs and 2 cats

Size of cases	Plate numbers	Size of plates
Small dogs <10 kg or cat	Unilateral (n = 4) Bilateral (n = 10)	2.0 (n = 4) 2.0 (n = 6), 2.7 (n = 4)
Medium dogs 11–26 kg	Bilateral (n = 11)	2.7 (n = 7), 3.5 (n = 4)
Large dogs 27–45 kg	Unilateral (n = 1) Bilateral (n = 2)	3.5 (n = 1) 3.5 (n = 2)

Abbreviation: SOP, String of Pearls.

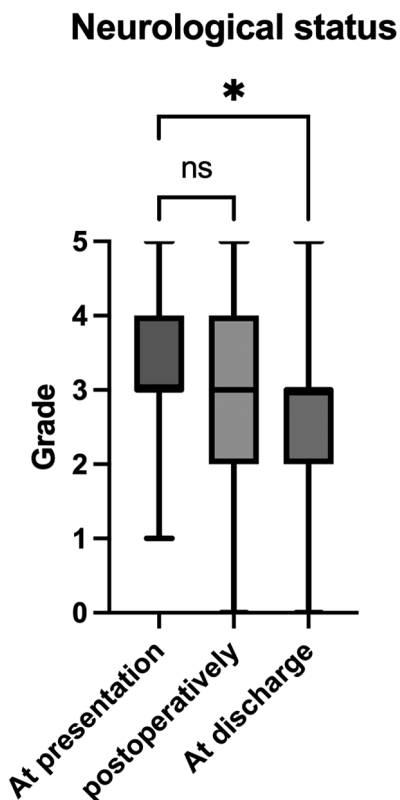
compared to the results obtained in dogs, their conditions were only described but not used in the outcome analysis. The neurological status at discharge ( $p < 0.05$ ) showed significant improvement compared to neurological status at presentation (► **Fig. 3**). The mean duration of hospitalization was 5.9 days (range: 3–11 days).

During peri- and postoperative care, 10 out of 28 cases needed bladder care initially by a urinary catheter or manual expression. At the time of discharge, 4 out of 27 cases lacked voluntary bladder control and needed manual expression. Of these, three had regained urinary continence at recheck. No decubitus ulcer or urine scalding was documented in any of the cases.

Complications were observed in 28.6% (8/28). There was one catastrophic complication (1/28, 3.6%), one major com-

plication (1/28, 3.6%), and six minor complications (6/28, 21.4%). The catastrophic complication (case 16) developed myelomalacia 3 days after surgery and was euthanized. The major complication (case 7) developed surgical-site infection (SSI) that needed surgical debridement. Of the minor complications, one developed surgical-site edema (case 8), surgical-site seroma (case 25), screw loosening (case 1, 14, 19), and surgical-site glial scarring (case 4) that did not require surgical or medical management. Cases 1 and 14 showed screw loosening at 6 to 8 weeks post-surgery and case 19 showed screw breakage at 6-week recheck.

Of the two cats in the study, the causes of injury were dog attack and fall from height and not motor vehicle accident. Both were assessed as having no deep pain perception prior to surgery but regained pain perception and motor function prior to discharge.



**Fig. 3** Neurological status assessment. A total of 25 dogs were included. The Kruskal–Wallis test was utilized to compare the various groups, and subsequently, Dunn's post-hoc test was employed for multiple comparisons. A  $p$ -value of  $< 0.05$  was considered significant for all analyses. The box-and-whisker plots display the median and quartiles. \*Significantly different at  $p$ -value  $< 0.05$ ; ns = no significant difference.

## Discussion

This case series showed that the use of SOP locking plates is a method of stabilizing traumatic injury to thoracolumbar spine in dogs and cats. The patient population in this study exhibited a similar sex and age distribution as the larger spinal trauma case series by Bruce et al.<sup>18</sup> The distribution of trauma causes was also comparable to previous case series.<sup>18</sup>

In our study, 82.1% (23/28) underwent bilateral spinal plating and the median total screw number was four cranially and caudally to the lesion, respectively. In general, plates span two vertebrae on each side of the injury.<sup>19</sup> Placement of lateral SOP locking plates on the dorsolateral aspect of the spine has recently been recommended, with a minimum of three screws cranial and caudal to the fracture.<sup>19</sup> Several biomechanical studies compared the stiffness of the SOP locking plate system, PMMA, and the LCP system in dogs.<sup>20–22</sup> One study evaluated pins and PMMA implants with bilateral SOP locking plates in lumbosacral fractures and reported that both groups provided similar stability, while SOP locking plates have the inherent advantage of avoiding the thermal injuries and the large implant volume of PMMA.<sup>20</sup>

Although no clinical studies have specifically been published using unilateral fixation comparing with bilateral fixation techniques, biomechanical studies have looked at the unilateral versus bilateral different techniques and stiffness.<sup>21</sup> Surgeon choices on specific implant configurations were considerably subjective. In our study, there were only three instances of implant loosening at recheck and none of

these required additional surgical procedures or other intervention therapies. As such, no substantive conclusions could be drawn associating implant configuration to implant failure or major complications.

Surgical treatment, in patients with intact nociception, has resulted in good outcomes for 80 to 90% of dogs and cats with fractured or luxated vertebrae,<sup>2,6</sup> while the prognosis for animals that lack deep pain perception is less certain.<sup>23</sup> The importance of nociception as a prognostic factor dictates careful assessment in spinal fracture patients.<sup>6</sup> The prognosis for functional recovery in patients with fractures or luxations is reported at 12% and may be significantly worse.<sup>6,23</sup> In a retrospective study evaluating prognosis for dogs with vertebral fractures or luxations with absent deep pain in nine dogs at presentation, two dogs underwent surgery and reported that none had returned nociception postoperatively.<sup>23</sup> Multiple factors, including instability, duration of the clinical signs before presentation of the patient, and degree of deformation of the spinal canal, will all be confounding factors. In our study, 25% (7/28) of animals showed no deep pain perception at presentation. After surgery, 85.7% (6/7) of animals regained deep pain at discharge and continued improving neurological function by 3 months. Factors relating to neurological improvement were not evident. One factor relating to neurological improvement reported by Bull et al was body weight, where dogs weighing more than 20 kg had a worse outcome than dogs with less than 20 kg. The weights of dogs in our study were less, with a median body weight of 12.1 kg (range: 2.7–37.2 kg).<sup>24</sup>

Urinary voiding is essential during peri- and postoperative care. In our study, 10 cases lacked voluntary bladder control at presentation. Of these, eight cases eventually regained urinary continence along with deep pain sensation and ambulation at recheck. It is reported that patients who present with deep pain perception in the pelvic limbs usually recover urination concomitantly with the return of motor function, and the prognosis for recovery of urinary continence is good.<sup>25</sup>

Specific peri-operative complications of spinal surgery include hematoma, SSIs, spinal canal violation, nerve root injury, and progressive myelomalacia.<sup>18</sup> Technical complications are generally secondary to inappropriate implant placement, movement of the implant, or implant failure.<sup>18,26</sup> Implant-related complications include screw breakage, implant loosening and failure due to inappropriate implant size or placement, poor bone holding properties, or excess patient mobility.<sup>2,6</sup> In our study, two cases (case 1 and 14) showed screw loosening at 6- to 8-week recheck, and one case (case 19) showed screw breakage at the 6-week recheck. This might be due to the shearing force between the plate–bone and the poor screw–bone purchase. All these cases involved bilateral plating and no clinical signs seemed to be related to the implants. This might indicate that the bone healing process and fixation stability were maintained after the complication occurred.

In our study, a total of 28.6% (8/28) of the cases had complications but only 2 were considered catastrophic or major (7.2%) and included myelomalacia and SSI. In humans,

87% of patients undergoing spinal surgery developed at least one complication.<sup>27</sup> In veterinary surgery, the postoperative complication rate has been reported as 10 out of 37 operated cases.<sup>18</sup> In another study, a 30% postoperative complication rate was reported with 8 dogs and 2 cats using 2–0 UniLock implants for stabilizing traumatic thoracolumbar instability.<sup>12</sup> One study showed no long-term complications in all 10 dogs with congenital thoracic vertebral body malformations treated with unilateral vertebral distraction and stabilization with monocortical screws and PMMA. However, no short-term complications were documented.<sup>28</sup> The other study showed a 33.3% postoperative complication rate in 12 dogs using screws, pins, and PMMA for atlantoaxial stabilization.<sup>29</sup> Vallefucio et al showed a 37.5% short-term complication rate in eight cats using screws and PMMA for thoracolumbar vertebral fractures and luxation stabilization, and no long-term complications were recorded.<sup>30</sup> Although our study showed an overall lower complication rate than previously published studies, the overall complication rate for spinal surgery in dogs and cats may vary depending on the specific procedure performed, the individual patient's health status, and the neurological status at presentation. Therefore, it is important to note that the rate of complications reported herein may not reflect the overall complication rate for all types of spinal surgeries in dogs.

SSI is a less common complication in dogs and cats undergoing spinal surgery.<sup>31</sup> In our study, one dog developed SSI 5 days after surgery, which required surgical debridement and wound drainage. Dyall and Schmökel showed that the SSI rate in dogs undergoing spinal surgery without the use of perioperative antibiotics was 0.6%, while the expected SSI rate in clean operative wounds in dogs and cats was 2.0 to 4.8%.<sup>31</sup> In our study, the SSI rate of 3.6% (1/28) was significantly higher than what was published by Dyall and Schmökel, but still within the published rate for clean procedures in veterinary medicine.<sup>31</sup>

The limitations of the study were primarily related to its retrospective nature, including variations in the documentation of surgery reports, variations in surgeon implant choices, techniques or case management, and varying follow-up time frames for individual cases. Additionally, the study was limited by a relatively small sample size. Future studies with larger sample sizes and a randomized prospective design should be conducted to address these limitations.

## Conclusion

In this retrospective study of 26 dogs and 2 cats, the use of SOP locking plates for the treatment of spinal fractures or luxations was evaluated. The findings indicate that the use of SOP locking plates in traumatic thoracic and lumbar fractures or luxations in dogs and cats yielded successful stabilization and had a 28% incidence of complications, which is comparable to those reported using other methods of spinal transfixation.

## Conflict of Interest

K.K. has a relevant financial interest in the String of Pearl plates.

## References

- 1 Turner WD. Fractures and fracture-luxations of the lumbar spine: a retrospective study in the dog. *J Am Anim Hosp Assoc* 1987; 23:459–464
- 2 Selcer RR, Bubb WJ, Walker TL. Management of vertebral column fractures in dogs and cats: 211 cases (1977–1985). *J Am Vet Med Assoc* 1991;198(11):1965–1968
- 3 Jeffery ND. Vertebral fracture and luxation in small animals. *Vet Clin North Am Small Anim Pract* 2010;40(05):809–828
- 4 Matthiesen DT. Thoracolumbar spinal fractures/luxations: surgical management. *Comp Cont Ed Sm Anim Pract* 1983;5:867–878
- 5 Orgonikova I, Brocal J, Cherubini GB, Palus V. Vertebral fractures and luxations in dogs and cats, part 1: evaluation of diagnosis and prognosis. *Companion Anim* 2021;26(02):1–10
- 6 Weh M, Kraus KH. Spinal fractures and luxations. In: Tobias KM, Johnston SA, eds. *Veterinary Surgery: Small Animal*. 2nd ed. Philadelphia PA: Saunders; 2017:487–503
- 7 Sharp NJH, Wheeler SJ. Trauma. In: Sharp NJH, Wheeler SJ, eds. *Small Animal Spinal Disorders Diagnosis and Surgery*. 2nd ed. London, UK: Elsevier Mosby; 2005:281–318
- 8 LeCouteur RA, Sturgess B. Spinal fractures and luxations. In: Slatter D, ed. *Textbook of Small Animal Surgery*. 3rd ed. Philadelphia PA: Elsevier Science; 2003:1244–1260
- 9 Walker TM, Pierce WA, Welch RD. External fixation of the lumbar spine in a canine model. *Vet Surg* 2002;31(02):181–188
- 10 Tammaro WJ, Early PJ, Bergman R, Petrovsky BL, Kraus KH. Diagnostic traction and dorsal locking plate stabilization of a fifth and sixth thoracic vertebral fracture/luxation in a golden retriever: case report. *Front Vet Sci* 2022;9:1011983
- 11 Klatzkow S, Johnson MD, James M, Carrera-Justiz S. Ventral stabilization of a T2–T3 vertebral luxation via median sternotomy in a dog. *Case Rep Vet Med* 2018;2018:9152394
- 12 Letesson J, Goin B, Trouillet JL, Barthez P. Long-term follow-up of dogs and cats after stabilization of thoracolumbar instability using 2–0 UniLock implants. *Vet Med Int* 2022;2022:5112274
- 13 Segal U, Bar H, Shani J. Repair of lumbosacral fracture-luxation with bilateral twisted string-of-pearls locking plates. *J Small Anim Pract* 2018;59:288–293
- 14 Solano MA, Fitzpatrick N, Bertran J. Cervical distraction-stabilization using an intervertebral spacer screw and string-of-pearl (SOP) plates in 16 dogs with disc-associated wobbler syndrome. *Vet Surg* 2015;44(05):627–641
- 15 Schmitt EM, Early P, Bergman R, et al. Computed tomography evaluation of proposed implant corridors in canine thoracic vertebrae. *Vet Surg* 2021;50(07):1427–1433
- 16 Mullins RA, Espinel Ruperéz J, Bleedorn J, et al. Accuracy of pin placement in the canine thoracolumbar spine using a free-hand probing technique versus 3D-printed patient-specific drill guides: an ex-vivo study. *Vet Surg* 2023;52(05):648–660
- 17 Cook JL, Evans R, Conzemius MG, et al. Proposed definitions and criteria for reporting time frame, outcome, and complications for clinical orthopedic studies in veterinary medicine. *Vet Surg* 2010; 39(08):905–908
- 18 Bruce CW, Brisson BA, Gyselinck K. Spinal fracture and luxation in dogs and cats: a retrospective evaluation of 95 cases. *Vet Comp Orthop Traumatol* 2008;21(03):280–284
- 19 Hettlich BF. Spinal fractures and luxations. In: Barnhart MD, Maritato KC, eds. *Locking Plate in Veterinary Orthopedics*. Hoboken, NJ: John Wiley & Sons; 2019:155–163
- 20 Nel JJ, Kat CJ, Coetzee GL, van Staden PJ. Biomechanical comparison between pins and polymethylmethacrylate and the SOP locking plate system to stabilize canine lumbosacral fracture-luxation in flexion and extension. *Vet Surg* 2017;46(06):789–796
- 21 Sturges BK, Kapatkin AS, Garcia TC, et al. Biomechanical comparison of locking compression plate versus positive profile pins and polymethylmethacrylate for stabilization of the canine lumbar vertebrae. *Vet Surg* 2016;45(03):309–318
- 22 Early PJ, Maller A, Kraus KH. Stiffness comparisons of SOP interlocking plate configurations in 3D printed canine lumbosacral vertebrae. *Vet Sci Res*. 2017;2(04):000144
- 23 Olby N, Levine J, Harris T, Muñana K, Skeen T, Sharp N. Long-term functional outcome of dogs with severe injuries of the thoracolumbar spinal cord: 87 cases (1996–2001). *J Am Vet Med Assoc* 2003;222(06):762–769
- 24 Bull C, Fehr M, Tipold A. Bandscheibenvorfälle beim hund: retrospektive studie über den klinischen verlauf von 238 hunden (2003–2004). *Berl Munch Tierarztl Wochenschr* 2008;121(01): 10–21
- 25 Shaw TA, De Risio L, Laws EJ, Rose JH, Harcourt-Brown TR, Granger N. Prognostic factors associated with recovery of ambulation and urinary continence in dogs with acute lumbosacral spinal cord injury. *J Vet Intern Med* 2017;31(03):825–831
- 26 Castel A, Olby NJ, Mariani CL, Muñana KR, Early PJ. Clinical characteristics of dogs with progressive myelomalacia following acute intervertebral disc extrusion. *J Vet Intern Med* 2017;31(06): 1782–1789
- 27 Street JT, Lenehan BJ, DiPaola CP, et al. Morbidity and mortality of major adult spinal surgery. A prospective cohort analysis of 942 consecutive patients. *Spine J* 2012;12(01):22–34
- 28 Farré Mariné A, De Risio L, Mascort J, et al. Transthoracic vertebral distraction and stabilization in 10 dogs with congenital thoracic vertebral malformations. *Vet Comp Orthop Traumatol* 2021;34 (05):367–374
- 29 Sanders SG, Bagley RS, Silver GM, Moore M, Tucker RL. Outcomes and complications associated with ventral screws, pins, and polymethyl methacrylate for atlantoaxial instability in 12 dogs. *J Am Anim Hosp Assoc* 2004;40(03):204–210
- 30 Vallefucio R, Manassero M, Leperlier D, Scotti S, Viateau V, Moissonnier P. Surgical repair of thoraco-lumbar vertebral fracture-luxations in eight cats using screws and polymethylmethacrylate fixation. *Vet Comp Orthop Traumatol* 2014;27(04): 306–312
- 31 Dyall BAR, Schmökkel HG. Surgical site infection rate after hemilaminectomy and laminectomy in dogs without perioperative antibiotic therapy. *Vet Comp Orthop Traumatol* 2018;31(03): 202–213