



Accessory Penile Frenulum: May Go Unnoticed throughout the Journey to Graveyard

Sunil Kumar Rout¹  Gulshan Patel²

¹Department of Plastic and Reconstructive Surgery, Kalinga Institute of Medical Sciences, Bhubaneswar, Odisha, India

²Department of General Surgery, Kalinga Institute of Medical Sciences, Bhubaneswar, Odisha, India

Address for correspondence Sunil Kumar Rout, MCh, A - 104, Infocity Greens Apartment, Sailashree Vihar, Bhubaneswar 751021, Odisha, India (e-mail: drsunilrout@rediffmail.com).

Indian J Plast Surg 2025;58:73–75.

Abstract

An accessory frenulum of the penis is so rare that only four cases have been documented so far. We came across a case of 45-year-old, sexually active man who sought medical attention for right foot injury caused by a road traffic accident. During a detailed clinical evaluation, he was discovered to have double frenulum in his penis. Along with the normal ventral frenulum he had an additional dorsal frenulum located at the 10 O'clock position. No history of penile torsion could be elicited from the patient. He had completed his family by the time of presentation, without any symptom of sexual dysfunction or dyspareunia. He was not offered any treatment for this congenital anomaly as it did not have any functional or aesthetic implication. A literature review was conducted to determine the incidence, spectrum of clinical presentation, and management of this pathology.

Keywords

- ▶ accessory penile frenulum
- ▶ congenital anomaly of penis
- ▶ dorsal penile frenulum
- ▶ pseudo-frenulum

Introduction

An accessory penile frenulum is an extremely rare congenital anomaly.^{1–4} This is characterized by the presence of two bands of tissue connecting the glans penis to the foreskin or the shaft of the penis with primary ventral frenulum and the other, at some other point along the corona glandis. This anatomical variation may remain asymptomatic and go unnoticed. But in some cases, it may cause pain during erection and sexual dysfunction. We came across a patient with paired penile frenulum observed coincidentally while treating him for trauma to the lower limb. In this report, we present the case with a literature review on this subject.

Anatomy of Prepuce and Frenulum

The prepuce is a normal anatomical covering of the glans.⁵ The embryologic development of the frenulum is related to the formation of the prepuce.^{3,5} The penile skin and prepuce are formed by 8 weeks of intrauterine life, by reduplication of the ectoderm. Then the space between the prepuce and the glans is formed, known as the preputial sac. The frenulum is the result of residual adhesions of the ectoderm on the ventral aspect of the penis between the inner prepuce and the glans penis. During preputial sac formation, the inner mucosa separates from the glans penis. When it fails to separate from the glans at some point other than the ventral midline, it results in an additional or accessory frenulum.

article published online
August 16, 2024

DOI <https://doi.org/10.1055/s-0044-1788811>.
ISSN 0970-0358.

© 2024. Association of Plastic Surgeons of India. All rights reserved. This is an open access article published by Thieme under the terms of the Creative Commons Attribution-NonDerivative-NonCommercial-License, permitting copying and reproduction so long as the original work is given appropriate credit. Contents may not be used for commercial purposes, or adapted, remixed, transformed or built upon. (<https://creativecommons.org/licenses/by-nc-nd/4.0/>)
Thieme Medical and Scientific Publishers Pvt. Ltd., A-12, 2nd Floor, Sector 2, Noida-201301 UP, India

Dorsal midline is the most commonly observed site for such additional frenula.³ There can be congenital torsion of the penis, which may result in shifting of the frenulum along with the external meatus clockwise or counterclockwise, with the latter being more common.⁶

Case Report

A 45-year-old man presented to our hospital to receive treatment for an injury to his right lower limb sustained in a road traffic accident. During preparation for reconstructive surgery, after administration of spinal anesthesia inside the operation room, he was observed to have a dorsal frenulum of the penis. There was a "V"-shaped band connecting the shaft of the penis to glans at the 10 o'clock position (►Fig. 1). Curiosity led us to examine the penis in detail to rule out any other abnormality in the organ. Clinical evaluation revealed a normal ventral frenulum at the 6 o'clock position (►Fig. 2), and normal external urethral meatus, glans, and shaft of the penis. There was no torsion of the penis and it displayed absolutely normal anatomy except the accessory dorsal frenulum. No scar or pigmentation of skin over any part of the penis was noticed. It was present since birth and he did not undergo circumcision so far, as informed by the patient. He also informed a normal flow and stream of urine during micturition. The patient had already completed his family and did not have any experience of sexual dysfunction. He did not show any interest for treatment of this abnormal dorsal band. Hence, no treatment was offered for this congenital anomaly. Based on these observations, the patient was diagnosed to have an accessory penile frenulum or pseudo-frenulum.

Discussion

An accessory penile frenulum is an extremely rare congenital anomaly.^{1,2} Only four cases have been reported so far in the

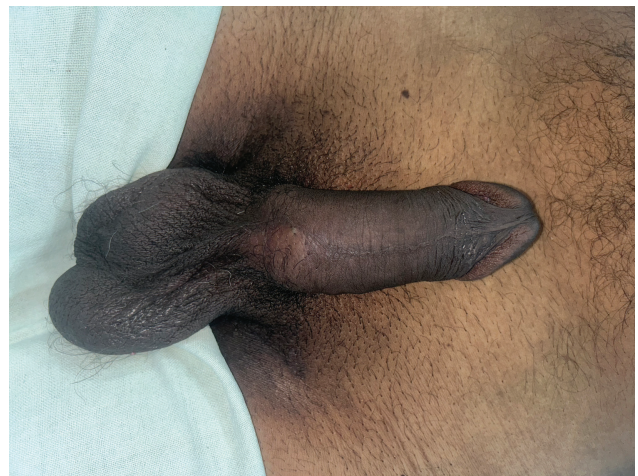


Fig. 2 A normal ventral frenulum at the 6 o'clock position.

published literature.¹⁻⁴ The first case of a solitary dorsal penile frenulum was reported from India, without any other associated abnormality in the penis.⁷ Being mostly asymptomatic and the organ rarely exposed, under-reporting of these cases could be a possibility. The cause of this deformity is not known and thought to result from aberrant embryological development. It may remain asymptomatic or may present with erectile discomfort, difficulty in retraction of the prepuce, and dyspareunia. Our case was asymptomatic and it was noticed coincidentally while receiving treatment for lower limb trauma. Although this anomaly has been reported previously as an accessory penile frenulum, the band may be termed as pseudo-frenulum because this is not connecting the shaft of the penis to the glans at any embryological fusion line. The anatomical location of the accessory frenulum was the dorsal midline in all cases, except the one reported by Goyal and Gupta.² In that case, the accessory frenulum was at the 10 o'clock position, as in our case. Their patient was an adolescent who presented with a complaint of occasional painful penile erection during sleep, painful enough to wake him up, and he was unhappy with the appearance of his penis. However, our patient was a middle-aged man, did not have any symptoms, the anomaly was detected coincidentally, and he had no sexual dysfunction. Hence, he did not have any interest in the treatment of the condition. A normal ventral frenulum provides an erogenous sensation and stability to the glans during erection, whereas none of the cases reported including ours had any functional implication.

There is a possibility for this band to be confused with acquired bands, which may result from mechanical trauma, surgery, or thermal injuries. However, such acquired lesions must have a history suggestive of an etiological role. Associated findings like hypo- or hyperpigmentation over the surrounding areas and scar of the surgical or traumatic wounds either healed by primary or secondary intention may be present in cases of acquired lesions. Other deformities like contracture with resultant pain during erection or dyspareunia may be experienced in these cases.

Management of this condition varies from masterly inactivity to definitive surgical correction. Asymptomatic cases may not



Fig. 1 An accessory penile frenulum present at the 10 o'clock position.

require any treatment unless the patient is concerned about the aesthetic appearance of the organ as in our case and the one reported by Mukendi and Doherty.⁴ Difficulty in retraction of the prepuce and resultant dyspareunia may be relieved by frenuloplasty. If the condition is associated with penile torsion, surgical correction needs extensive dissection of Buck's fascia and release of torsion in addition to frenuloplasty.⁷

Conclusion

An accessory penile frenulum is a rare congenital anomaly of the penis that may be present over the dorsal midline or dorsolaterally. Surgical treatment of this condition is predominantly determined by the resultant symptom and patient preference.

Funding

None.

Conflict of Interest

None declared.

References

- 1 Kumar M, Sharma S, Kumar M, et al. Dorsal and ventral frenulum in an uncircumcised young male: an extremely rare case report and review of literature. *Indian J Surg* 2023 (e-pub ahead of print). Doi: 10.1007/s12262-023-03949-z
- 2 Goyal SK, Gupta S, Gupta S. Double-penile frenulum: an unusual developmental anomaly. *Curr Med Issues* 2020;18:332–333
- 3 Arora B. Dorsal penile frenulum: a rare developmental abnormality. *Int J Case Rep Imag* 2016;7(05):311–313
- 4 Mukendi AM, Doherty SW. Dorsal penile frenulum: a rare congenital abnormality. *Afr J Urol* 2019;25:1–3
- 5 Yiee JH, Baskin LS. Penile embryology and anatomy. *Scientific-WorldJournal* 2010;10:1174–1179
- 6 Shaeer O. Torsion of the penis in adults: prevalence and surgical correction. *J Sex Med* 2008;5(03):735–739
- 7 Singla SL, Garg P, Bishnoi PK, Singh B. Dorsal penile frenulum. *Urol Int* 1997;59(01):55–56