



Computed Tomography Scan Correlation of Position of Appendix with Present Literature

Manohar Kachare¹ Abhijit D. Patil¹ Shanta A. Gamanagatti¹ Sanjay B. Kulkarni²

¹Department of Radiodiagnosis, Government Medical College and Hospital, Miraj, Maharashtra, India

²Department of Surgery, Vishrambag Hospital, Sangli, Maharashtra, India

Address for correspondence Manohar Kachare, MD Rad., EDIR, Diplomate of ICRI, D Ortho, Department of Radiodiagnosis, Government Medical College and Hospital, Pandharpur Road GMC Campus, Miraj 416410, Maharashtra, India (e-mail: manoharkachare4100@gmail.com).

J Gastrointestinal Abdominal Radiol ISGAR

Abstract

Background The appendix exhibits varied anatomical orientations, which significantly influence the diagnosis and treatment of appendicitis. Existing literature predominantly relies on cadaveric studies to delineate common appendix positions, lacking comprehensive computed tomography (CT)-based investigations on a large scale. Thus, our study endeavors to delineate the prevailing position of the appendix on CT scans and ascertain its concordance with existing literature, thereby augmenting our understanding of this anatomical entity. This cross-sectional study was conducted in a tertiary care hospital setting.

Materials and Methods A total of 1,068 patients aged 18 years and older, undergoing abdominal CT scans at the hospital between July 2020 and July 2021, were enrolled in the study, with exclusion criteria applied to conditions that could distort anatomical features. The position of the appendix was meticulously documented for each patient, alongside measurements including diameter, wall thickness, and origin. Data collection utilized a predefined Microsoft Excel sheet. Subsequently, numerical and relative frequencies were computed for appendiceal positions and origins. Additionally, diameter and wall thickness were assessed, and pertinent parameters were derived.

Results The relative frequencies of various potential appendiceal positions observed in our study were as follows: subcecal: 6.6%; paracecal: 1.2%; pelvic: 21.9%; postileal: 32.9%; preileal: 6.7%; retrocecal: 28.5%; subhepatic: 2.2%.

Conclusion In contrast to traditional assumptions, our findings reveal that the most prevalent positions of the appendix are postileal, retrocecal, and pelvic, challenging historical beliefs.

Keywords

- ▶ appendix
- ▶ positions
- ▶ MDCT
- ▶ in vivo

Introduction

The appendix, part of the gastrointestinal system, typically resides in the right iliac fossa. As a vestigial structure, the vermiform appendix emerges during the developmental phase from the cecum, exhibiting a remarkably diverse anatomical location.

The appendix can assume various positions within the abdomen, deviating from its typical location in the lower right quadrant. These atypical positions can result in atypical clinical symptoms that may not align with the classic presentation of appendicitis.^{1,2} In pelvic appendicitis, suprapubic pain and urinary frequency may predominate, and positive rectal or vaginal tenderness and obturator signs are

DOI <https://doi.org/10.1055/s-0044-1788261>.
ISSN 2581-9933.

© 2024. The Author(s).

This is an open access article published by Thieme under the terms of the Creative Commons Attribution License, permitting unrestricted use, distribution, and reproduction so long as the original work is properly cited. (<https://creativecommons.org/licenses/by/4.0/>)

Thieme Medical and Scientific Publishers Pvt. Ltd., A-12, 2nd Floor, Sector 2, Noida-201301 UP, India

common. Similarly, cases of subhepatic appendicitis can present with pain in the right upper quadrant and epigastric region in sharp contrast to the right lower quadrant pain typically seen in a more commonly placed appendix.³ Therefore, understanding the spectrum of appendiceal positional variations assumes paramount importance, particularly in cases where appendicitis manifests with atypical clinical features.^{4,5} In such patients, imaging studies play a significant role in preoperative diagnosis and to guide the laparoscopic surgeons in planning the proper treatment.⁶

Despite postmortem studies and conventional surgical and anatomical textbooks commonly citing retrocecal as the most prevalent position, such assertions warrant empirical validation.⁷⁻¹¹ Hence, our study endeavors to delineate the prevailing position of the appendix on computed tomography (CT) scans and ascertain its concordance with existing literature, thereby augmenting our understanding of this anatomical entity.

Materials and Methods

This cross-sectional study was conducted with approval from the institutional ethics committee. The requirement for obtaining consent has been waived by the institutional ethics committee, given that we are acquiring anonymized data for a cross-sectional study.

Selection and Description of Participants

All patients referred for abdominal CT scans, whether plain or plain and contrast studies, from various clinical departments and who have given consent, were eligible for inclusion in

this study. To ensure robustness, we calculated the minimum sample size required to be 1,068, employing a population proportion of 0.5 and an absolute precision of 0.03.

Inclusion criteria stipulated that patients must be aged 18 years and above. Exclusion criteria encompassed patients with disseminated abdominal malignancies, infections, or trauma causing anatomical distortion, intra-abdominal pathologies exerting a mass effect on the right colon, malrotation of the gut, and individuals who had previously undergone appendectomy.

Technical Information

Imaging procedures were performed in elective patients on Somatom Definition AS+ 128 slice multidetector computed tomography (MDCT) scanner (Siemens Medical Solutions, Forchheim, Germany). Patients were kept fasting for 4 hours prior to the scan. Premedication, including Perinorm 2 mL (metoclopramide 10 mg) and Avil 1 mL (pheniramine maleate 22.75 mg) was given intravenously (IV) to avoid contrast-induced allergic reactions. IV methylprednisolone was given to patients with a history of allergies. Patients were briefed in their vernacular language regarding machine instructions for breath holding and contrast injection via the pressure injector.

The scan was acquired according to the following protocol (► **Table 1**).

Image Interpretation

The images were analyzed by two radiologists in consensus, each having a minimum of 5 years of experience in abdominal imaging. The appendix was traced along its entire length,

Table 1 Scan protocol

Patient position	Supine position, head first, on the gantry table, with their hands placed above the head and abdomen centered within the gantry
Tube voltage (kVp)	140
Tube current (mAs)	220
Pitch	0.6
Gantry speed	0.5 s per rotation
Scan extent	From the dome of the diaphragm to the coccyx
Scan direction	Craniocaudal
Field of view	350–400 mm
Slice thickness	5 mm (1.5-mm-thick reconstruction for plain scans and 1-mm reconstruction for contrast scans)
Slice interval	1 mm
Reconstruction algorithm	Kernel B30f smooth
Oral contrast	800 mL of water 1 hour before the scan, followed by a table dose of 200 mL of water just before the scan
Intravenous contrast	<ol style="list-style-type: none"> 1. Noncontrast scan 2. Biphasic arterial and venous acquisition <ul style="list-style-type: none"> • Contrast volume: 2 mL/kg nonionic iodinated contrast injected at a speed of 4 mL/s through a pressure injector (Medrad, United States) • Bolus tracking: abdominal aorta • Arterial phase: after a delay of 6 s following bolus tracking • Venous phase: after a delay of 40 s from bolus tracking <p>Subsequently, axial, sagittal, and coronal–multiplanar images were reconstructed in kernel B30f smooth and reviewed in soft tissue window</p>

from origin to tip. Key parameters including the location of the ostium, diameter, wall thickness, and position based on the tip's location were recorded. The ostium of the appendix was characterized based on its origin from the cecal wall, categorized as anterior, posterior, lateral, medial, or inferior. Wall thickness was measured at the maximum diameter of the appendix.

The position of the appendix was categorized as follows: (1) retrocecal or retrocolic position (posterior to the cecum or the lower ascending colon, or both) (►Figs. 1, 2A), (2) pelvic or descending position (suspended over the pelvic brim) (►Figs. 1, 2B), (3) subcecal location (below the cecum) (►Figs. 1, 2C), (4) preileal position (anterior to the terminal ileum) (►Figs. 1, 2D), (5) postileal position (posterior to the terminal ileum) (►Figs. 1, 2E), (6) paracecal position (adjacent to the cecum) (►Figs. 1, 2F), and (7) subhepatic position (►Fig. 2G).

Statistical Analysis

Data were systematically collected in a predesigned Microsoft Excel spreadsheet. Subsequently, the numbers and relative frequencies of appendiceal positions and origins were computed. Diameter and wall thickness measurements were recorded for each patient. Furthermore, the mean and range of appendix diameter and appendiceal wall thickness were calculated.

Results

A total of 1,068 patients were enrolled in the study. There were 624 men and 444 women. The age range was 18 to 76 years. The median age was 48 years.

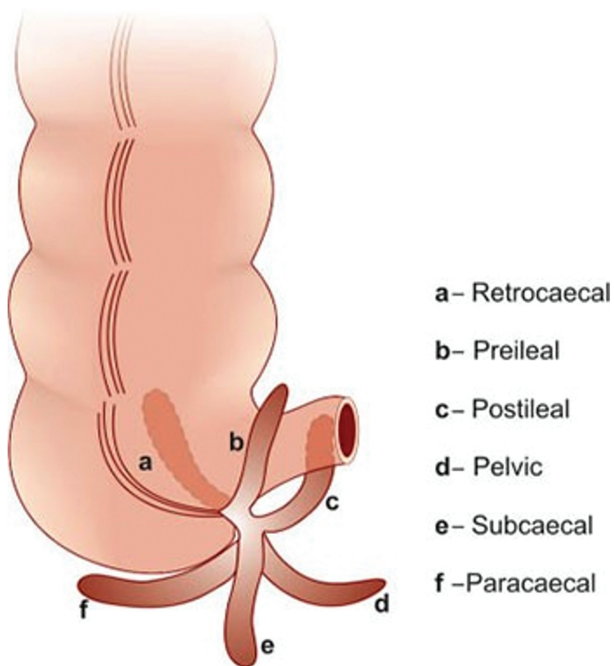


Fig. 1 Various positions of appendix in relation to cecum and terminal ileum.

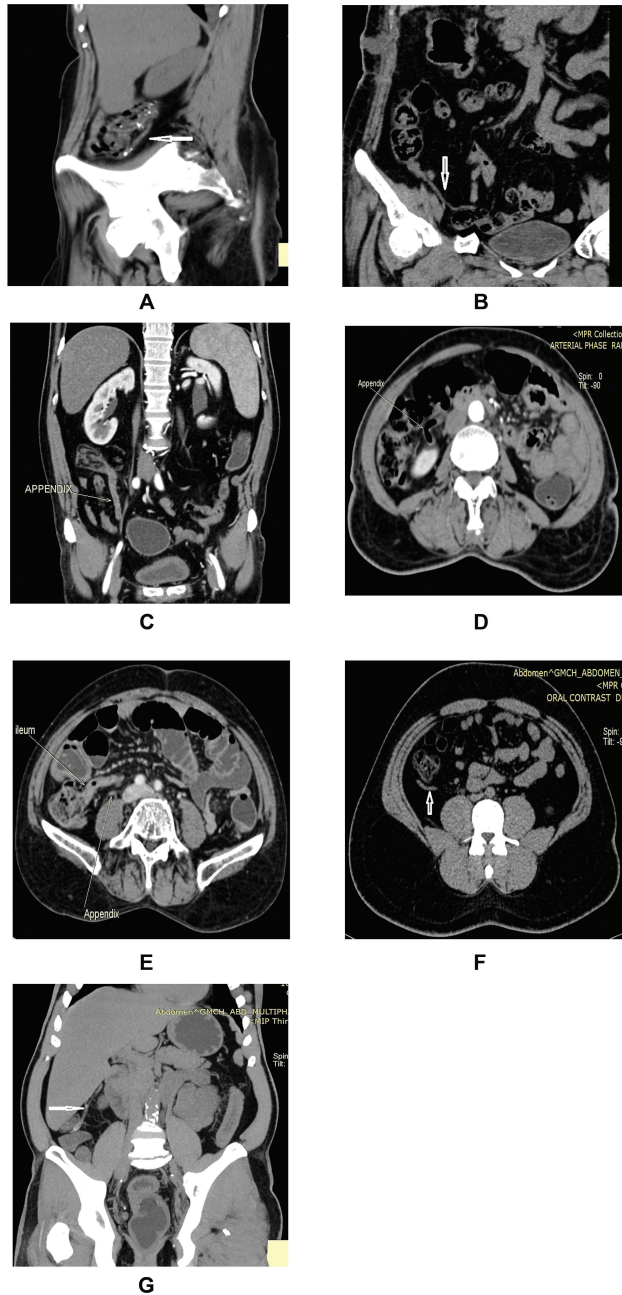


Fig. 2 Appendiceal positions as seen on computed tomography. (A) Right (Rt) parasagittal reconstruction shows retrocecal appendix (arrow). (B) On coronal section pelvic appendix (arrow) is seen hanging over Rt iliac vessels. (C) Coronal section shows appendix in subcecal position. (D) A preileal appendix is seen on axial section. (E) Axial section shows a postileal appendix passing superiorly behind terminal ileum. (F) The paracecal appendix is seen on axial section. (G) A coronal maximum intensity projection shows appendix in subhepatic location.

Among these 1,068 cases, 71 appendices (6.6%) were subcecal, 13 (1.2%) were paracecal, 234 (21.9%) were in the pelvic region, 351 (32.9%) were postileal, 72 (6.7%) were preileal, 304 (28.5%) were retrocecal, and 23 (2.2%) were subhepatic (►Table 2).

Regarding the origin of the appendix (►Table 3), the most common was found to be posteromedial, in 638 cases (59.7%). Other origins exhibited the following distribution:

Table 2 Frequency distribution of in vivo position of appendix

Position of appendix	Frequency	%
Subcecal	71	6.6
Paracecal	13	1.2
Pelvic	234	21.9
Postileal	351	32.9
Preileal	72	6.7
Retrocecal	304	28.5
Subhepatic	23	2.2
Total	1,068	100

Table 3 Frequency distribution of origin of appendix

Origin of appendix	Frequency	%
Anterior	1	0.1
Inferior	68	6.4
Inferomedial	11	1.00
Lateral	1	0.1
Medial	224	20.9
Posterior	124	11.6
Posteromedial	638	59.7
Postileal	1	0.1
Total	1,068	100

1 (0.1%) anterior, 68 (6.4%) inferior, 11 (1%) inferomedial, 1 (0.1%) lateral, 224 (21%) medial, 124 (11.6%) posterior, and 1 (0.1%) postileal.

In our study, the mean maximum outer diameter of the appendix was determined to be 5.31 ± 1.2 mm, with a range of 1.3 to 15 mm. Notably, 235 patients (22%) displayed a diameter exceeding 6.0 mm.

The mean appendiceal wall thickness was calculated as 1.68 ± 0.6 mm, ranging from 0.5 to 7 mm. Of significance, only 39 appendices (3.7%) exhibited a wall thickness surpassing 3.0 mm.

Discussion

In Wakeley's anatomopathological examination of 10,000 deceased subjects,⁷ the vermiform appendix exhibited retrocecal and retrocolic positioning in 65.28% of cases, pelvic placement in 31.01%, subcecal positioning in 2.26%, preileal positioning in 1%, and postileal positioning in 0.4%.

Studies utilizing CT scans have revealed that the prevailing positions of the appendix include the retroileal,^{9,10} deep pelvic,^{11,12} or subcecal types.¹² Lee et al¹² conducted an investigation involving 1,157 subjects to ascertain the in vivo location of the vermiform appendix via MDCT scans. Their findings challenged the conventional belief that the retrocecal appendix is the most frequent, instead indicating a

higher incidence of the appendix in subcecal and deep pelvic positions. Moreover, they noted that the relative frequency of various appendix positions can vary based on patient gender and pathological conditions.

Similarly, Willekens et al¹³ examined 186 individuals undergoing abdominal CT scans without suspicion of acute appendicitis. Their analysis revealed that the pelvic location accounted for 66% of appendices, underscoring the variability in appendix positioning observed across studies and patient populations.

Oh et al¹⁴ conducted an assessment of normal appendices using MDCT scans in 427 consecutive adult patients. They categorized the positions of normal appendices into five types: type I (postileal and medial paracecal), type II (subcecal), type III (retrocecal and retrocolic or laterocolic), type IV (preileal and medial colic), and type V (lower pelvic cavity). Their analysis revealed the frequency of these types as follows: type I ($n = 187$; 44%), type II ($n = 78$; 18%), type III ($n = 92$; 22%), type IV ($n = 39$; 9%), and type V ($n = 31$; 7%).

Similarly, Picken et al¹⁵ investigated the normal vermiform appendix in 100 patients undergoing abdominal CT scans, finding it predominantly situated in a retroileal position.

Moreover, recent studies employing various medical imaging techniques and laparoscopy have produced findings that challenge historical conventions regarding the position of the appendix, as highlighted in several recent studies.^{13,14,16}

Peletti and Baldisserotto¹⁶ conducted a study involving 107 children who underwent gray-scale ultrasound (USG) scanning. They classified normal and abnormal appendices with the following distributions: 54.4 and 39.3% were located in the midpelvic region, 27.2% and 28.6% were retrocecal, 11.4% and 17.8% were deep pelvic, and 6.8% and 14.3% were abdominal.

Yabunaka et al¹⁷ evaluated 788 adult patients with normal appendices using sonography. They categorized the appendix locations based on the appendiceal tip, identifying it as abdominal in 37 (9.5%) cases, pelvic in 291 (75%), retrocecal in 23 (6.0%), and exhibiting a midline extension in 37 (9.5%).

In a laparoscopic study involving 303 adults, Ahmed et al¹⁸ concluded that the position of the vermiform appendix was pelvic in 155 (51.2%) patients, preileal in 9 (3.0%), paracecal in 11 (3.6%), postileal in 67 (22.1%), and retrocecal in 61 (20.1%) patients.

Providing preoperative information to the surgeon regarding the location of the inflamed appendix facilitates preoperative planning for appropriate incisions in open appendectomy, thereby reducing the incidence of postoperative complications such as pain, hematoma, and incision site hernia.¹⁹ However, in laparoscopic appendectomy, while knowledge of the appendix's location may contribute to reduced operative time and less aggressive search efforts, its importance may be relatively diminished.^{12,20}

CT scans have demonstrated superior diagnostic performance compared with USG in assessing the appendix.^{21,22} Standard abdominopelvic CT with IV contrast, with or without oral and rectal contrast, is the preferred investigative modality.^{13,21}

The comparison of previous studies has been hindered by differing classifications and definitions. In our study, we considered seven appendiceal positions, including six originally described by Wakeley et al. Our findings reveal that the postileal, retrocecal, and pelvic positions are the most common, with subcecal, paracecal, preileal, and subhepatic positions being less frequent.

Twenty-two percent (235 patients) exhibited an appendiceal diameter exceeding 6 mm, aligning with findings from the study by Willekens et al,¹³ indicating that a 6.0 mm diameter alone may not suffice for diagnosing appendicitis in the absence of other CT indicators.

However, only 3.7% of patients displayed a wall thickness surpassing 3.0 mm, suggesting that a wall thickness > 3.0 mm might serve as a more reliable indicator of inflammation, necessitating further validation.

The predominant origins of the appendix were posteromedial (59.73%), medial (21%), and posterior (11.61%), whereas anterior, inferior, inferomedial, lateral, and postileal origins were less frequent. During development, the appendiceal origin undergoes counter-clockwise rotation, resulting in the prevalence of posteromedial, medial, and posterior origins.⁷

Conclusion

Contrary to traditional teachings, the common positions of the appendix observed in vivo on MDCT are, in descending order of prevalence, postileal, retrocecal, and pelvic with other locations being less common. Additionally, the current study elucidates a significant variance in the diameters of the appendix among cases of appendicitis, a finding incongruous with the existing 6-mm threshold utilized in diagnosing acute appendicitis. Consequently, this underscores the necessity for further investigations aimed at establishing a revised diagnostic cutoff for acute appendicitis.

Informed Consent

Informed consent was obtained from all participants and assured that no identification would be revealed.

Consultation Fees and Patents

There are no consultation fees or other forms of remuneration from organizations that may gain or lose financially and patents or patent applications whose value may be affected by the publication of this article.

Ethical Standards

The authors assert that all procedures contributing to this work comply with the ethical standards of the relevant national and institutional guidelines on human experimentation and with the Helsinki Declaration of 1975, as revised in 2008. The study was approved by the Institutional Ethics Committee.

Funding

None.

Conflict of Interest

None declared.

References

- Randal Bollinger R, Barbas AS, Bush EL, Lin SS, Parker W. Biofilms in the large bowel suggest an apparent function of the human vermiform appendix. *J Theor Biol* 2007;249(04):826–831
- Moris D, Paulson EK, Pappas TN. Diagnosis and management of acute appendicitis in adults: a review. *JAMA* 2021;326(22):2299–2311
- Yu D, Gu C, Zhang S, Yang H, Yao T. Ultrasound features and the diagnostic strategy of subhepatic appendicitis. *Ann Transl Med* 2020;8(17):1083
- Alzaraa A, Chaudhry S. An unusually long appendix in a child: a case report. *Cases J* 2009;2(01):7398
- Ting JY, Farley R. Subhepatically located appendicitis due to adhesions: a case report. *J Med Case Rep* 2008;2(01):339
- Wong CH, Trinh TM, Robbins AN, Rowen SJ, Cohen AJ. Diagnosis of appendicitis: imaging findings in patients with atypical clinical features. *AJR Am J Roentgenol* 1993;161(06):1199–1203
- Wakeley CP. The position of the vermiform appendix as ascertained by an analysis of 10,000 cases. *J Anat* 1933;67(Pt 2):277–283
- Richmond B. The appendix. In: Townsend CM, Evers BM, Beachamp RD, Mattox KL, Sabiston Textbook of Surgery: The Biological Basis of Modern Surgical Practice, 1st South Asia Edition. Philadelphia: Elsevier Saunders; 2016:1296
- Prystowsky JB, Pugh CM, Nagle AP. Current problems in surgery. Appendicitis. *Curr Probl Surg* 2005;42(10):688–742
- Chaurasia BD. Small and large intestine. In, Krishna Garg. BD Chaurasia's Human Anatomy, 8th ed., New Delhi: CBS Publishers and distributors Pvt. Ltd.; 2020; volume 2, 316.
- Lunniss PJ. Large intestine. In: Standring S. *Grey's Anatomy: The Anatomical Basis Of Clinical Practise*. 41st ed., Elsevier; 2016:1142
- Lee SL, Ku YM, Choi BG, Byun JY. In vivo location of the vermiform appendix in multidetector CT. *J Korean Soc Radiol* 2014;70(04):283–289
- Willekens I, Peeters E, De Maeseneer M, de Mey J. The normal appendix on CT: does size matter? *PLoS One* 2014;9(05):e96476
- Oh KJ, Cho JS, Shin KS, et al. Normal appendix in adults: MDCT findings about the location, thickness and the presence or absence of intraluminal gas. *J Korean Radiol Soc* 2006;55(04):373–379
- Picken G, Ellis H, Dixon AK. The normal vermiform appendix at computed tomography: visualization and anatomical location. *Clin Anat* 1993;6(01):9–14
- Peletti AB, Baldisserotto M. Optimizing US examination to detect the normal and abnormal appendix in children. *Pediatr Radiol* 2006;36(11):1171–1176
- Yabunaka K, Katsuda T, Sanada S, Fukutomi T. Sonographic appearance of the normal appendix in adults. *J Ultrasound Med* 2007;26(01):37–43, quiz 45–46
- Ahmed I, Asgeirsson KS, Beckingham IJ, Lobo DN. The position of the vermiform appendix at laparoscopy. *Surg Radiol Anat* 2007;29(02):165–168
- Moneer MM. Avoiding muscle cutting while extending McBurney's incision: a new surgical concept. *Surg Today* 1998;28(02):235–239
- Chan WT, Cheng NHY, Cheng KC, et al. Does appendix position affect the clinical outcome of acute appendicitis? *Ann Coll Surg Hong Kong* 2002;6:109–112
- Wise SW, Labuski MR, Kasales CJ, et al. Comparative assessment of CT and sonographic techniques for appendiceal imaging. *AJR Am J Roentgenol* 2001;176(04):933–941
- Balthazar EJ, Birnbaum BA, Yee J, Megibow AJ, Roshkow J, Gray C. Acute appendicitis: CT and US correlation in 100 patients. *Radiology* 1994;190(01):31–35