



Hepatic Peliosis and Hemorrhage after Anabolic Steroid Abuse

Kausthubh Hegde¹ Patrick D. Sutphin¹ Thomas J. An¹ Sanjeeva P. Kalva¹

¹Division of Interventional Radiology, Department of Radiology, Massachusetts General Hospital and Harvard Medical School, Boston, Massachusetts, United States

Address for correspondence Kausthubh Hedge, MBBS, Division of Interventional Radiology, Department of Radiology, GRB-290 Massachusetts General Hospital, 55 Fruit Street, Boston, MA 02114, United States (e-mail: khegde@mgh.harvard.edu).

J Gastrointestinal Abdominal Radiol ISGAR

Abstract

Anabolic steroid abuse has become prevalent in modern society, with many athletes and bodybuilders using these substances for their performance-enhancing effects. A significant concern related to anabolic steroid abuse is the potential development of androgen-associated liver tumors such as hepatocellular carcinoma and adenomas. Anabolic steroid abuse has also been associated with hepatic vascular abnormalities like hepatic peliosis, a rare condition characterized by blood-filled cavities within the liver parenchyma. Hepatic peliosis can present with nonspecific symptoms or remain asymptomatic, making it difficult to diagnose without appropriate imaging studies. In this case report, the authors describe the imaging findings and management of two patients with intrahepatic bleeding associated with anabolic steroid consumption.

Keywords

- ▶ adenoma
- ▶ anabolic steroid abuse
- ▶ hemorrhage
- ▶ hepatic peliosis
- ▶ liver

Introduction

Anabolic steroid abuse for performance enhancement is prevalent among athletes. Hepatic complications of anabolic steroids include jaundice, cholestasis, elevation of liver enzymes, benign hepatic adenomas, and hepatocellular carcinoma.^{1,2} Vascular complications, such as sinusoidal dilatation, peliosis hepatitis, and Budd-Chiari syndrome, may also be seen.^{1,2}

Hepatic peliosis is a vascular condition in which the proliferation of sinusoids in the liver results in the engorgement of the capillary bed and cavities within the liver parenchyma. Rupture of these abnormal vessels can lead to fatal internal hemorrhage.³⁻⁵ This study describes the imaging findings and management of two patients with intrahepatic bleeding associated with anabolic steroids.

Case Reports

Case 1

A 31-year-old man presented with sudden-onset sharp right upper quadrant abdominal pain. Labs were notable for leukocytosis, alanine transaminase 620 U/L, aspartate transaminase 400

U/L, and normal bilirubin, alkaline phosphatase, and coagulation parameters. Prior history was significant for nonprescription oral androstenedione and intramuscular nandrolone use and associated bleeding hepatic adenoma, for which he underwent left lateral hepatectomy 4 years prior to presentation. Pathology revealed hepatic adenoma and peliosis hepatitis of 25 cm. He admitted to a recurrence in the use of parenteral nandrolone 6 weeks prior to the current presentation.

Computed tomography (CT) scan revealed multiple lesions in the right lobe of the liver (▶ **Fig. 1A**) accompanied by a subcapsular hematoma and intraperitoneal hemorrhage. The largest of these lesions measured 7.7 cm × 7.2 cm and demonstrated intralesional hemorrhage. He was managed conservatively and developed acutely worsening pain, tachycardia, and blood loss 3 days later. CT scan done on day 3, showed an interval increase in the hepatic hemorrhage with new subphrenic and anterior perihepatic/subcapsular components (▶ **Fig. 1B**).

Given his limited liver function and ongoing steroid abuse, a decision was made to proceed with angiography with embolization. The aberrant right hepatic artery supplying the posterior segments arising directly from the celiac trunk

DOI <https://doi.org/10.1055/s-0044-1787963>.
ISSN 2581-9933.

© 2024. The Author(s).

This is an open access article published by Thieme under the terms of the Creative Commons Attribution License, permitting unrestricted use, distribution, and reproduction so long as the original work is properly cited. (<https://creativecommons.org/licenses/by/4.0/>)
Thieme Medical and Scientific Publishers Pvt. Ltd., A-12, 2nd Floor, Sector 2, Noida-201301 UP, India

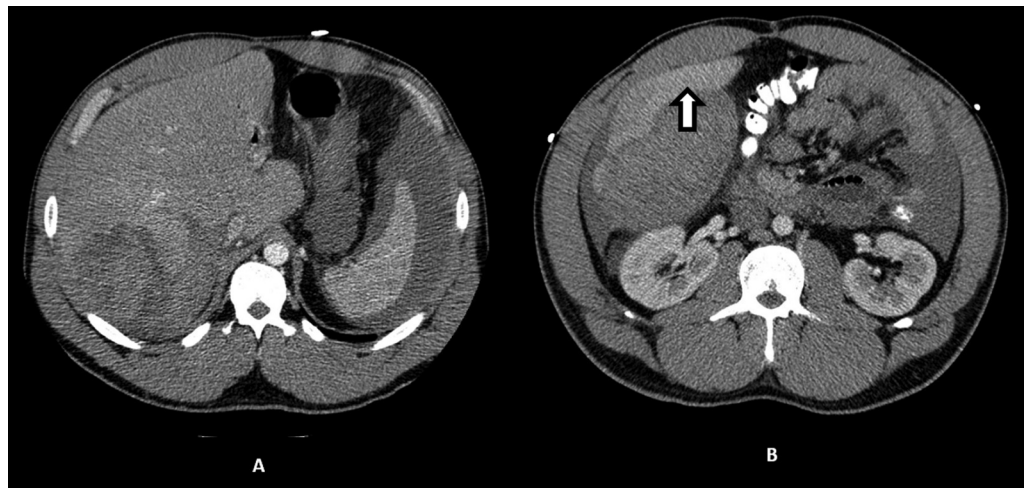

Fig. 1 Contrast-enhanced computed tomography (CT) scans done on day 1 (A) and day 3 (B) of current presentation showed an interval increase in the hepatic hemorrhage with new subphrenic and anterior perihepatic/subcapsular components (indicated by the white block arrow).

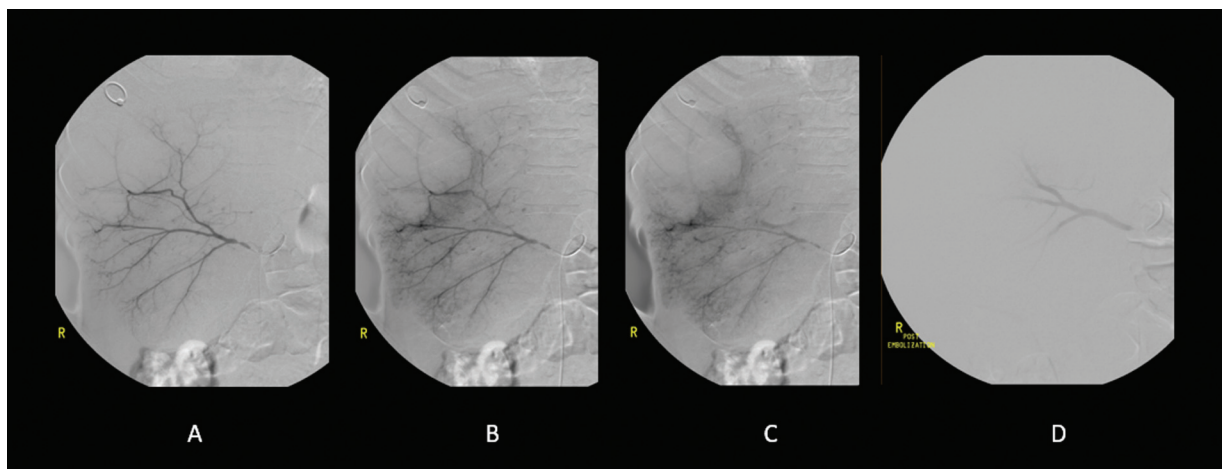

Fig. 2 Angiography via an aberrant right hepatic artery (A). Pooling of contrast (B, C) which may represent hepatic peliosis. The aberrant right hepatic artery was embolized with 700–900 μ m polyvinyl alcohol (PVA) particles, after which distal contrast pooling resolved (D).

was selectively catheterized (**Fig. 2A**), and angiography showed pooling of contrast material with no active extravasation consistent with hepatic peliosis (**Fig. 2B, C**). The aberrant right hepatic artery was embolized with 700 to 900 μ m polyvinyl alcohol particles with resolution of the distal contrast pooling (**Fig. 2D**).

Case 2

A previously healthy 20-year-old male with a history of non-prescribed selective androgen receptor modulator (SARM) Ligandrol consumption and active use of 4000 mg N-acetylcysteine (NAC) presented with acute-onset severe right upper quadrant abdominal pain. CT scan revealed a large 25.7 cm subcapsular hepatic hematoma in the right lobe with active extravasation (**Fig. 3**). The etiology of the extensive spontaneous bleeding was unclear. The hemorrhage may be secondary to an underlying hepatic adenoma or hepatic peliosis, difficult to visualize on imaging due to the hematoma’s size, compounded by a coagulopathic state possibly created or worsened by NAC use.⁶ The underlying lesion may also be linked to prior SARM or undisclosed anabolic steroid use.

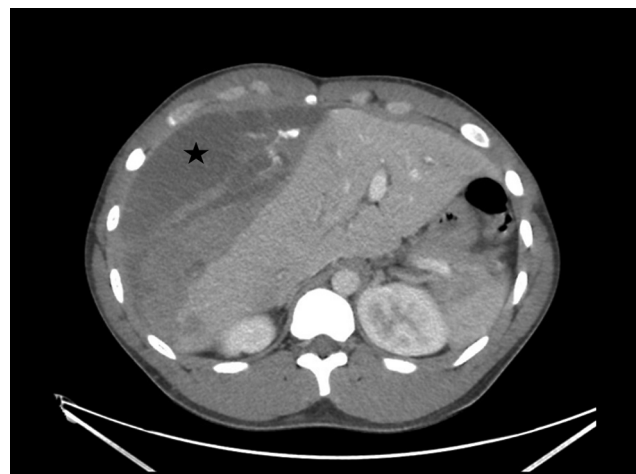

Fig. 3 An initial computed tomography (CT) scan of the abdomen showing a large right lobe subcapsular hepatic hematoma (indicated by the black star). An extensive mass effect was also noted, and hence an underlying mass lesion could not be excluded on the basis of this study.

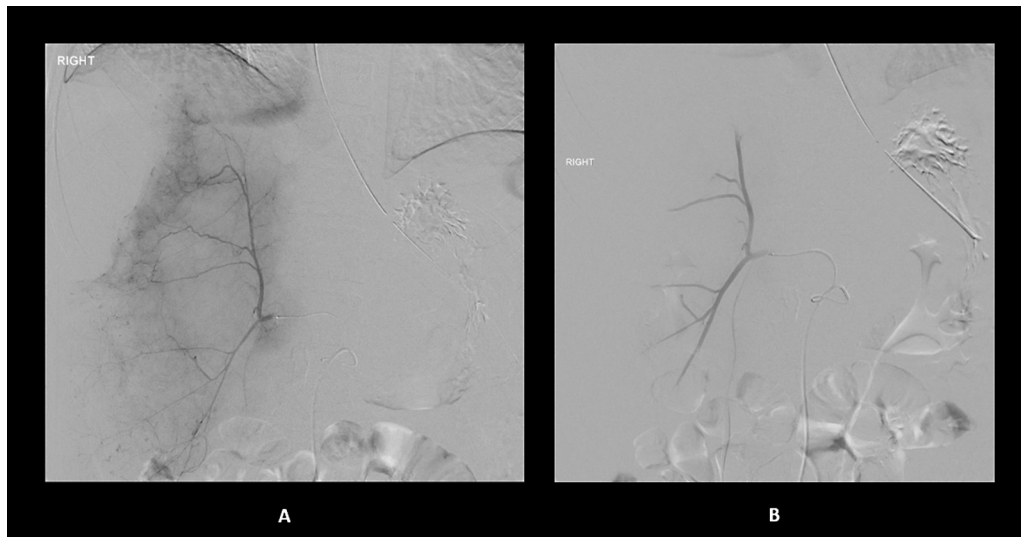


Fig. 4 Right hepatic artery digitally subtracted angiogram with multifocal areas of contrast pooling (A) along the right hepatic lobe adjacent to the hematoma, which suggests hepatic peliosis. No evidence of large foci of extravasation or arterially enhancing mass lesion. Multiple segmental branches were selectively catheterized and embolized with gelatin sponge. (B) Postembolization images showed pruning of the vasculature and no significant residual hemorrhage.

The patient was taken for endovascular management. A superior mesenteric angiography demonstrated an aberrant right hepatic artery and a marked mass effect on the hepatic parenchyma from the large subcapsular hematoma. The right hepatic artery angiography demonstrated multifocal areas of contrast pooling (►Fig. 4A) along the right hepatic lobe adjacent to the hematoma, which may be seen in the setting of hepatic peliosis.⁷ There was no evidence of large foci of extravasation or arterially enhancing mass lesion. Multiple segmental branches of the right hepatic artery were embolized with gelatin sponge with resolution of contrast pooling and near stasis of flow (►Fig. 4B).

Discussion and Conclusion

On angiography, hepatic peliosis appears as accumulations of contrast material during the late arterial phase. The enhancement is typically more distinct during the parenchymal phase and persists during the porto-venous phase.⁷ In the cases described above, digital subtraction angiography showed focal puddling of contrast material that slowly increased over time. This finding is indicative of a higher likelihood of hepatic peliosis. In contrast, hepatic adenomas are hypervascular and do not show puddling of contrast. Arterial embolization can effectively address bleeding associated with hepatic adenomas or peliosis.

In conclusion, the cases described here underscore the severe, potentially fatal complications of anabolic steroid abuse. Health care providers should have a high level of suspicion for hepatic complications when there is a history of anabolic steroid abuse. In the backdrop of addictive behavior

patterns, rigorous monitoring for neoplastic manifestations is indispensable.

Funding

This research received no specific grant from funding agencies in the public, commercial, or not-for-profit sectors.

Conflict of Interest

None declared.

References

- 1 Petrovic A, Vukadin S, Sikora R, et al. Anabolic androgenic steroid-induced liver injury: An update. *World J Gastroenterol* 2022;28(26):3071–3080
- 2 Casavant MJ, Blake K, Griffith J, Yates A, Copley LM. Consequences of use of anabolic androgenic steroids. *Pediatr Clin North Am* 2007;54(04):677–690, x
- 3 Fidelman N, LaBerge JM, Kerlan RK Jr. SCVIR 2002 Film Panel case 4: massive intraperitoneal hemorrhage caused by peliosis hepatis. *J Vasc Interv Radiol* 2002;13(05):542–545
- 4 Choi SK, Jin JS, Cho SG, et al. Spontaneous liver rupture in a patient with peliosis hepatis: a case report. *World J Gastroenterol* 2009;15(43):5493–5497
- 5 Hayward SR, Lucas CE, Ledgerwood AM. Recurrent spontaneous intrahepatic hemorrhage from peliosis hepatis. *Arch Surg* 1991;126(06):782–783
- 6 Niemi TT, Munsterhjelm E, Pöyhiä R, Hynninen MS, Salmenperä MT. The effect of N-acetylcysteine on blood coagulation and platelet function in patients undergoing open repair of abdominal aortic aneurysm. *Blood Coagul Fibrinolysis* 2006;17(01):29–34
- 7 Iannaccone R, Federle MP, Brancatelli G, et al. Peliosis hepatis: spectrum of imaging findings. *AJR Am J Roentgenol* 2006;187(01):W43–52