




Comparison of the Results of Phalloplasty Using Radial Free Forearm Flap and Anterolateral Thigh in Iran from 2014 to 2019

Mohammad-Reza Akhoondinasab¹ Amir Saraee¹  Siamak-Farokh Forghani¹ Ali Mousavi¹
Mohammad Amin Shahrbafe²

¹ Department of Plastic and Reconstructive Surgery, School of Medicine, Iran University of Medical Sciences, Tehran, Iran

² Faculty of Medicine, Shahid Beheshti University of Medical Sciences, Tehran, Iran

Address for correspondence Amir Saraee, MD, Department of Plastic and Reconstructive surgery, Iran University of Medical Sciences, Fatima Plastic and Reconstructive Surgery Hospital, Asad Abadi Avenue, 21, Tehran, 1433933111, Iran (e-mail: Dr.a.saraee@gmail.com).

Indian J Plast Surg 2024;57:387–393.

Abstract

Introduction Due to the worldwide growing number of transgender individuals openly identifying themselves, including in Iran, these individuals need more attention and support. This study compares patient satisfaction and quality of life after female-to-male gender confirmation surgery using an anterolateral thigh (ALT) flap and radial forearm free flap (RFFF).

Materials and Methods This study included 49 patients who underwent phalloplasty from 2014 to 2019 using two different methods. The two groups' outcomes and quality of life were investigated and compared 1 year after the operation.

Results The mean age of the patients in this study was 32.7 years. Among patients, 44.9% underwent revision operations, and 38.8% had residual protective sensations after 1 year. In terms of quality of life after surgery, the general shape of the phallus, cold and heat sensation, sense of touch, the body of glans and shaft, color and size of the phallus, sexual pleasure in patients and their partners, and the relationship between the number of anastomosed nerves and sexual satisfaction, there was no statistically significant difference between the two groups. The ALT group had statistically significantly higher rates of orgasms compared to the RFFF group.

Conclusion The outcomes of the two phalloplasty surgery methods (ALT and RFFF) are similar in different aspects, such as the quality of life.

Keywords

- ▶ phalloplasty
- ▶ gender-affirmation surgery
- ▶ anterolateral thigh flap

Introduction

The prevalence of gender dysphoria varies across different countries in the world, and it is estimated that 25 million people worldwide are affected by the condition. Although society's current situation is changing positively, early

The principles outlined in the Declaration of Helsinki have been followed.

Appropriate institutional review board approval has been obtained.

article published online
May 24, 2024

DOI <https://doi.org/10.1055/s-0044-1787060>.
ISSN 0970-0358.

© 2024. Association of Plastic Surgeons of India. All rights reserved. This is an open access article published by Thieme under the terms of the Creative Commons Attribution-NonDerivative-NonCommercial-License, permitting copying and reproduction so long as the original work is given appropriate credit. Contents may not be used for commercial purposes, or adapted, remixed, transformed or built upon. (<https://creativecommons.org/licenses/by-nc-nd/4.0/>)

Thieme Medical and Scientific Publishers Pvt. Ltd., A-12, 2nd Floor, Sector 2, Noida-201301 UP, India

judgments were unfavorable toward these patients. In Iran, there are few accurate statistics on this disorder's prevalence and incidence. As the new legislation permits gender-affirming surgery in Iran, the number of related surgeries has increased. Phalloplasty, a well-recognized surgical procedure commonly used to treat transgender male patients, is performed in our hospital using different methods. This study compared the satisfaction from phalloplasty by radial forearm free flap (RFFF) with a pedicled anterolateral thigh flap (pALT).

Materials and Methods

First, records of patients who underwent phalloplasty surgery in Hazrat Fatemeh Hospital from 2014 to 2019 were reviewed. Cases of phalloplasty other than pALT and RFFF (latissimus dorsi flap and fibula free flap) were excluded from the research. It was necessary that at least 1 year should have passed from the surgery to assess the sensation in the neophallus. We obtained written consent and then compiled the results into a table.

One surgeon performed all surgeries. Selecting the appropriate flap depended on several factors, including the need for urinary diversion, subcutaneous fat thickness, and the patient's preference. Standing urination is not common in Iran, and due to the high incidence of urinary complications, most patients were denied committing to urethroplasty. Still, if a patient insisted on doing it, RFFF was considered, and a tube-in-tube flap was performed. In the second stage, a urologist placed a suprapubic catheter for patients who requested urethroplasty. The genital skin surrounding the 14F catheter was elliptically incised, and the urologist created a vaginal mucosal flap around the catheter in the proximal portion.

Neourethral consists of the urethral plate, clitoral shaft skin, and vulvar skin. The labia minora skin covered the raw surface, and the labia majors created the scrotum. For other patients, selecting a flap was based on the desired phallus size, that is, for larger size ALT and average size RFFF was chosen. In obese patients, RFFF was suitable, and in thin individuals, an ALT flap was considered a superior option.

In all patients, at least one nerve anastomosis was performed (usually to the ilioinguinal nerve) to create the protective sensation. Two sensory nerves were selected in both the RFFF and ALT groups. In the RFFF group, the medial and lateral antebrachial nerves, and in the ALT group, two branches of the lateral cutaneous nerve of the thigh, were selected. The giant branch of the flap was anastomosed to the ilioinguinal nerve, and the lesser branch was anastomosed to the dorsal clitoris nerve.

Occasionally, the second nerve (clitoral and cutaneous sensory nerve) was anastomosed. The inability to the anastomosis of the clitoral nerve was due to two main reasons: clitoral adhesion secondary to previous metoidioplasty operation or the lack of a suitable nerve in the flap. The deepithelialized clitoris was released, turned upward, and fixed by polydioxanone 3-0 suture to the symphysis pubis. In the ALT group, the pedicled flap was based on the descending branch of the lateral circumflex artery. In the RFFF group, the

free flap was anastomosed to the left femoral artery and saphenous vein. A pALT flap or RFFF was set to the fascia of the symphysis pubis in the midline over the clitoris. Coronoplasty and scrotoplasty were performed in the second stage between 2 and 6 months after the primary surgery. Also, the vaginal introitus (colpocleisis) was partially closed at the same surgery. Nobody underwent a vaginectomy because of the chance of injury to the urethra or rectum and the risk of remanent vagina mucosa that could have converted to mucosal cyst.

One year after phalloplasty, penile and scrotal implants were inserted. Because of the high cost of penile implants, two patients in the ALT group and one in the RFFF group accomplished the last stage. All the implants were malleable (Promedon), and one or two cylinders were placed according to tissue capacity. At least 1 year after the operation, patients finally included in the study were referred to the occupational therapy ward for skin protective sensation assessment and the monofilament test.

Based on the monofilament test, results were classified into five groups:

- Normal sensation
- Residual texture (difficulty discriminating shape and temperature)
- Residual protective sensation (loss of hot and cold discrimination)
- Loss of protective sensation but still able to feel deep pressure and pain
- Residual deep pressure but still able to feel pain

Patients were questioned about their satisfaction with the shape of the phallus, glans, shaft, thermal sensation (hot and cold), penile size, and orgasmic experience (yes or no question). Ultimately, we compared the results of the two groups.

Other factors studied included the quality of life with the 36-Item Short Form Health Survey (SF-36) questionnaire, which examines the current patient's quality of life compared to the previous year. This questionnaire was adapted to the context of our country, Iran.

These nine groups include the following:

- Physical functioning
- Role limitations due to physical health
- Role limitations due to emotional problems
- Energy and fatigue
- Emotional well-being
- Social functioning
- Pain
- General health
- Health change

Sampling Method

This study included 72 patients who underwent phalloplasty surgery in Hazrat Fatemeh Hospital from 2014 to 2019. Among these patients, 23 cases were excluded from the study.

There were two flap failures. One was phalloplasty with ALT, which was replaced by a latissimus dorsi flap, and the other was partial necrosis of RFFF. These two flaps were

Table 1 Relation between the count of the nerve anastomosis and sexual arousal

Number of nerve anastomosed	Sexual arousal		Total
	No	Yes	
One nerve	6	1	7
Two nerves	5	37	42
Total	11	38	49

excluded from the study. Twenty-one other patients were excluded because less than a year had passed since the surgery or the patient did not wish to continue participating in the study. According to the number of surgeries performed in this center from 2014 to 2019, 25 cases in the phalloplasty group with RFFF and 24 patients in the ALT group were studied.

Statistical Analysis

Data were analyzed using SPSS statistical software version 23.

Results

Out of 49 patients in this study, 49% (24 patients) underwent ALT surgery, and 51% (25 patients) underwent RFFF surgery.

The mean age of patients enrolled in this study was 32.7 years, with a minimum of 23 and a maximum of 46 years.

We compared the relationship between the number of anastomosed nerves (one nerve for protection vs. two for protection and sexual arousal) and the degree of sexual pleasure. In 42 patients (85.7%), two nerves (mentioned above in the methods section), and in 7 patients (14.3%), one nerve has been anastomosed (►Table 1). Of these seven cases, three were in the ALT group and four were in the RFFF group. The relationship between the number of anastomosed nerves and the patient's level of sexual arousal was statistically significant (p -value < 0.05).

Due to the high cost of phallus prosthesis, it was implanted only in 6.1% of patients. Testicular prostheses were inserted in 34.7% of cases. Among the ALT and RFFF groups, the prosthesis was inserted in 8.33 and 4%, respectively.

Urethral reconstruction was performed in 10.2% of the cases during the surgery. The reconstruction technique was tube-in-tube in RFFF patients.

The minimum and maximum ages of patients in this study were 23 and 46, respectively. The mean age of the participants was 32.7 years.

Note that 44.9% of patients underwent a revision for partial phallus necrosis, urinary tract infection, glans reconstruction, irrigation, and debridement. There was no significant difference in revision in the two groups (ALT = 41.7% and RFFF = 48%). The monofilament test was performed at least 1 year after surgery to assess the sensation of the neophallus. In 38.8% of the patients the residual protective sensation of the phallus was detected. No patient reached the usual sense of the phallus and there was no significant difference in neophallus skin sensation between the ALT and RFFF groups (►Table 2).

The usual sense of neophallus was not obtained for at least 1 year after the operation. A total of 4.1% of patients had residual texture, 28.6% experienced a loss of protective sensation, and 28.6% endured residual deep pressure.

In comparison between ALT and RFFF groups regarding neophallus sensory examination, the highest number of patients in both groups belonged to the residual protective sensation. According to the chi-square test, the sensation of neophallus was not significantly different between the two groups (p -value > 0.05).

All patients completed the standardized SF-36 questionnaire, which evaluates the quality of life in the previous year in nine aspects. The patient's average quality of life in the ALT group was 87.22%, and in the RFFF group, it was 90.53%, which was not statistically significant (p -value > 0.05).

The results of the SF-36 questionnaire, which assesses patients' quality of life (in nine subgroups), demonstrated that the difference in the patient's quality of life between the two groups was not statistically significant.

The highest level of improvement in quality of life in both RFFF and ALT groups was related to the patient's physical functioning (►Table 3). In a 1-year postoperative evaluation, the neophallus thermal sensation (hot and cold) was examined in patients. As a result, there was no significant difference between the two groups regarding the genital sensibility to temperature and tactile sensation of the neophallus.

The mean width of the neophallus was 4 cm in the ALT group and 3 cm in the RFFF group. The mean length of it was 15 cm in the ALT group and 13 cm in the RFFF group. We asked the patient about their satisfaction with the shape,

Table 2 Monofilament test results according to each group

Monofilament test	Type		Total
	ALT	RFFF	
Residual deep pressure	8	6	14
Loss of protective sensation	6	8	14
Residual protective sensation	10	9	19
Residual texture	0	2	2
Total	24	25	49

Abbreviations: ALT, anterolateral thigh; RFFF, radial forearm free flap.

Table 3 Comparing the results of SF-36 questionnaires in two groups

Groups Statistics					
	Type	N	Mean	Standard deviation	Standard error of mean
Physical functioning	ALT	24	92.083	7.6495	1.5614
	RFFF	25	95.200	8.5975	1.7195
Role limitation due to physical health	ALT	24	88.125	13.6583	2.7880
	RFFF	25	87.800	14.5831	2.9166
Role limitation due to emotional problems	ALT	24	86.950	22.6008	4.6134
	RFFF	25	92.000	6.4550	1.2910
Energy/fatigue	ALT	24	85.208	17.4754	3.5672
	RFFF	25	92.800	9.6911	1.9382
Emotional well-being	ALT	24	84.250	15.9599	3.2578
	RFFF	25	90.240	7.6446	1.5289
Social functioning	ALT	24	86.771	17.1388	3.4984
	RFFF	25	86.500	13.1893	2.6379
Pain	ALT	24	88.646	18.3561	3.7469
	RFFF	25	86.900	13.2736	2.6547
General health	ALT	24	83.333	17.9774	3.6696
	RFFF	25	89.120	13.7759	2.7552
Health change	ALT	24	89.583	15.5980	3.1839
	RFFF	25	94.200	9.0921	1.8184

Abbreviations: ALT, anterolateral thigh; RFFF, radial forearm free flap; SF-36, 36-Item Short Form Health Survey.

size, color, and glans shape of the penis and orgasm capability (yes or no).

The satisfaction of various parameters among the ALT/RFFF group, the appearance of neophallus (87%/72%), penile shaft (87%/72%), glans appearance (54%/68%), skin color with texture (79%/84%), and neophallus size (75%/72%) were statistically insignificant.

Achieving orgasm was also investigated in this study. The orgasm was also reported in 17 patients in the ALT group and 8 patients in the RFFF group. The difference was statistically significant between the groups.

Patients were asked about the possibility of intercourse. A total of 11 patients in the ALT group (1 patient had an implant) and 8 patients in the RFFF group (1 patient had an implant) had successful intercourse, which was not statistically significant.

Discussion

Gender incongruence refers to a gender-related condition that results in an incompatibility between one's gender identity and sex organs, eventually leading to severe psychological problems.^{1,2}

The prevalence of gender dysphoria varies worldwide, and approximately 25 million people are struggling with this disorder worldwide. This disorder is more common in men than women.^{3,4}

The World Professional Association for Transgender Health (WPATH) has developed guidelines for treating these patients.

All patients in this study had passed WPATH criteria before the transmen operation. Hormone therapy is recommended for 12 months before operating any masculinizing surgeries.⁵

The surgery begins with the masculinization of the breast and shaping of the upper body (top surgery) and ends with the surgery of the lower body (bottom surgery). In this study, transmen surgery was done in three steps. The first step was phalloplasty, the second was the reconstruction of the glans and scrotum, and the final was prosthesis implantation.

An ideal neophallus construction is predictably reproduced at a one-stage procedure, is aesthetically acceptable, has endogenous sensibility, is sexually satisfying, stimulates enough sexual pleasure, creating a neourethra, and has minor complications and scarring for the patient as well as the donor area.^{2,6}

Metoidioplasty may be an acceptable technique for thin patients, but phalloplasty is better for patients with higher subcutaneous fat thickness.^{7,8}

Despite recent advances, no unique method has been developed to encompass all the above-mentioned features.

ALT Flap

Most surgeons prefer to use ALT flap as a pedicle due to its proximity to the groin to reduce the operation's length and hospital admission. Glans reconstruction should be delayed (usually 3 months later) to reduce the risk of distal necrosis. After harvesting the flap, the external or internal branches of the femoral cutaneous nerve can be anastomosed to the posterior branch of the clitoris to provide its sensation

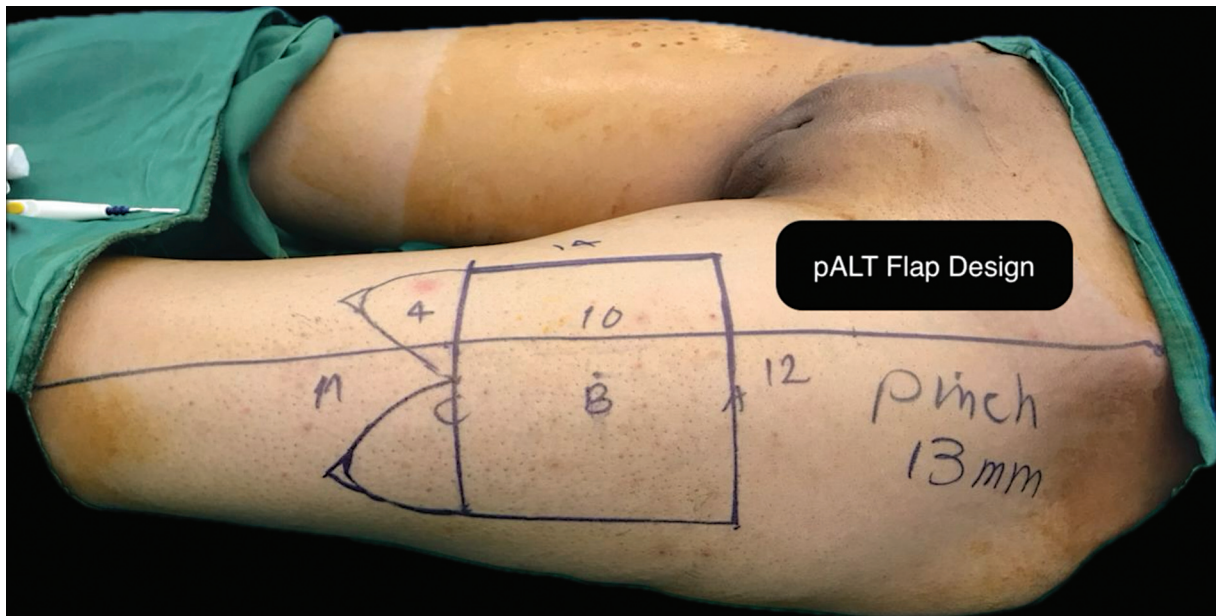


Fig. 1 Design of phalloplasty with anterolateral thigh (ALT) flap.

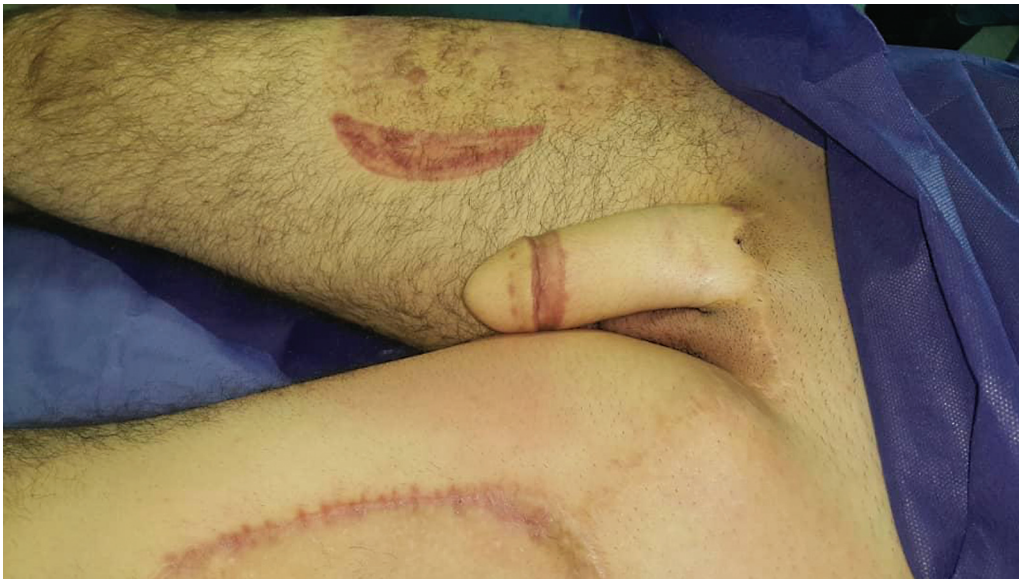

Fig. 2 Phalloplasty in a 32-year-old man with anterolateral thigh (ALT) flap.

(► **Figs. 1 and 2**). The risk of urinary fistula and dehiscence of the wound are higher in this type of flap.^{4,9} In the ALT group, there is a depressed scarring site in the donor site that is covered with the split-thickness skin graft from the other thigh. The patient in the ALT group could have intercourse without a prosthesis due to the bigger size of the ALT flap and its inherent firmness. Patients expressed that they could have intercourse using a thick, sufficiently lubricated condom.

RFFF Flap

RFFF is currently the most common surgical technique in phalloplasty. Due to its suitable anatomical properties, RFFF is presently used as a single-stage tube-in-tube flap with

glans reconstruction (► **Figs. 3 and 4**). The medial and lateral antibrachial nerves sensitize the flap by anastomosis to the dorsal clitoral and ilioinguinal nerves. According to some studies, it takes a year for a flap to gain sensation in the skin in the pubic region.^{9,10} Some disadvantages include flap atresia and a color mismatch between the phallus and surrounding tissues.³ Limitations of this technique also include the need for a prosthesis for erection and effective intercourse.^{5,11} In this group, there was a depressed scarring site in the donor's forearm (TS sign).⁶

In a study conducted from 2014 to 2019, researchers retrospectively compared pALT and RFFF phalloplasty and examined the patients during a 4-month follow-up period. Based on their results, the overall complications of RFFF

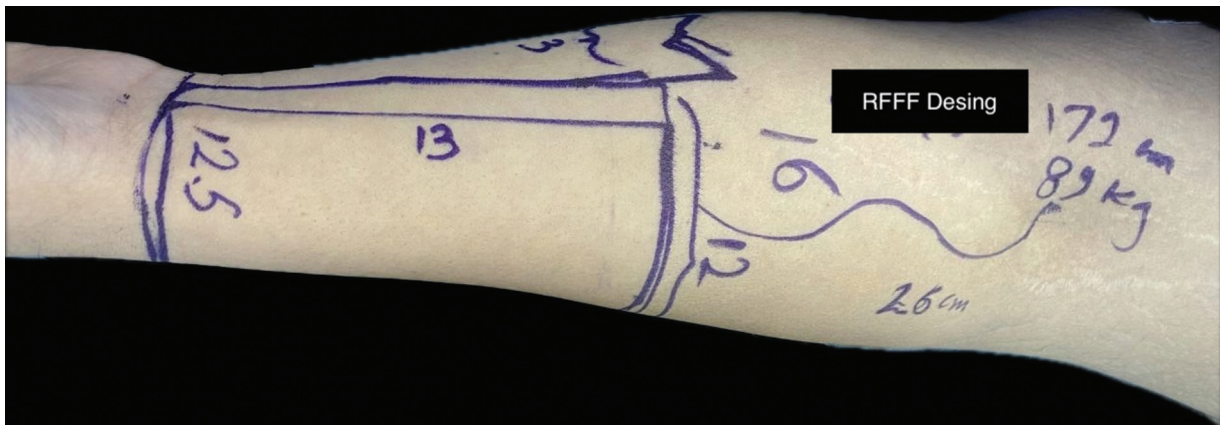


Fig. 3 Design of phalloplasty with radial forearm free flap (RFFF) method.

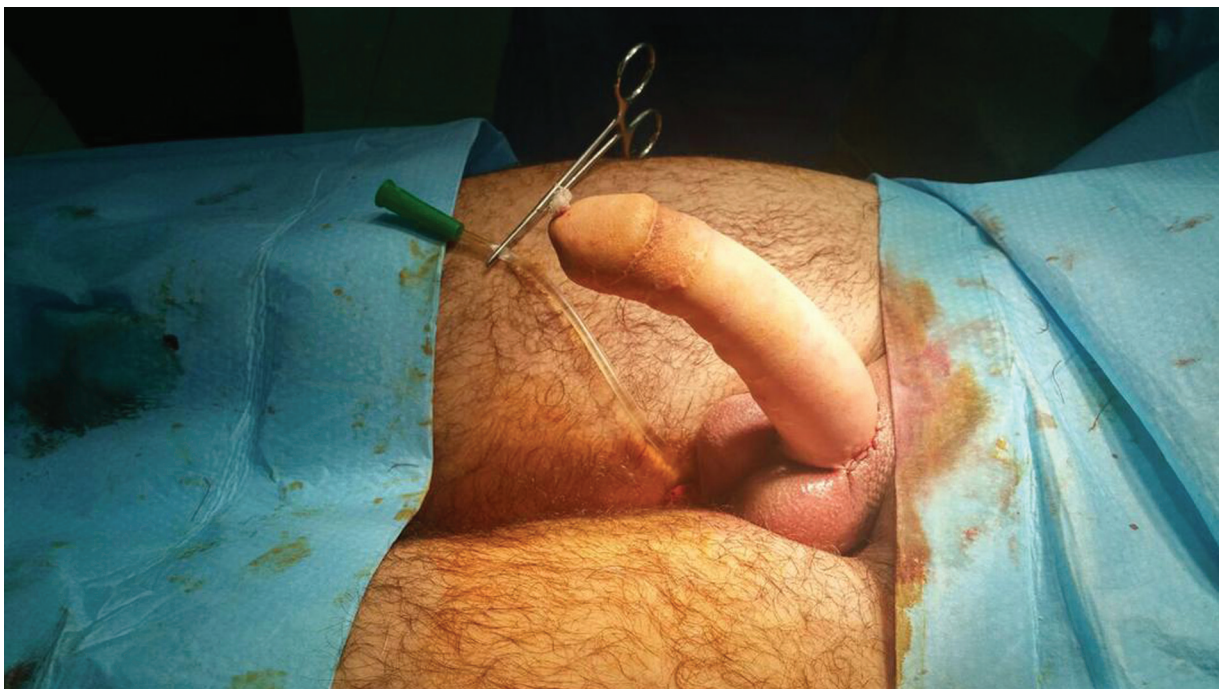


Fig. 4 Phalloplasty with radial forearm free flap (RFFF). A penile semirigid implant was inserted.

were generally lower than those of pALT. Therefore, they reported more neourethra difficulties in pALT phalloplasty.³

In our country, Iran, although these patients have an association, there are no accurate incidence, prevalence, or geographical distribution statistics. Due to the enactment of new laws related to gender affirmation in our country, the number of surgeries has dramatically increased.

In the present study, two of the most common phalloplasty techniques, RFFF and ALT, were studied and compared.

To obtain more widely applicable results, it is necessary to conduct studies with larger sample sizes. Due to the time-consuming legal process of obtaining permission to perform surgery in our country, it is recommended that the small sample size be compensated by conducting multicentric studies in several plastic surgery centers. It is also recommended that in future studies, patients should be

monitored for a longer duration. Moreover, this study can be conducted using other phalloplasty methods, such as a latissimus dorsi flap or a radial flap with bone.

Conclusion

The two methods of phalloplasty (ALT and RFFF) are not widely different in different aspects, such as promoting the quality of life. It is recommended to consider anastomosis of two nerves of the neophallus to the dorsal clitoral nerve and the ilioinguinal nerve (to maintain the protective sensation) to improve the patient's erogenous sense and increase sexual satisfaction. There were no significant differences between the two methods regarding neophallus characteristics. Still, regarding the patient's ability to orgasm, the ALT method was superior. The inherent stiffness of the flap can reduce the need for a prosthesis.

Note

The principles outlined in the Declaration of Helsinki have been followed. Appropriate institutional review board approval has been obtained.

Conflict of Interest

None declared.

References

- 1 Pavanello Decaro S, Van Gils S, Van Hoorde B, Baetens K, Heylens G, Elaut E. It Might take time: a study on the evolution of quality of life in individuals with gender incongruence during gender-affirming care. *J Sex Med* 2021;18(12):2045–2055
- 2 Frey JD, Poudrier G, Chiodo MV, Hazen A. A systematic review of metoidioplasty and radial forearm flap phalloplasty in female-to-male transgender genital reconstruction: is the “ideal” neophallus an achievable goal? *Plast Reconstr Surg Glob Open* 2016;4(12):e1131
- 3 Ascha M, Massie JP, Morrison SD, Crane CN, Chen ML. Outcomes of single stage phalloplasty by pedicled anterolateral thigh flap versus radial forearm free flap in gender confirming surgery. *J Urol* 2018;199(01):206–214
- 4 Morrison SD, Chen ML, Crane CN. An overview of female-to-male gender-confirming surgery. *Nat Rev Urol* 2017;14(08):486–500
- 5 Sarikaya S, Ralph DJ, Ralph DJ. Mystery and realities of phalloplasty: a systematic review. *Turk J Urol* 2017;43(03):229–236
- 6 Remington AC, Morrison SD, Massie JP, et al. Outcomes after phalloplasty: do transgender patients and multiple urethral procedures carry a higher rate of complication? *Plast Reconstr Surg* 2018;141(02):220e–229e
- 7 Bordas N, Stojanovic B, Bizic M, Szanto A, Djordjevic ML. Metoidioplasty: surgical options and outcomes in 813 cases. *Front Endocrinol (Lausanne)* 2021;12:760284
- 8 Elfering L, van de Grift TC, Al-Tamimi M, et al. How sensitive is the neophallus? Postphalloplasty experienced and objective sensitivity in transmasculine persons. *Sex Med* 2021;9(05):100413
- 9 Stojanovic B, Bencic M, Bizic M, Djordjevic ML. Metoidioplasty in gender affirmation: a review. *Indian J Plast Surg* 2022;55(02):156–161
- 10 Hu C-H, Chang CJ, Wang SW, Chang KV. A systematic review and meta-analysis of urethral complications and outcomes in transgender men. *J Plast Reconstr Aesthet Surg* 2022;75(01):10–24
- 11 Purohit RS, Kent M, Djordjevic ML. Penile prosthesis in transgender men after phalloplasty. *Indian J Plast Surg* 2022;55(02):168–173