



Background Factors Associated with Postoperative Complications in Patients with Advanced Hypopharyngeal Cancers Undergoing Total Pharyngolaryngoesophagectomy Followed by Free Jejunal Flap Reconstruction

Shintaro Fujimura¹ Hideaki Suzuki¹ Jun-ichi Ohkubo¹ Ryusuke Hori, MD, PhD¹

¹Department of Otorhinolaryngology – Head and Neck Surgery, University of Occupational and Environmental Health, Japan

Int J Pract Otolaryngol 2024;7:e16–e20.

Address for correspondence Shintaro Fujimura, Department of Otorhinolaryngology - Head and Neck Surgery, University of Occupational and Environmental Health, Japan, 1-1, Iseigaoka, Yahatanishi-ku Kitakyushu-shi, Fukuoka 807-8555, Japan (e-mail: s-fujimura@med.uoeh-u.ac.jp).

Ryusuke Hori, MD., Ph. D., Department of Otorhinolaryngology - Head and Neck Surgery, University of Occupational and Environmental Health, Japan, 1-1, Iseigaoka, Yahatanishi-ku Kitakyushu-shi, Fukuoka 807-8555, Japan

Abstract

Keywords

- ▶ hypopharyngeal cancer
- ▶ total pharyngolaryngectomy
- ▶ postoperative complication
- ▶ stricture of the esophagojejunal anastomosis
- ▶ background factor

We retrospectively analyzed background factors associated with postoperative complications in patients with advanced hypopharyngeal cancers who underwent total pharyngolaryngectomy followed by free jejunal flap reconstruction. A total of 23 participants, including 21 men and 2 women aged 49 to 83 years (average 72.3 years) were enrolled in this study. Mild and moderate/severe complications occurred in five and seven cases, respectively. The most common complication was stricture of the esophagojejunal anastomosis (nine cases). Other complications included two tracheostomal stenosis, one each for pneumonia and chyle leakage. The free jejunal flap survived in all cases. The disease-free survival rate was 47.8% at 52 weeks after surgery. The platelet count was significantly lower ($18.8 \pm 1.9 \times 10^4/\text{mL}$ vs. $27.7 \pm 1.8 \times 10^4/\text{mL}$; $p = 0.008$) in patients with moderate/severe complications than in those without. The percentage of stage IV cases and intraoperative blood loss tended to be higher in patients with complications than in those without. Knowledge of these potential risk factors for the development of postoperative complications to satisfactorily manage the clinical course of patients with advanced hypopharyngeal cancers is necessary.

Introduction

The morbidity and mortality rates for hypopharyngeal cancer have recently been on the rise in Japan. Early-stage hypopharyngeal

cancer is not associated with any major subjective symptoms; however, it is prone to lymph node metastasis. Approximately 60% of the patients initially diagnosed with hypopharyngeal cancer are already at an advanced stage.¹

received
September 22, 2023
accepted after revision
January 18, 2024

DOI <https://doi.org/10.1055/s-0044-1786800>.
ISSN 2569-1783.

© 2024. The Author(s).

This is an open access article published by Thieme under the terms of the Creative Commons Attribution-NonDerivative-NonCommercial-License, permitting copying and reproduction so long as the original work is given appropriate credit. Contents may not be used for commercial purposes, or adapted, remixed, transformed or built upon. (<https://creativecommons.org/licenses/by-nc-nd/4.0/>)

Georg Thieme Verlag KG, Rüdigerstraße 14, 70469 Stuttgart, Germany

Patients with advanced hypopharyngeal cancer require extended surgery and reconstructive procedures. They often experience a significant decline in quality of life (QOL) because of the adverse effects of surgery on various functions, including speech and swallowing. In addition, many patients have underlying conditions, such as alcohol dependence, hepatic dysfunction, renal dysfunction, diabetes mellitus, hypertension, and arteriosclerosis, and these risk factors increase the incidence of postoperative complications.² Total pharyngolaryngoesophagectomy (TPLE) followed by free jejunal flap reconstruction is currently the standard surgical treatment for advanced hypopharyngeal cancer. In this study, we analyzed a set of advanced hypopharyngeal cancer cases that involved TPLE, followed by free jejunal flap reconstruction in our department, with a focus on postoperative complications and a literature review.

Participants and Methods

This study included 23 patients with advanced hypopharyngeal cancer who underwent TPLE followed by free jejunal flap reconstruction in our department from April 2020 to January 2022. The Department of Head and Neck Surgery was responsible for resectioning the primary lesion and dissecting the neck. The Department of Gastrointestinal Surgery collected the jejunum, and the Department of Plastic and Reconstructive Surgery was responsible for the reconstruction.

As potential background factors associated with postoperative complications, the following data were retrospectively examined based on available medical records: age, sex, preoperative performance status (PS), stage, nutritional status, past medical history (multiple primary cancers, hypertension, and diabetes mellitus), preoperative chemotherapy/radiotherapy information, preoperative blood tests (hemoglobin level, serum total protein level, albumin level, and platelet count), surgery duration, and intraoperative blood loss. Glasgow Prognostic Score (GPS) was used to evaluate nutritional status. The Japan Clinical Oncology Group postoperative complications criteria (Clavien–Dindo classification) were used to assess postoperative complications. Grade I and II complications were considered mild, whereas grade III to V complications were considered moderate to severe. Differences in the means and proportions were determined by univariate analysis using the Mann–Whitney U and Fisher's exact tests, respectively, followed by a multivariate analysis using logistic regression analysis. Differences with $p < 0.05$ and $p < 0.1$ were considered statistically significant and near-significant, respectively. EZR was used for statistical analysis.³

Results

Of the enrolled participants, 21 were men and 2 were women. The ages ranged from 49 to 83 years (mean 72.3 years). The length of postoperative hospital stay and postoperative follow-up ranged from 14 to 72 days (mean 26.0 d) and 4 to 138 weeks (mean 69.6 weeks), respectively. The histopathological type was squamous cell carcinoma for all cases. The lesions were identified at the following subsites:

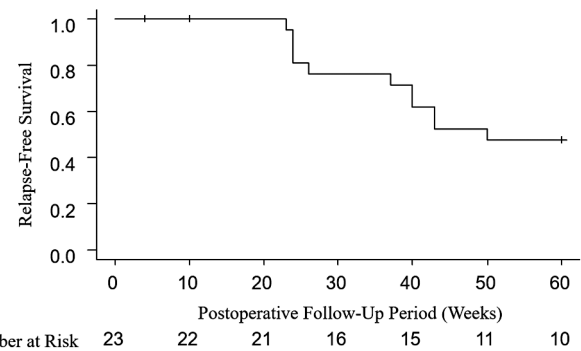


Fig. 1 Relapse-free survival curve. The relapse-free survival rate at postoperative week 52 was 47.8%.

pyriform sinus in 12 cases (52%), posterior wall in 8 cases (35%), and the postcricoid area in 3 cases (13%). Concerning stage classification, there were 3, 3, and 17 cases of stage II, III, and IV, respectively. Ten patients had multiple primary cancers, including three with esophageal cancer, three with gastric cancer, one with colorectal cancer, four with laryngeal cancer, and two with lung cancer. Seven patients had double primary cancer, whereas three had triple primary cancer. The surgery and intraoperative blood loss duration ranged from 412 to 587 minutes (mean 493.3 min) and 50 to 800 mL (mean 237.0 mL), respectively. Neck dissection was performed in all cases, including 17 cases (74%) in which bilateral neck dissection was performed.

► **Fig. 1** shows the Kaplan–Meier curve for relapse-free survival. The relapse-free survival rate at postoperative week 52 was 47.8%. Of the 23 patients, 3 died during the follow-up period, 2 died from distant metastasis, and 1 died from suffocation because of intratracheal bleeding during postoperative chemotherapy following mediastinal lymph node metastasis.

Postoperative complications occurred in 12 cases (52%), including mild and moderate-to-severe complications in five and seven cases, respectively. Mild complications included esophagojejunal anastomotic stricture in three cases, stenosis of the tracheostoma in one case, and pneumonia in one case. Moderate-to-severe complications included esophagojejunal anastomotic stricture in six cases (plus chylorrhea in one case) and stenosis of the tracheostoma in one case. Free jejunal flap necrosis was not observed in any patient. Of the cases in which esophagojejunal anastomotic stricture occurred, endoscopic dilation was performed in five cases, and two patients were incapable of oral ingestion because of esophageal anastomotic stricture. One of these patients also had stricture resulting from esophageal cancer, and reestablishment of oral ingestion failed even after radiotherapy. The other patient also could not reestablish oral ingestion through swallowing rehabilitation, whereas other interventions were unsuccessful because of marked cognitive impairment and treatment refusal.

The differences in background factors between patients with and without complications and the results of univariate analysis are summarized in ► **Table 1**. There tended to be more stage IV cases in the complication-positive group ($n = 12$) than in the group without ($n = 11$; 11/12 [92%] vs.

Table 1 All complications and background factors

	Complication-positive (n = 12)	Complication-negative (n = 11)	p-Value
Age (years)	74.5 ± 2.2	69.9 ± 3.0	0.241
Sex (male/female)	11/1	10/1	1.000
PS ≥1	6/12 (50%)	2/11 (18%)	0.193
Patients with positive lymph nodes	11/12 (92%)	7/11 (64%)	0.155
Stage IV	11/12 (92%)	6/11 (55%)	0.069 ^a
GPS ≥1	4/12 (33%)	4/11 (36%)	1.000
History of multiple primary cancers	5/12 (42%)	5/11 (45%)	1.000
History of Hypertension	4/12 (33%)	6/11 (55%)	0.414
History of diabetes mellitus	3/12 (25%)	2/11 (18%)	1.000
History of chemotherapy	2/12 (17%)	2/11 (18%)	1.000
History of radiotherapy	2/12 (17%)	3/11 (27%)	0.640
Albumin level (g/dL)	3.84 ± 0.4	3.68 ± 0.5	0.686
Hemoglobin level (g/dL)	13.4 ± 0.5	12.8 ± 0.5	0.310
Serum total protein (g/dL)	5.3 ± 0.4	5.4 ± 0.3	0.926
Platelet count (×10 ⁴ /μL)	22.6 ± 2.2	27.6 ± 2.2	0.065 ^a
Surgery duration (min)	506.5 ± 14.4	479.0 ± 17.0	0.176
Intraoperative blood loss (mL)	304.2 ± 63.0	163.6 ± 15.9	0.056 ^a

Abbreviations: GPS, Glasgow Prognostic Score; PS, preoperative performance status.

^a*p* < 0.1.

6/11 [55%]; *p* = 0.069). The platelet count also tended to be lower ($22.6 \pm 2.2 \times 10^4/\mu\text{L}$ vs. $27.6 \pm 2.2 \times 10^4/\mu\text{L}$; *p* = 0.065), and intraoperative blood loss tended to be higher (304.2 ± 63.0 vs. 163.6 ± 15.9 mL; *p* = 0.056) than that of the complication-negative group. **Table 2** summarizes the differences in background factors between patients with and without moderate-to-severe complications and the results of univariate analysis. In the moderate-to-severe complication-positive group (*n* = 7), hemoglobin levels were significantly higher (14.1 ± 0.3 vs. 12.7 ± 0.5 g/dL; *p* = 0.049) and the platelet count was significantly lower ($18.8 \pm 1.9 \times 10^4/\mu\text{L}$ vs. $27.7 \pm 1.8 \times 10^4/\mu\text{L}$; *p* = 0.008) than those in the moderate-to-severe complication-negative group (*n* = 16). Moreover, intraoperative blood loss tended to be higher (302.1 ± 66.8 vs. 208.4 ± 42.5 mL; *p* = 0.095). Multivariate analysis revealed a significant difference in platelet count (*p* = 0.045). There were no differences between the complication-positive and -negative groups or between the moderate-to-severe complication-positive and -negative groups concerning age, sex, PS, proportion of patients with cervical lymph node metastasis, GPS, proportion of patients with multiple primary cancers, proportion of patients with hypertension, proportion of patients with diabetes mellitus, history of chemotherapy, history of radiotherapy, total serum protein levels, and duration of surgery.

Discussion

Head and neck cancer cases account for approximately 5% of all cancer cases. A national survey of 205 medical institutions

conducted by the Japan Society for Head and Neck Cancer in 2019 revealed that out of 13,658 patients with head and neck cancer, 2,858 (20.9%) were patients with hypopharyngeal cancers, which was second only to oral cancer (29.2%) in number. Patients with hypopharyngeal cancers have a peak age of onset in their sixties to seventies, and 91% are men.⁵ Consistent with this report, the vast majority of the patients included in the present study were men (21/23, 91%) and the mean age was 72.3 years.

For safety and restoring oral ingestion early, the free jejunal flap is the first-choice material for reconstructive surgery after TPLE for advanced hypopharyngeal cancer.⁴⁻⁶ At our hospital, the free jejunal flap was selected as a material for reconstruction following TPLE in all cases. With respect to intraoperative factors (surgery duration and blood loss) and the length of postoperative hospital stay, our results were equivalent or superior to those in other institutions.^{4,7}

Typical complications after TPLE and free jejunal flap reconstruction included esophagojejunal anastomotic stricture, necrosis of the grafted flap resulting from clot formation in the anastomosed blood vessels, anastomotic suture failure, bowel obstruction, and stenosis of the tracheostoma.⁸ In the present study, esophagojejunal anastomotic stricture was the most frequent complication. The univariate and multivariate analyses of the background factors revealed risk factors for these postoperative complications. In patients with moderate-to-severe complications, the univariate analysis showed a significantly lower platelet count and a near significantly higher hemoglobin level, whereas the multivariate analysis showed a significantly lower platelet count.

Table 2 Moderate-to-severe complications and background factors

	Moderate-to-severe complication-positive (n = 7)	Moderate-to-severe complication-negative (n = 16)	p-Value
Age	75.9 ± 3.1	70.8 ± 2.2	0.132
Sex (male/female)	7/0	14/2	1.000
PS ≥1	2/7 (29%)	6/16 (38%)	1.000
Patients with positive lymph nodes	7/7 (100%)	11/16 (69%)	0.272
Stage IV	6/7 (86%)	11/16 (69%)	0.621
GPS ≥1	2/7 (29%)	6/16 (38%)	1.000
History of multiple primary cancers	3/7 (43%)	7/16 (44%)	1.000
History of Hypertension	2/7 (29%)	8/16 (50%)	0.405
History of diabetes mellitus	1/7 (14%)	4/16 (25%)	1.000
History of chemotherapy	1/7 (14%)	3/16 (19%)	1.000
History of radiotherapy	1/7 (14%)	4/16 (25%)	1.000
Albumin level (g/dL)	3.8 ± 0.4	3.7 ± 0.5	0.710
Hemoglobin level (g/dL)	14.1 ± 0.3	12.7 ± 0.5	0.049 ^a
Serum total protein (g/dL)	5.1 ± 0.5	5.5 ± 0.3	0.504
Platelet count (×10 ⁴ /μL)	18.8 ± 1.9	27.7 ± 1.8	0.008 ^a
Surgery duration (min)	499.6 ± 23.3	490.6 ± 13.0	0.738
Intraoperative blood loss (mL)	302.1 ± 66.8	208.4 ± 42.5	0.095 ^b

Abbreviations: GPS, Glasgow Prognostic Score; PS, preoperative performance status.

^ap < 0.05.

^bp < 0.1.

Risk factors previously associated with complications after surgery for advanced head and neck cancer, as well as free flap reconstruction, included duration of surgery, excessive fluid infusion, surgeon skill level, history of chemoradiotherapy, and nutritional status.^{7–10} In the present study, low platelet count was a significant background factor for moderate-to-severe complications (► **Table 2**). An animal study in esophagectomized rats showed that ischemia at the anastomotic site is involved in anastomotic stricture,¹¹ which indicates the possibility that low platelet counts contributed to anastomotic stricture through increased intraoperative blood loss and caused local ischemia. The intraoperative blood loss tended to be larger among complication-positive patients (► **Tables 1 and 2**).

Identifying high hemoglobin levels as a background complication factor is paradoxical, and the reason remains unclear. Diluting blood without changing blood volume improved microcirculation in an animal study, as blood viscosity decreases upon dilution.¹² Hemodilution has also been applied in the surgery of head and neck tumors.¹³ For the cases in the present study, this mechanism may act to decrease complications. Identification of stage IV disease as a near-significant background factor for complications is understandable from the standpoint that the invasiveness of surgery is higher than that for stage III and less advanced diseases. No previous reports have documented the associations between post-TPLE complications and stage; however, an association between the total number of lymph nodes removed intraoperatively and postoperative anastomotic

stricture was reported in patients who underwent esophagectomy for esophageal cancer.¹⁴

The most frequent complication in our cohort was esophagojejunal anastomotic stricture, which occurred in nine cases (39%), including all severity grades. This incidence rate is similar to that reported previously.¹⁵ Anastomotic stricture is a complication that has major effects on postoperative treatment. In our department, endoscopic examinations are proactively performed when symptoms indicative of anastomotic stricture, such as reflux of food and drink, are evident for early detection and treatment. Endoscopic dilation is the treatment of choice for anastomotic stricture; however, dilation may be difficult to achieve in patients with low preoperative PS, decreased cognitive function, or no motivation to receive treatment. Thus, it is important to check for these background factors in advance to ensure that patients can complete the treatment. QOL will inevitably be disrupted if dysphagia cannot be improved because the patient must depend on gastrostomy or total parenteral nutrition.

Mori et al stated that postoperative radiotherapy is associated with anastomotic stricture and that frequent use of bougies during and after irradiation is important to prevent stricture.¹⁶ Moreover, mechanical anastomosis is more prone to postoperative stricture than manual anastomosis¹⁷; however, we used manual anastomosis in all cases, and the incidence of anastomotic stricture was comparable with previously reported rates. Thus, the anastomotic technique is unlikely to be a significant risk factor.

Necrosis of the free jejunal graft is the most serious complication of TPLE/free jejunal reconstruction. The incidence rates of free jejunal flap necrosis were approximately 1 to 5%,^{8,14,17} and free jejunal flap reconstruction is a reconstructive procedure that results in the highest graft survival rates in the head and neck region. In the present study, we showed that jejunal flaps survived in all of the 23 cases, which resulted in a satisfactory surgical outcome. Our department manages patients who have undergone this procedure in the intensive care unit. Blood flow is checked in the anastomotic vessels with an ultrasonic Doppler flowmeter, and the graft color is monitored every hour for early detection of jejunal flap necrosis. As a graft monitoring method, recent studies have measured local oxygen saturation using near-infrared devices, such as pulse oximeters.^{18,19} This technique may develop into a useful method for the early detection of flap necrosis.

Conclusion

We analyzed background factors for postoperative complications in 23 patients who underwent TPLE and free jejunal flap reconstruction for advanced hypopharyngeal cancer. Postoperative complications occurred in 12 cases (52%), and esophagojejunal anastomotic stricture, the most frequent complication, was observed in 9 cases (39%). Free jejunal flap necrosis did not occur in any of the cases. A low platelet count was identified as a significant background factor for moderate-to-severe complications. Moreover, the percentage of stage IV cases and the amount of intraoperative blood loss tended to be higher in patients who experienced complications. Our results suggest that monitoring these background factors in advance for early detection of complications is important for completing treatment in patients with advanced hypopharyngeal cancer.

Conflict of Interest

None declared.

References

- Eckel HE, Bradley PJ. Natural history of treated and untreated hypopharyngeal cancer. *Adv Otorhinolaryngol* 2019;83:27–34
- Bradley PJ. Symptoms and signs, staging and co-morbidity of hypopharyngeal cancer. *Adv Otorhinolaryngol* 2019;83:15–26
- Kanda Y. Investigation of the freely available easy-to-use software 'EZR' for medical statistics. *Bone Marrow Transplant* 2013;48(03):452–458
- Sugiyama N, Kimata Y, Sekido M, et al. A multi-institutional study of reconstruction for laryngopharyngo-esophagectomy. *Jpn J Head Neck Cancer* 2006;32:486–493
- Denewer A, Khater A, Hafez MT, et al. Pharyngo-esophageal reconstruction after resection of hypopharyngeal carcinoma: a new algorithm after analysis of 142 cases. *World J Surg Oncol* 2014;12:182
- Carlson GW, Schusterman MA, Guillaumondegui OM. Total reconstruction of the hypopharynx and cervical esophagus: a 20-year experience. *Ann Plast Surg* 1992;29(05):408–412
- Minami K, Inoue H, Kuba K, et al. Clinical analysis of free jejunal-autograft for pharyngo-esophageal reconstruction in patients with head and neck cancer. *J Saitama Med Sch* 2017;44:9–14
- Pattani KM, Byrne P, Boahene K, Richmon J. What makes a good flap go bad? A critical analysis of the literature of intraoperative factors related to free flap failure. *Laryngoscope* 2010;120(04):717–723
- Lin Y, He JF, Zhang X, Wang HM. Intraoperative factors associated with free flap failure in the head and neck region: a four-year retrospective study of 216 patients and review of the literature. *Int J Oral Maxillofac Implants* 2019;48(04):447–451
- Ohkubo JI, Wakasugi T, Takeuchi S, Takahashi A, Nguyen TN, Suzuki H. Biophysical properties of the neck skin indicating potential complications of salvage surgery for laryngeal/hypopharyngeal cancer. *Acta Otolaryngol* 2022;142(7–8):634–637
- Li N, Fei X, Li C, Zhao T, Jin H, Chen H. A rat model of esophago-gastric anastomotic stricture. *Eur Surg Res* 2022;63(04):294–301
- Marroni N, Casadevall M, Panés J, Piera C, Jou JM, Pique JM. Effects of chronic normovolemic anemia on gastric microcirculation and ethanol-induced gastric damage in rats. *Dig Dis Sci* 1994;39(04):751–757
- Marchiori C, Fede A, Bassano M, Nieri A. Normovolemic hemodilution in head and neck surgery. *Arch Otorhinolaryngol* 1989;246(05):333–335
- Gu YM, Yang YS, Shang QX, Wang WP, Yuan Y, Chen LQ. Risk factors for benign anastomotic stricture post-oesophagectomy: single-centre analysis of 702 oesophagectomies with squamous cell carcinoma. *Transl Cancer Res* 2019;8(03):828–835
- Nasu T, Koike S, Noda D, et al. A clinical analysis on the outcome of free jejunal-autograft for reconstruction in head and neck cancer patients. Postoperative complications and swallowing function. *Jpn J Head Neck Cancer* 2009;35:293–299
- Mori K, Sakata K, Hirano M, et al. Investigation of outcome of free jejunal autograft for head and neck reconstruction. Factors influencing on the success rate and swallowing function. *J Jpn Bronchoesophagol Soc* 1997;48:227–233
- Reece GP, Bengtson BP, Schusterman MA. Reconstruction of the pharynx and cervical esophagus using free jejunal transfer. *Clin Plast Surg* 1994;21(01):125–136
- Ueda Y, Takashima M, Hashimoto K. Methods for graft tissue monitoring after tissue transplantation using microsurgery; usefulness of pulse oximeter. *J Jpn Coll Surg* 1996;21:14–21
- Yano A, Orihashi K, Yoshida Y, Kuriyama M. Near-infrared spectroscopy for monitoring free jejunal flap. *J Plast Reconstr Aesthet Surg* 2021;74(01):108–115