




# Neuromonitoring in a Case with Midbrain Cavernoma Operated in Sitting Position: Unveiling the Complexities

Joslita Rebello<sup>1</sup>  Bhoomika Thakore<sup>1</sup>

<sup>1</sup> Department of Anesthesiology, P.D Hinduja Hospital and Medical Research Center, Mumbai, Maharashtra, India

J Neuroanaesthesiol Crit Care

**Address for correspondence** Joslita Rebello, MD, Department of Anesthesiology, P.D Hinduja Hospital and Medical Research Center, Mumbai 400016, Maharashtra, India (e-mail: joslitarebello@yahoo.com).

## Abstract

The sitting position is often utilized for mid-brain cavernoma excision due to its several surgical advantages. Intraoperative neuromonitoring aids dynamic functional assessment of neural structures in real-time. In this case report, we discuss the anesthetic management of a patient scheduled for midbrain cavernoma excision in a sitting position. Evoked potential monitoring was performed as the tumor was in proximity to cortico-spinal tracts. We used a combination of inhalational and intravenous anesthetics for the maintenance of anesthesia. Intraoperatively significant events included two episodes of venous air embolism, and loss of motor evoked potentials during the resection of the tumor. These complications were promptly recognized and managed. In the early postoperative period, the patient had motor power 3/5 in flexors of the right upper limb, which improved to normal by Day 5. Thus, good communication among anesthesiologists, neurologists, and surgeons helped identify altered evoked potential signals early, aiding the modification of dissection accordingly.

## Keywords

- ▶ midbrain cavernoma
- ▶ sitting position
- ▶ SSEP
- ▶ MEP
- ▶ venous air embolism

## Introduction

Midbrain tumors account for approximately 14.2 to 25% of cerebral cavernous malformations.<sup>1</sup> Between 80 and 100% present symptomatically due to hemorrhagic conversion.<sup>2</sup> Surgical resection is the definitive treatment, and goal is complete resection with sophisticated strategy. Complex neuroanatomy of midbrain can be challenging to both neuro-anesthesiologist and neurosurgeon. Sitting position is one among the many positions utilized for posterior fossa surgeries, due to the advantages offered in terms of better surgical exposure airway accessibility, better ventilation, and less bleeding due to venous drainage. Risks involved are venous air embolism (VAE), pneumocephalus, and ischemic injury.<sup>3</sup> Intraoperative neuromonitoring, namely somatosensory-evoked potential (SSEP) and motor-evoked potentials (MEP), are indicated for midbrain surgeries for

dynamic functional assessment of neural structures.<sup>4</sup> We hereby present a case report of woman posted for midbrain cavernoma excision in sitting position with SSEP, MEP, and bispectral index (BIS) monitoring.

## Case Presentation Report

A 56-year-old homemaker, known hypertensive and hypothyroid, weighing 75 kg presented with diplopia since 2 months. She was diagnosed with left midbrain cavernoma 3 years ago.

There was no history of nausea vomiting, blurring of vision, facial numbness, altered hearing, weakness or altered sensorium. There were no preoperative neurologic deficits. Perioperative magnetic resonance imaging brain (T2 and fluid-attenuated inversion recovery) showed 9.6 × 9.4 × 14.3 mm hyperdense lesion with popcorn appearance showing hemosiderin rim in left hemi midbrain. Extensive blooming

DOI <https://doi.org/10.1055/s-0044-1786516>.  
ISSN 2348-0548.

© 2024. The Author(s).

This is an open access article published by Thieme under the terms of the Creative Commons Attribution License, permitting unrestricted use, distribution, and reproduction so long as the original work is properly cited. (<https://creativecommons.org/licenses/by/4.0/>)

Thieme Medical and Scientific Publishers Pvt. Ltd., A-12, 2nd Floor, Sector 2, Noida-201301 UP, India

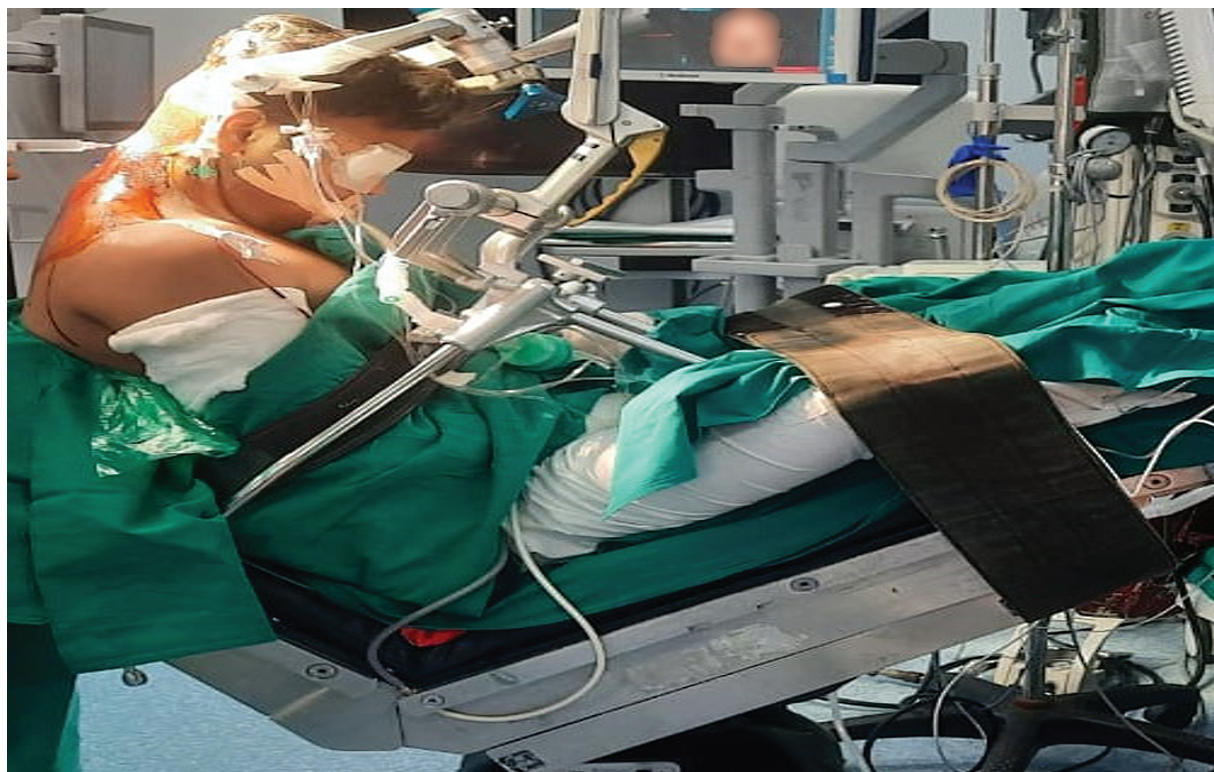on gradient echo images was suggestive of chronic hemorrhage. Diffusion tensor imaging (DTI) showed left-sided corticospinal tracts were anterolateral to the lesion and intact. Craniotomy and excision of midbrain cavernoma in sitting position was planned with MEP, SSEP, and BIS monitoring. Written informed consent was taken.

In the operating room, preinduction monitors, electrocardiography, pulse-oximetry, noninvasive blood pressure, were attached. General anesthesia and endotracheal intubation were facilitated by intravenous fentanyl—2 µg/kg, propofol—2mg/kg, and vecuronium—0.1 mg/kg. Postinduction temperature, invasive blood pressure, central venous pressure, transesophageal echo, MEP, SSEP, and BIS monitoring were done. Sitting position was gradually given over a span of 3 minutes, keeping a watch on hemodynamics (►Fig. 1). The patient tolerated the position well and did not require any vasopressors to maintain hemodynamics. Anesthesia was maintained by propofol infusion—100 to 150 µg/kg/min, fentanyl infusion—0.5 µg/kg/h, along with sevoflurane minimum alveolar concentration of 0.3 to 0.4, titrated to maintain a BIS of 40 to 60. Baseline MEP, SSEP in supine position as well as in sitting position were normal (►Fig. 2A). Surgical access to the cavernoma was achieved by midline suboccipital craniotomy. During the procedure, two episodes of VAE were detected by transesophageal echo. Sudden drop in end-tidal CO<sub>2</sub> from 27 to 23 mm Hg was noted. The surgeon was notified, surgical site was flooded with saline and packed with gauze, 10 mL of air was aspirated through central venous catheter, and bilateral jugular compression was given. There were no hemodynamic changes during the

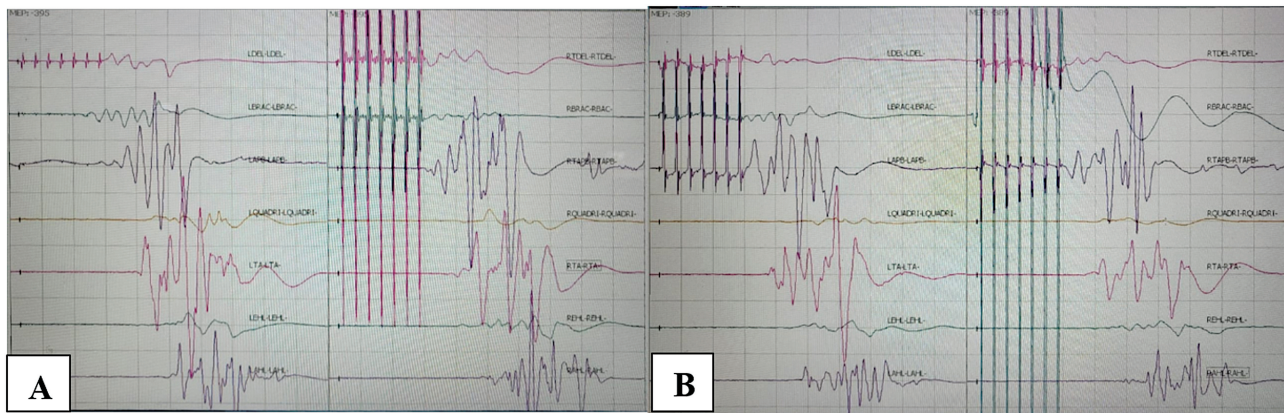
VAE. Throughout the procedure mean arterial pressure (MAP) was maintained above 90 mm Hg via pulse pressure variation-guided fluid therapy. During the resection of cavernoma, MEP signal of right brachioradialis was lost completely. Anesthetic and technical causes were ruled out. The stimulus intensity was increased in aliquots of 50V from 300 to 450V, but still no MEP was obtained from the right brachioradialis. The signal was not restored at the end of the procedure (►Fig. 2B). The total blood loss was 300 mL. Vasopressors were not used at any point of time during the surgery. Trachea was extubated at the end of surgery. The patient had power of 3/5 for flexion of right upper limb that was correlating with the MEP findings. The patient was shifted to intensive care unit for further postoperative monitoring. Postoperatively intravenous methylprednisolone (500 mg) was administered twice daily for 3 days. The power for flexion of right upper limb improved on postoperative day 5.

## Discussion

The median suboccipital supracerebellar approach to dorsal midbrain lesions requires patient to be in prone or sitting position. Sitting position gives potential advantages of good surgical field, access to airway and better ventilation. However, anatomical and physiological challenges, increased risk of VAE, hypotension, and tension pneumocephalus can be challenging and devastating. Functional integrity of descending motor pathways and their selective and specific assessment during critical surgical maneuvers is accomplished by MEP during brainstem surgeries especially those involving



**Fig. 1** Patient in the sitting position.



**Fig. 2** (A) Baseline motor-evoked potential (MEP). (B) Complete loss of MEP signals in right brachioradialis at the end of procedure.

the midbrain.<sup>4</sup> MEP altered signals can result due to surgical insult, hypotension, anesthetic agents, hypothermia, technical glitch, and brain shift.<sup>5,6</sup> Surgeries in semisitting position can alter the MEP and SSEP signals indirectly by drastically reducing the cardiac output during VAE. It is uncertain whether VAE impacts SSEPs and MEPs. It has been put forward, therefore, that VAE may result in MEP and SSEP alterations unrelated to neurological dysfunction.<sup>6,7</sup> In our case, VAE did not cause any change in the evoked potentials. MEP signals were lost for the right brachioradialis while dissecting the tumor. This could be due to handling of the left sided corticospinal tracts, which were anterolateral to the lesion as per the DTI scan.

Total intravenous anesthesia (TIVA) offers an advantage of early onset induction in addition to continuous monitoring of neuronal structures.<sup>8</sup> Further studies have shown that the neuroprotection offered by TIVA and inhalational agents had no significant differences. We therefore used a combination of TIVA (propofol and fentanyl) and inhalational agents (sevoflurane) to reduce the dose of one another and prevent untoward hemodynamic complications. Target-controlled infusion (TCI) is the TIVA technique that maintains a constant plasma concentration of the desired drug. However, literature shows both manual and TCI are reasonable methods to achieve BIS-guided TIVA.<sup>9</sup> We do not have a TCI pump in our institute, and hence we used the manual technique.

Sitting position requires absolute immobility aided through nondepolarizing muscle relaxants; however, their use in neuromonitoring, especially MEPs, is contraindicated and poses a challenge for the anesthesiologist. Thus, maintaining adequate depth of anesthesia is absolutely essential.<sup>10,11</sup>

Effective monitoring of depth of anesthesia is crucial during TIVA to prevent intraoperative awareness, which can have negative implications on patient. BIS values between 40 and 60 ensure adequate depth of anesthesia. Lee et al in their research concluded that sitting positions reduce BIS values in tandem with MAP when compared with supine position.<sup>12</sup> We ensured MAP of more than 90 mm Hg and BIS values between 40 and 60 at all times.

A thorough knowledge of the anatomy, physiology, anesthetic technique, methodical surgical dissection will assist in accurate interpretation of the altered sequence of MEP intraoperatively.

Standard-of-care anesthesia technique combining TIVA and inhalational anesthesia, offer a safe anesthesia and optimal surgical conditions in the absence of muscle relaxation.

## Conclusion

Midbrain cavernoma excision in sitting position with SSEP and MEP monitoring requires expertise, individualized anesthesia technique, and vigilance for complications. A multi-disciplinary discussion with anesthesiologist, surgeon, and neurologist is the key step in diagnosing intraoperative altered SSEP and MEP signals and, thus, the early detection of new neurological deficits during the procedures at midbrain.

## Conflict of Interest

None declared.

## References

- Hauck EF, Barnett SL, White JA, Samson D. Symptomatic brainstem cavernomas. *Neurosurgery* 2009;64(01):61–70, discussion 70–71
- Gross BA, Batjer HH, Awad IA, Bendok BR, Du R. Brainstem cavernous malformations: 1390 surgical cases from the literature. *World Neurosurg* 2013;80(1-2):89–93
- Goraksha S, Thakore B, Monteiro J. Sitting position in neurosurgery. *J Neuroanaesth Crit Care* 2019;7(02):77–83
- Sarnthein J, Bozinov O, Melone AG, Bertalanffy H. Motor-evoked potentials (MEP) during brainstem surgery to preserve corticospinal function. *Acta Neurochir (Wien)* 2011;153(09):1753–1759
- Kuwano A, Yamaguchi K, Funatsu T, et al. A case of cavernous malformation of the midbrain removed via an interhemispheric transcallosal subchoroidal approach. *NMC Case Rep J* 2022;9(00):337–342
- Acioly MA, Ebner FH, Hauser TK, et al. The impact of subdural air collection on intraoperative motor and somatosensory evoked potentials: fact or myth? *Acta Neurochir (Wien)* 2011;153(05):1077–1085
- Lee CC, Wu A, Li M. (2020). Venous Air Embolism During Neurosurgery. In: Brambrink, A., Kirsch, J. (eds) *Essentials of Neurosurgical Anesthesia & Critical Care*. Springer, Cham. [https://doi.org/10.1007/978-3-030-17410-1\\_44](https://doi.org/10.1007/978-3-030-17410-1_44)
- Zuleta-Alarcón A, Castellón-Larios K, Niño MC, Bergese SD. Total intravenous anaesthesia versus inhaled anaesthetics in neurosurgery. *Colombian J Anesthesiol*. 2015;43:9–14

- 9 Mu J, Jiang T, Xu XB, Yuen VM, Irwin MG. Comparison of target-controlled infusion and manual infusion for propofol anaesthesia in children. *Br J Anaesth* 2018;120(05):1049–1055
- 10 Sahinovic MM, Gadella MC, Shils J, Dulfer SE, Drost G. Anesthesia and intraoperative neurophysiological spinal cord monitoring. *Curr Opin Anaesthesiol* 2021;34(05):590–596
- 11 Myles PS. Depth of anaesthesia monitoring: updated evidence. Comment on *Br J Anaesth* 2023; 131: 196-9. *Br J Anaesth* 2023; 131(05):e145–e147
- 12 Lee SW, Choi SE, Han JH, Park SW, Kang WJ, Choi YK. Effect of beach chair position on bispectral index values during arthroscopic shoulder surgery. *Korean J Anesthesiol* 2014;67(04):235–239