



A Case of Spontaneous Intracranial Hematoma with Critically Low Platelet Count: A Neurointensivist's Nightmare

Sukhen Samanta¹ Malligere Prasanna¹

¹ Critical Care Institute, Cleveland Clinic Abu Dhabi, Abu Dhabi, United Arab Emirates

Address for correspondence Sukhen Samanta, MD, DM, MRCP, EDIC, Critical Care Institute, Cleveland Clinic Abu Dhabi, Abu Dhabi 112412, United Arab Emirates (e-mail: samants@clevelandclinicabudhabi.ae).

J Neuroanaesthesiol Crit Care

Abstract

Keywords

- ▶ immune thrombocytopenia
- ▶ intracranial hematoma
- ▶ critically low platelet counts

Complications of immune thrombocytopenia (ITP) are more frequent at a platelet count lower than 10,000/ μ L of blood. Intracranial hematoma (ICH) is one of the most severe complications of ITP. Subdural hematoma (SDH) and subarachnoid hemorrhage (SAH) usually occur as extensions of ICH and is generally spontaneous in nature. We report a case of ICH along with SDH and SAH who presented with critically low platelet count managed using apheresis platelet transfusion, desmopressin, intravenous immunoglobulin, and methylprednisolone. The patient was discharged successfully from hospital without any neurological deficit. The importance of early referral and immediate aggressive management and monitoring at an advanced center is suggested.

Introduction

Intracerebral hematoma (ICH) is a rare (1.4% in adults, <1% in children) but catastrophic complication of immune thrombocytopenia (ITP), with high mortality and morbidity.¹ The risk for bleeding depends upon the severity of thrombocytopenia. There is no robust guideline for urgent management of such ITP with ICH. Immediate treatment of ITP should only be considered if there is a high risk of bleeding. We describe a case of ITP with ICH in which immediate and aggressive interventions helped favorable outcome.

Case Report

A 25-year-old man presented with a history of a sudden onset severe headache for 4 days not relieved with paracetamol and aspirin. Computed tomographic (CT) scan of brain confirmed left-sided ICH in frontal region along with thin frontoparietal subdural hemorrhage (SDH), thickness less than 5 mm, scattered subarachnoid (SAH), and intraventricular hemorrhage, without midline shift. He had no history of visual disturbance, altered level of consciousness, photophobia, behavior change, fever, neck rigidity, seizure, and other infective symptoms.

The patient had no history of hematuria, oral or rectum bleeding. There was no significant past medical and surgical history except smoking. He presented with Glasgow Coma Scale of 15, pupils 3 mm equal and briskly reactive. He had generalized petechiae all over his body, multiple hematomas along his right flank, right shoulder and bilateral deltoid area. No hepatosplenomegaly or sternal tenderness demonstrated on examination. His admission platelet count was less than 1,000/ μ L. He was closely monitored in a neurocritical care unit (NCCU). In NCCU, we performed immediate CT head (**Fig. 1**), frequent complete hemogram, coagulation study, and thrombocytopenia workup. He was nonreactive for human immunodeficiency virus and hepatitis B and C virus. Dengue serology was negative. Metabolic panel was nonsignificant. Blood peripheral smear demonstrated no schistocytes to suggest thrombotic thrombocytopenia. Ultrasound abdomen demonstrated a 4.1 \times 3.5 cm slightly hyperechoic area in the posterior aspect of the left liver lobe. CT abdomen confirmed it as hepatic adenoma. Extensive immunologic workup revealed he was positive for antinuclear antibody (ANA) and anti-Ro antibody.

Close clinical and radiological monitoring in NCCU were of utmost priority. Systolic blood pressure was kept below 140 mm Hg to prevent hematoma extension. He received

DOI <https://doi.org/10.1055/s-0044-1786178>.
ISSN 2348-0548.

© 2024. The Author(s).

This is an open access article published by Thieme under the terms of the Creative Commons Attribution License, permitting unrestricted use, distribution, and reproduction so long as the original work is properly cited. (<https://creativecommons.org/licenses/by/4.0/>)

Thieme Medical and Scientific Publishers Pvt. Ltd., A-12, 2nd Floor, Sector 2, Noida-201301 UP, India

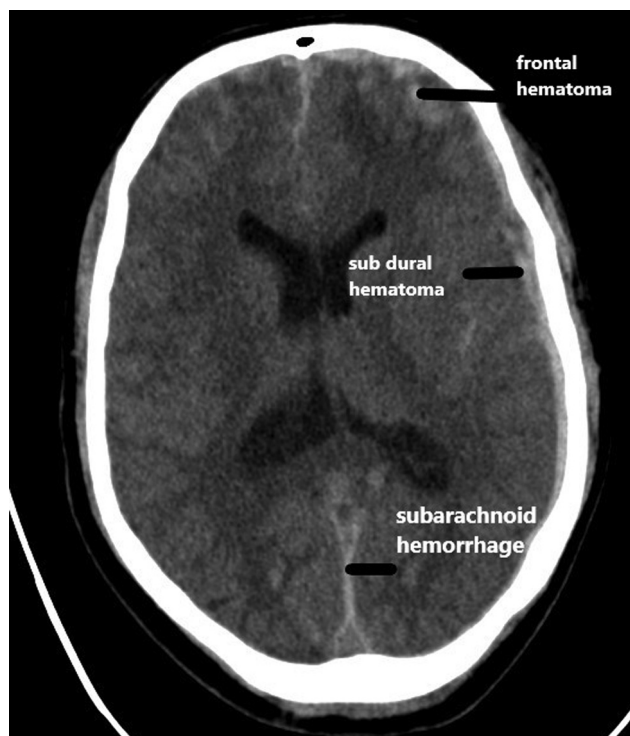


Fig. 1 Computed tomography scan of head on admission showing left-side frontal hematoma with thin subdural and subarachnoid hemorrhage.

transfusion with 4 units of apheresis platelet at the earliest. Neurosurgery and hematology physicians were consulted immediately. He was initially treated with IV desmopressin (DDAVP) 24 μg (0.4 $\mu\text{g}/\text{kg}$) over 20 to 30 minutes infusion in view of aspirin use, methylprednisolone 1 g daily for 3 days followed by oral prednisolone 1 mg/kg, two doses of intravenous immunoglobulin (IVIg) along with other supportive measures. Rituximab was kept for the next level of treatment. He clinically improved. Platelet count started improving and sustained at 57,000/ μL . Follow-up CT head after 6 days showed chronic changes of hematoma with decreased SAH (**Fig. 2**). He was discharged from hospital neurologically intact on oral prednisolone 40 mg daily. Follow-up has continued over telephone and he did not need any further hospitalization.

Discussion

ITP is characterized by decreased platelet count due to destruction and impaired platelet function by antibodies.² ICH in ITP may present as spontaneous supratentorial or infratentorial hematoma, epidural, SDH, and SAH. Platelet count less than 10,000/ μL is prone for spontaneous bleeding.¹ In our patient, admission platelet count was less than 1,000/ μL with manual count. To the best of our knowledge, ICH in ITP with such a critical platelet count has never been reported in literature. In a retrospective study, Zhao et al described 93 adult patients with ITP who developed ICH. They found trauma, platelet count less than 15,000/ μL at the time of ITP diagnosis, and severe life-threatening bleeding

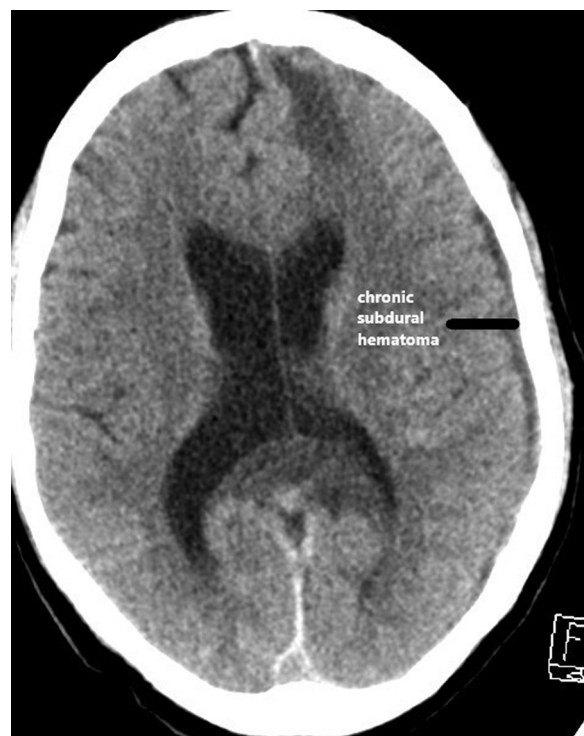


Fig. 2 Computed tomography scan of head on day 6 showing resolving and chronic subdural hematoma with resolving subarachnoid hemorrhage.

are the individual risk factors for ICH.³ Panicker et al reported seven cases of SDH from chronic ITP.⁴ This is in contrast to ICH, which occurs more frequently in acute ITP.⁵

The aim of management is to increase the platelet count as quickly as possible by platelet concentrate transfusions in critical situations like intracranial or intraocular bleed. This transfusion will prevent further expansion of ICH and rebleeding. We used DDAVP single bolus in view of recent use of aspirin for headache. Neurocritical care guidelines suggest administration of a single dose of DDAVP for ICH associated with antiplatelet agents.⁶ Prevention and control of raised intracranial pressure from hematoma expansion, rebleeding, or cerebral edema need frequent neurological monitoring along with radiological follow-up (hematoma size in imaging) to decide the need for surgical decompression. In case of raised intracranial pressure, aggressive treatment should be initiated immediately. Tier approach is well known but in such critical situations we can step up therapy. Prevention of secondary brain injury is of utmost importance to get favorable neurological outcome.⁷

Kurata et al reported association of auto antibodies in chronic ITP. Out of 66 patients, 29 were positive for ANA and 7 for anti-Ro antibodies.⁸ Our patient had positive ANA and anti-Ro antibody titer. This autoimmune process could lead to ITP. Treatment modalities target various aspects of ITP pathophysiology such as the inhibition of autoantibody production (decreased autoimmune process), modulation of T cell activity (with prolongation of platelets survival), and stimulation of platelet production. Corticosteroid therapy should be the first treatment of choice, but there is a high risk of relapse. Second-line therapy options include IVIg

and/or rituximab-an anti-CD 20 monoclonal antibody.⁹ Gellens et al reported two ITP patients with ICH treated with a newer drug romiplostim, a thrombopoietin receptor agonist, as an “on demand therapy” that resulted in rapid and sustained increase in platelets.¹⁰

Conclusion

Patients with ICH who have critically low platelet counts can benefit greatly from early referral to a specialized center, where they can receive close neurological and radiological monitoring and prompt medical interventions, which can significantly increase their chances of a good outcome.

Conflict of Interest

None declared.

References

- 1 Neunert C, Noroozi N, Norman G, et al. Severe bleeding events in adults and children with primary immune thrombocytopenia: a systematic review. *J Thromb Haemost* 2015;13(03):457–464
- 2 Cines DB, Bussel JB, Liebman HA, Luning Prak ET. The ITP syndrome: pathogenic and clinical diversity. *Blood* 2009;113(26):6511–6521
- 3 Zhao P, Hou M, Liu Y, et al. Risk stratification and outcomes of intracranial hemorrhage in patients with immune thrombocytopenia under 60 years of age. *Platelets* 2021;32(05):633–641
- 4 Panicker JN, Pavithran K, Thomas M. Management of subdural hematoma in immune thrombocytopenic purpura: report of seven patients and a literature review. *Clin Neurol Neurosurg* 2009;111(02):189–192
- 5 Lee MS, Kim WC. Intracranial hemorrhage associated with idiopathic thrombocytopenic purpura: report of seven patients and a meta-analysis. *Neurology* 1998;50(04):1160–1163
- 6 Frontera JA, Lewin JJ III, Rabinstein AA, et al. Guideline for reversal of antithrombotics in intracranial hemorrhage: executive summary. A statement for healthcare professionals from the Neurocritical Care Society and the Society of Critical Care Medicine. *Crit Care Med* 2016;44(12):2251–2257
- 7 Rangel-Castilla L, Gopinath S, Robertson CS. Management of intracranial hypertension. *Neurol Clin* 2008;26(02):521–541, x
- 8 Kurata Y, Miyagawa S, Kosugi S, et al. High-titer antinuclear antibodies, anti-SSA/Ro antibodies and anti-nuclear RNP antibodies in patients with idiopathic thrombocytopenic purpura. *Thromb Haemost* 1994;71(02):184–187
- 9 Neunert CE, Cooper N. Evidence-based management of immune thrombocytopenia: ASH guideline update. *Hematology (Am Soc Hematol Educ Program)* 2018;2018(01):568–575
- 10 Gellens R, Habchi S, Freppel S, Couret D, Iacobelli S. Romiplostim for emergency management of severe thrombocytopenia with intracerebral hemorrhage. *Front Neurol* 2018;8:737