



Trans-splenic Approach for Transjugular Intrahepatic Portosystemic Shunt (TIPS) Creation in Patients with Portal Vein Thrombosis

Maryam Boumezrag¹ George Lynskey² Saher Sabri¹

¹Medstar Georgetown University Hospital, Washington, District of Columbia, United States

²National Vascular Physicians, National Harbor, Maryland, United States

Address for correspondence Maryam Boumezrag, MD, Department of Interventional Radiology, Medstar Georgetown University Hospital, 3800 Reservoir Road NW, Washington, DC 20007, United States (e-mail: maryam.boumezrag@medstar.net).

Arab J Intervent Radiol

Abstract

Purpose The aim of this study was to evaluate the safety and efficacy of using a trans-splenic approach for transjugular intrahepatic portosystemic shunt (TIPS) creation in patients with portal vein thrombosis. (PVT).

Materials and Methods A retrospective review was performed on 36 consecutive patients with PVT who underwent TIPS using a trans-splenic approach from February 2018 to June 2021. Preprocedural data including demographic information and Model for End-Stage Liver Disease (MELD) scores were obtained. Outcomes measured included technical success, clinical success, complications, and survival.

Results Technical success was achieved in 32 of 36 patients (89%). During the follow-up period, 16 of 32 (50%) required secondary TIPS interventions, most of which were planned as part of a staged procedure. TIPS patency was 30/32 (94%) had stent patency on their most recent follow-up with a median follow-up of 164 days. No patients had variceal bleeding following TIPS. Eleven of thirty-two (34%) patients underwent successful transplant after TIPS. Anatomical portal vein end-to-end anastomosis was achieved in 11/12 (92%) patients.

Conclusion The trans-splenic approach to TIPS is a reliable alternative to traditional TIPS in patients with PVT and provides high technical and clinical success rates. This technique can also be utilized to improve future liver transplant outcomes by facilitating anatomic portal vein end-to-end anastomoses.

Keywords

- ▶ cirrhosis
- ▶ portal hypertension
- ▶ TIPS
- ▶ trans-splenic access
- ▶ transjugular intrahepatic portosystemic shunt

Introduction

Portal vein thrombosis (PVT) represents a well-documented complication of liver cirrhosis and can also occur in diverse clinical contexts, such as prothrombotic disorders, abdominal inflammatory conditions, and abdominal infections.¹ Given the heterogenous etiologies and presentation of PVT, consensus guidelines on its management remain ambiguous.² In cirrhotic patients with chronic PVT, treatment options include

anticoagulation, thrombolysis, and transjugular intrahepatic portosystemic shunt (TIPS).³ The cornerstone of treatment for noncirrhotic PVT is anticoagulation, with endovascular treatments reserved for patients who cannot tolerate or have failed anticoagulation.⁴

TIPS is a widely accepted procedure for secondary prevention of variceal bleeding and management of refractory ascites. In cirrhotic patients with concomitant PVT, indications for TIPS also include contraindications to anticoagulation, progression

DOI <https://doi.org/10.1055/s-0044-1785526>.
ISSN 2542-7075.

© 2024. The Author(s).

This is an open access article published by Thieme under the terms of the Creative Commons Attribution License, permitting unrestricted use, distribution, and reproduction so long as the original work is properly cited. (<https://creativecommons.org/licenses/by/4.0/>)

Thieme Medical and Scientific Publishers Pvt. Ltd., A-12, 2nd Floor, Sector 2, Noida-201301 UP, India

of thrombosis despite anticoagulation, and PVT in a liver transplant candidate. Given the technical challenges associated with nonvisualization of the portal vein during TIPS,⁵ portal vein recanalization using a trans-splenic approach has gained popularity.^{6,7} Herein, we present our experience with using a trans-splenic approach to TIPS in cirrhotic and noncirrhotic patients with PVT.

Materials and Methods

This study is a single-center, retrospective review of consecutive patients with PVT who underwent TIPS using a trans-splenic approach, from February 2018 to June 2021. This study was approved by our institutional review board. The need to obtain informed consent was waived due to the retrospective nature of the study design.

Electronic medical records were reviewed for demographic data, imaging data, technical details of the procedure, complications, and clinical outcomes. Demographic data recorded included the age and gender of the patient. The outcomes measured included technical success, clinical success, complications, and survival. Complications were classified using the Society of Interventional Radiology (SIR) Classification System for Complications by Outcome.⁸

The indication for trans-splenic access was secondary to failed attempts at traditional transjugular intrahepatic access or if the operator determined that such access is unlikely to be successful due to extent of PVT.

Patient Characteristics

A total of 36 patients with PVT were indicated for trans-splenic TIPS from February 2018 to June 2021. There were 27 men and 9 women, with a median age of 58 years (range, 19–73). Liver cirrhosis was present in 24 of 36 patients, with an average MELD of 18. Nineteen patients were listed for liver transplant. Twelve patients were noncirrhotic; of these, several had underlying hypercoagulability secondary to various etiologies including hormone replacement therapy, Crohn's disease, recent right hemicolectomy, polycythemia vera, prothrombin gene mutation, protein S deficiency, and methylenetetrahydrofolate reductase (MTHFR) mutation. Thirty patients had chronic PVT and 6 patients had acute or subacute PVT. None of the patients had malignant PVT. Patient characteristics are summarized in ►Table 1.

Indications for the procedure included worsening PVT despite anticoagulation (22%), recurrent variceal bleeding (22%), refractory ascites (21%), persistent abdominal pain (6%), hepatic encephalopathy (6%), and recanalization of portal vein for future transplantation (12.5%). Four patients had a prior failed attempt at conventional TIPS.

Procedure

The right neck and upper abdomen were prepared and draped in the usual sterile fashion. The right internal jugular vein was accessed using ultrasound guidance and a 10 Fr sheath was placed. Percutaneous splenic vein access was obtained under ultrasound guidance using a 21-gauge INRAD needle (INRAD, INC., Kentwood, Michigan, United

Table 1 Patient characteristics

	n (%)
Male	24 (73%)
Female	9 (27%)
Age (mean y ± SD)	58 ± 14.7
Indication for TIPS	
Persistent abdominal pain	6%
Worsening PVT despite anticoagulation	22%
Recurrent variceal bleeding	22%
Refractory ascites	21%
Hepatic encephalopathy	6%
PVT recanalization for future transplantation	12.5%

Abbreviations: PVT, portal vein thrombosis; SD, standard deviation; TIPS, transjugular intrahepatic portosystemic shunt.

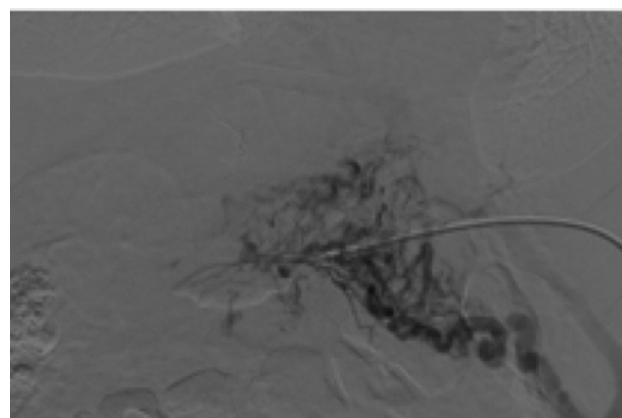


Fig. 1 Portal and splenic vein thrombosis with extensive collaterals.

States) that was exchanged for a 5 Fr sheath. A venogram was performed via the sheath to evaluate patient's anatomy and extent of PVT (►Fig. 1). Thirteen patients had balloon angioplasty of the portal vein alone and 8 had thrombectomy and angioplasty either during the initial procedure or a planned second procedure. The "gun-sight" technique, first described by Haskal et al in 1996,⁹ was used in 24 of 32 patients. In this subset of patients, a 15 mm snare (Amplatz gooseneck snare, Medtronic, Minneapolis, Minnesota, United States) was placed in the right or middle hepatic vein and a 20 mm snare was placed in the right or left portal vein. A 20-gauge Chiba needle (Cook Medical, Bloomington, Indiana, United States) was advanced through both snares (►Fig. 2) and through-and-through access was obtained (►Fig. 3). In the remaining eight patients, access was obtained using a standard TIPS access set (Cook Medical, Bloomington, Indiana, United States) with the snare in the portal vein branch as a target. Pressures were measured and direct portal venography was performed. A TIPS Viatorr stent (Gore, Flagstaff, Arizona, United States) was deployed, and pressure measurements and portal venography were repeated (►Fig. 4). Hemostasis was obtained using manual pressure for the internal jugular access site and combination of fibered coils

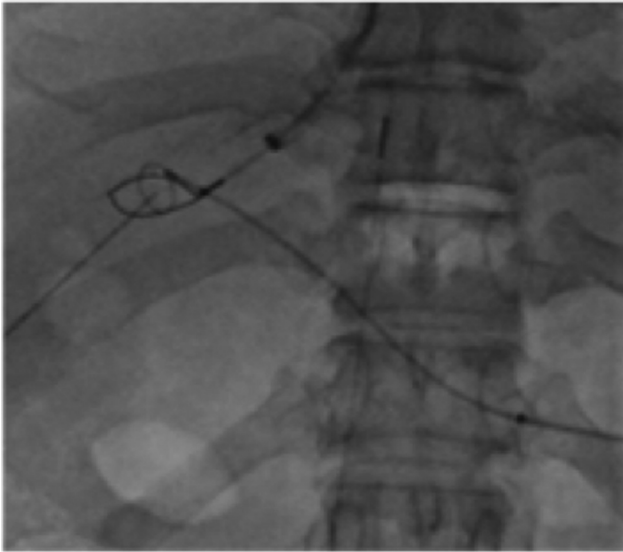


Fig. 2 20 g Chiba needle going through 10mm snare in the portal vein and 15 mm snare in the right hepatic vein.

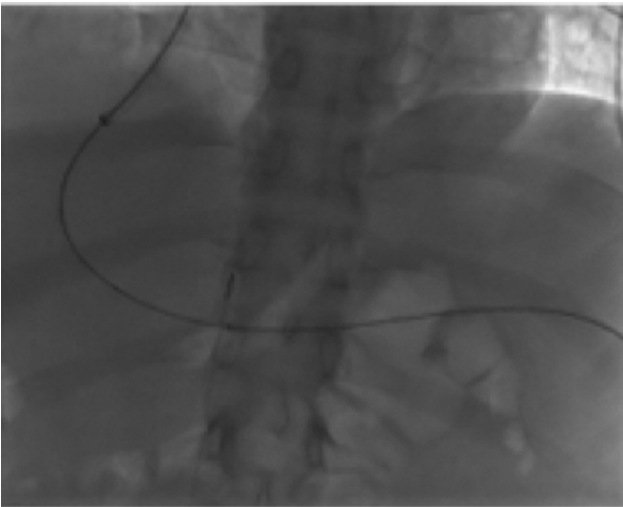


Fig. 3 Through-and-through access established with a 0.018 wire.

(-MReye, Cook Medical, Bloomington, Indiana, United States) and Gelfoam (Merit Medical, South Jordan, Utah, United States) or MVP lug (Medtronic, Minneapolis, Minnesota, United States) for the trans-splenic access.

Periprocedural Care

Anticoagulation was started 24 hours postprocedure for patients with noncirrhotic PVT and any cirrhotic patients with residual acute PVT postprocedure. Anticoagulation was continued indefinitely for patients with noncirrhotic PVT.

Results

Treatment Efficacy

Technical success was defined as successful recanalization of PVT and placement of TIPS with patency of the portal vein

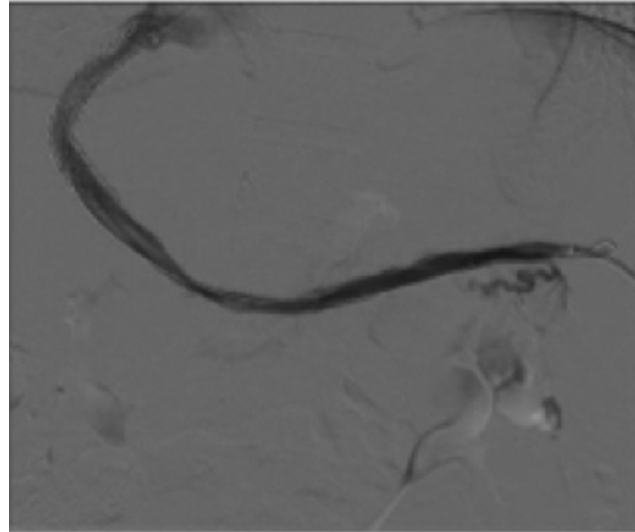


Fig. 4 Brisk flow without evidence of stenosis and resolution of collaterals.

and TIPS at the conclusion of the procedure. Technical success was achieved in 32 of the 36 patients (89%).

Adverse Events

Procedural complications occurred in 3 of 32 (9%) patients. One patient developed a perisplenic hematoma that was managed conservatively (Class B). A second patient developed hematemesis in the immediate postprocedural period. An arterioportal fistula was found on angiogram and was embolized with Gelfoam (Class C). One death occurred due to post-TIPS hepatic decompensation secondary to hepatic infarct (Class F).

Follow-Up

All patients underwent clinical and radiographic follow-up. Mean imaging follow-up period was 1,312 days (range, 1–1312 days; median, 164 days). During the follow-up period, 16 of 32 (50%) required a secondary TIPS intervention, most of which were planned as part of a staged procedure. Nine of thirty-two patients (28%) needed two or more reinterventions. Thirty of thirty-two patients (94%) had stent patency at last follow-up with median follow-up of 164 days. None of the patients had variceal bleeding following TIPS.

Twelve patients underwent successful liver transplant after TIPS. Anatomical end-to-end anastomosis was performed in 11 out of 12 patients.

Discussion

Our cohort was comprised of two subsets of patients: those with cirrhotic PVT and those with PVT secondary to other etiologies. In cirrhotic patients, the prevalence of PVT closely parallels the severity of patient's baseline liver disease.¹⁰ The cause-and-effect relationship between PVT and worsening outcomes is complex and highly debated.¹¹ While some studies suggest a lack of progression of liver decompensation despite development of PVT,¹⁰ and little to no effect on

overall survival,¹² Senzolo et al propose that while the effect of PVT may be inconsequential in patients with compensated cirrhosis (Child-Pugh A), patients with decompensated cirrhosis had a significantly higher chance of death at 2 years.¹³ Furthermore, there may be a significantly increased risk of failure to control active variceal bleeding in the setting of PVT.¹⁴

Treatment choice for cirrhotic PVT is based on numerous factors including chronicity, extent of thrombus, degree of portal hypertension, and transplant status. Several algorithms including the Shanghai consensus guidelines on management of cirrhotic PVT recommend treating acute to subacute symptomatic PVT with anticoagulation^{13,15} with the goal of preventing thrombus extension and reestablishing portal vein patency. Anticoagulation is also recommended for patients with chronic PVT causing greater than 50% stenosis, involvement of a mesenteric vein, and in transplant candidates, though the benefit must be weighed against bleeding risk on a case-by-case basis, including assessment of varices and initiation of variceal prophylaxis.³ In cases in which anticoagulation is contraindicated or there is progression of thrombus despite anticoagulation, TIPS can provide an alternative approach for portal vein recanalization.^{16,17}

In the subset of patients who are candidates for liver transplant, PVT was historically considered a contraindication. In recent years, advances have been made with the development of several new surgical techniques. The surgical treatment of choice for Yerdel grades 1, 2, and 3 is eversion thrombectomy.¹⁸ In more extensive cases (Yerdel grade 4), options include venovenous bypass, portal arterIALIZATION, and cavoportal hemitransposition.¹⁹ These non-anatomic techniques are associated with several complications including variceal bleeding, ascites, and renal dysfunction following portocaval hemitransposition, and aneurysmal dilatation of portal branches following portal arterIALIZATION.^{18,20} Given these complications, obtaining portal vein patency reduces morbidity and mortality, especially in cases with high-grade PVT. As seen with our cohort, trans-splenic TIPS can help achieve this goal and optimize post-transplant outcomes, paralleling results seen in other transplant centers.²¹

Within the noncirrhotic group, predisposing factors for PVT included hormonal therapy, Crohn's disease, recent right hemicolectomy, polycythemia vera, prothrombin gene mutation, protein S deficiency, and MTHFR mutation. In this subset of patients, treatment algorithms are also ambiguous and differ based on patient presentation, chronicity, and etiology. Historically, the cornerstone of treatment for acute PVT in noncirrhotic patients has been anticoagulation.² Similarly, anticoagulation is also generally accepted for patients with chronic PVT and an underlying malignancy or hypercoagulable disorder. In patients who are unable to tolerate anticoagulation or who have failed anticoagulation, several endovascular techniques have been proposed including thrombectomy, thrombolysis, balloon dilatation, and stenting.²² These techniques are associated with high rates of rethrombosis due to the low-pressure nature of the portal

venous system that requires a pressure gradient to achieve adequate outflow.²³ Given underlying coagulopathy in most of our patients with noncirrhotic PVT, postprocedural anticoagulation was continued indefinitely. All our noncirrhotic patients had stent patency on their most recent imaging follow-up.

With regard to trans-splenic access, which was historically associated with increased risk of complications,²⁴ our experience was congruent with more recent literature demonstrating the relative safety of this approach,²⁵ with only one access-related complication in our 32 patients. This complication was a small perisplenic hematoma that was treated conservatively.

This study has several limitations including its retrospective nature and small sample size. Additionally, absence of a control group prevents direct comparisons with alternative treatment approaches and limits the establishment of causal relationships.

Conclusion

The trans-splenic approach to TIPS is a reliable alternative to traditional TIPS in patients with PVT and provides high technical and clinical success rates. This technique can also be utilized to improve liver transplant eligibility by allowing anatomic end-to-end anastomoses.

Conflict of Interest

None declared.

References

- Rajani R, Björnsson E, Bergquist A, et al. The epidemiology and clinical features of portal vein thrombosis: a multicentre study. *Aliment Pharmacol Ther* 2010;32(09):1154–1162
- Wu M, Schuster M, Tadros M. Update on management of portal vein thrombosis and the role of novel anticoagulants. *J Clin Transl Hepatol* 2019;7(02):154–164
- Gadani S, Partovi S, Levitin A, et al. Narrative review of portal vein thrombosis in cirrhosis: pathophysiology, diagnosis, and management from an interventional radiology perspective. *Cardiovasc Diagn Ther* 2022;12(01):135–146
- Klinger C, Riecken B, Schmidt A, et al. Transjugular local thrombolysis with/without TIPS in patients with acute non-cirrhotic, non-malignant portal vein thrombosis. *Dig Liver Dis* 2017;49(12):1345–1352
- Sharma AK, Kaufman DC. TIPS performed in a patient with complete portal vein thrombosis. *Radiol Case Rep* 2017;12(02):327–330
- Tuite DJ, Rehman J, Davies MH, Patel JV, Nicholson AA, Kessel DO. Percutaneous transsplenic access in the management of bleeding varices from chronic portal vein thrombosis. *J Vasc Interv Radiol* 2007;18(12):1571–1575
- Zhu K, Meng X, Zhou B, et al. Percutaneous transsplenic portal vein catheterization: technical procedures, safety, and clinical applications. *J Vasc Interv Radiol* 2013;24(04):518–527
- Sacks D, McClenny TE, Cardella JF, Lewis CA. Society of Interventional Radiology clinical practice guidelines. *J Vasc Interv Radiol* 2003;14(9 Pt 2):S199–S202
- Haskal ZJ, Duszak R Jr, Furth EE. Transjugular intrahepatic trans-caval portosystemic shunt: the gun-sight approach. *J Vasc Interv Radiol* 1996;7(01):139–142

- 10 Nery F, Chevret S, Condat B, et al; Groupe d'Etude et de Traitement du Carcinome Hépatocellulaire. Causes and consequences of portal vein thrombosis in 1,243 patients with cirrhosis: results of a longitudinal study. *Hepatology* 2015;61(02):660–667
- 11 Shukla A, Giri S. Portal vein thrombosis in cirrhosis. *J Clin Exp Hepatol* 2022;12(03):965–979
- 12 Maruyama H, Okugawa H, Takahashi M, Yokosuka O. De novo portal vein thrombosis in virus-related cirrhosis: predictive factors and long-term outcomes. *Am J Gastroenterol* 2013;108(04):568–574
- 13 Senzolo M, Riva N, Dentali F, Sartori MT, Ageno WIRSVT Study Investigators. Portal vein thrombosis in decompensated cirrhosis: rationale for treatment. *Clin Transl Gastroenterol* 2019;10(04):e00026
- 14 D'Amico G, De Franchis RCooperative Study Group. Upper digestive bleeding in cirrhosis. Post-therapeutic outcome and prognostic indicators. *Hepatology* 2003;38(03):599–612
- 15 Hepatobiliary Disease Study Group, Chinese Society of Gastroenterology, Chinese Medical Association. Consensus for management of portal vein thrombosis in liver cirrhosis (2020, Shanghai). [published correction appears in *J Dig Dis*. 2021 May;22(5):295] *J Dig Dis* 2021;22(04):176–186
- 16 Thornburg B, Desai K, Hickey R, et al. Portal vein recanalization and transjugular intrahepatic portosystemic shunt creation for chronic portal vein thrombosis: technical considerations. *Tech Vasc Interv Radiol* 2016;19(01):52–60
- 17 Qi X, Han G. Transjugular intrahepatic portosystemic shunt in the treatment of portal vein thrombosis: a critical review of literature. *Hepatol Int* 2012;6(03):576–590
- 18 Paskonis M, Jurgaitis J, Mehrabi A, et al. Surgical strategies for liver transplantation in the case of portal vein thrombosis—current role of cavoportal hemitransposition and renoportal anastomosis. [published correction appears in *Clin Transplant*. 2006 Nov-Dec;20(6):799] *Clin Transplant* 2006;20(05):551–562
- 19 Robles R, Fernandez JA, Hernández Q, et al. Eversion thromboendovenectomy in organized portal vein thrombosis during liver transplantation. *Clin Transplant* 2004;18(01):79–84
- 20 Bonnet S, Sauvagnet A, Bruno O, et al. Long-term survival after portal vein arterialization for portal vein thrombosis in orthotopic liver transplantation. *Gastroenterol Clin Biol* 2010;34(01):23–28
- 21 Habib A, Desai K, Hickey R, et al. Portal vein recanalization-transjugularintrahepatic portosystemic shunt using the trans-splenic approach to achieve transplant candidacy in patients with chronic portal vein thrombosis. *J Vasc Interv Radiol* 2015;26(04):499–506
- 22 Bilbao JI, Vivas I, Elduayen B, et al. Limitations of percutaneous techniques in the treatment of portal vein thrombosis. *Cardiovasc Intervent Radiol* 1999;22(05):417–422
- 23 Bilbao JI, Elorz M, Vivas I, Martínez-Cuesta A, Bastarrika G, Benito A. Transjugular intrahepatic portosystemic shunt (TIPS) in the treatment of venous symptomatic chronic portal thrombosis in non-cirrhotic patients. *Cardiovasc Intervent Radiol* 2004;27(05):474–480
- 24 Probst P, Rysavy JA, Amplatz K. Improved safety of splenoportography by plugging of the needle tract. *AJR Am J Roentgenol* 1978;131(03):445–449
- 25 Chu HH, Kim HC, Jae HJ, et al. Percutaneous transsplenic access to the portal vein for management of vascular complication in patients with chronic liver disease. *Cardiovasc Intervent Radiol* 2012;35(06):1388–1395