



A Cross-Sectional Cone-Beam Computed Tomography Study of Root Canal Morphology and Configuration of Mandibular Premolars in Saudi and Sudanese Subpopulations

Lina Salah¹ Hussain M. Alkhamis² Zokaa Alhaj¹ Saleh M. A. Al-Jubran² Aseel Mohammed¹
Hussain H. I. Baleis² Najj M. M. Almاده² Amir I. O. Ibrahim²

¹Department of Restorative Dentistry, University of Khartoum, Khartoum, Sudan

²Department of Restorative Dentistry, College of Dentistry, King Faisal University, Al-Ahsa, Saudi Arabia

Address for correspondence Amir Isam Omer Ibrahim, BDS, MSc, PhD, Department of Restorative Dentistry, College of Dentistry, King Faisal University, P.O. Box 400, Al-Ahsa 31982, Saudi Arabia (e-mail: dr.aio.ibrahim@gmail.com; aiibrahim@kfu.edu.sa).

Eur J Gen Dent

Abstract

Objective To evaluate and compare the root canal morphology of mandibular premolars in Saudi and Sudanese subpopulations and between males and females within each group using cone-beam computed tomography (CBCT).

Materials and Methods A cross-sectional study was done between May 2022 and July 2023. Six hundred premolars from Saudi and Sudanese subpopulations were evaluated using CBCT for their number of roots, type of root canal configuration based on Vertucci's classification, and average canal length measured from the buccal cusp tip to the root end.

Statistical Analysis Statistical comparisons were made between males and females within each subpopulation and the two subpopulations using the chi-square test for root number and type of root canal configuration and an independent sample *t*-test for the canal length.

Results Most mandibular premolars in both subpopulations had a single root, with type I root canal configuration. However, Sudanese showed various canal configurations (I, II, III, IV, and V) compared with Saudis, which was statistically significant in the first canal of the first mandibular premolar ($p < 0.05$). Also, there were statistically significant differences in canal length between Saudi males and females ($p < 0.05$) and between Saudis and Sudanese ($p < 0.05$) in the first and second premolars.

Conclusion Although most mandibular premolars in Saudi and Sudanese subpopulations exhibited a single root and type I canal configuration, variations exist between and within the groups, highlighting ethnic and gender differences and emphasizing the need for dentists' attention.

Keywords

- ▶ cone-beam computed tomography
- ▶ mandibular premolar
- ▶ root canal configuration
- ▶ Saudi subpopulation
- ▶ Sudanese subpopulation
- ▶ Vertucci's classification

DOI <https://doi.org/10.1055/s-0044-1785474>.
ISSN 2320-4753.

© 2024. The Author(s).

This is an open access article published by Thieme under the terms of the Creative Commons Attribution License, permitting unrestricted use, distribution, and reproduction so long as the original work is properly cited. (<https://creativecommons.org/licenses/by/4.0/>)
Thieme Medical and Scientific Publishers Pvt. Ltd., A-12, 2nd Floor, Sector 2, Noida-201301 UP, India

Introduction

The main aim of endodontic treatment is to remove any microbial contamination from the entire root canal system using mechanical and chemical debridement and three-dimensionally seal the root canal system to prevent recontamination.^{1,2} The internal anatomy of the root canal system can affect the mechanical and chemical debridement since a single canal can be divided into several canals and fuse at any point along the length of the root canal system.^{3,4} The root canal anatomical variations (root canal configuration) were studied and evaluated by Vertucci⁵ into eight types according to the number of canals, orifices, and divisions along its course.

Radiographic evaluation of the root canal configuration before endodontic treatment is essential to determine the type of root canal configuration and, hence, the anatomical complexity of the root canal system.⁶ Periapical radiographs may not provide enough detail about the root canal structure because the three-dimensional anatomy of the radiographed area is compressed into a two-dimensional image, leading to overlapping structures.⁷ In 1973, Hounsfield developed the first computed tomography device to capture different tissues in a three-dimensional view.⁸ Cone-beam computed tomography (CBCT) is a type of radiograph that enables the viewing of objects in three dimensions (axial, sagittal, and coronal), hence better visualization of root canal internal anatomy⁹ and visualization of accurate geometry of scanned objects.¹⁰

Most of mandibular premolars possess single canal and a single periapical foramen.¹¹ However, anatomical variations regarding the root canal anatomy of mandibular premolars were reported among different ethnic groups and genders.^{12–15} Proper knowledge of this anatomical variation is critical because it can affect the outcome of root canal treatment, especially in places with different ethnic groups. Saudi Arabia and Sudan are well known for their population mix. Several studies evaluated the root canal morphology of Saudi subpopulations.^{16–18} A recent study¹⁸ reviewed the root canal configuration of mandibular premolars in the Saudi subpopulation. They found that most mandibular first premolars had a single root (86.6%), with a single canal (91.5%) and type I root canal configuration (96.9%).

The literature is lacking studies that evaluate the root canal morphology of mandibular premolar in Sudanese population. Therefore, this study aimed to evaluate and compare the number of roots, type of root canal configurations, and the average canal length of mandibular first and second premolars in the Saudi and Sudanese subpopulations using CBCT images.

Materials and Methods

A cross-sectional descriptive study was done between May 2022 and July 2023. The CBCT images were collected from the dental complex at King Faisal University in Al-Hasa (Saudi Arabia) and the 3D Scan Centre, Dental Radiology Centre in Khartoum (Sudan). Ethical approval was obtained

from the ethical research committee at King Faisal University, Saudi Arabia (KFU-REC-2023-JUN-ETHICS1008). A written permission was obtained from both centers to access their CBCT image databases. All patients' data were kept anonymous.

The samples were collected using convenience sampling. The inclusion criteria for this study were: Sudanese and Saudis (males and females), ≥ 18 years, presence of one of the mandibular premolars on either side (right or left) with no congenital disturbances or anomalies. The exclusion criteria involved the presence of previous root canal treatment, complex restorations, or extensive carious lesions, along with the presence of root resorption or periapical lesions. The collected data included 359 CBCT images.

CBCT Technique

One hundred eighty-three CBCT images were evaluated for the Saudis using I-CT Vision QTM (Imaging Sciences International, Hatfield, Pennsylvania, United States). The CBCT images were captured at a voltage of 120 kV, a current of 5 mA, and a field of view of 13×16 cm with a voxel size of 250 μ m. The CBCT images were evaluated with the Vision i-CT software program's measurement tool (version 1.9.3.14, Imaging Sciences International). For the Sudanese, 176 CBCT images were evaluated. The images were captured using Planmeca ProMax 3D Classic (Helsinki, Finland) at 90 kV voltage, 12 mA current, 160 μ m voxel size, and 88 cm field of view. The images were viewed and evaluated using Planmeca Romexis Viewer software (version 6.1.0.997, Helsinki, Finland).

Image Analysis

The total number of premolars evaluated was 600, 300 from the Saudis and 300 from the Sudanese; 150 first and 150 second premolars were evaluated in each subpopulation. The patient's gender was recorded, corresponding to the CBCT image captured. Each premolar was viewed in three different plans (coronal, sagittal, and axial) (**► Fig. 1**) using Vision i-CT software for the Saudis and Planmeca Romexis Viewer software for the Sudanese. Each premolar was evaluated for the number of roots, type of root canal configuration (according to Vertucci's classification), and canal length measured from the buccal cusp tip to the apex (measured with the Vision i-CT software and Planmeca Romexis Viewer software measuring tools). The observers were trained and calibrated with another senior staff from the radiology department. Three observers analyzed each image of each subpopulation.

Statistical Analysis

The data were collected, organized, and analyzed using Statistical Package for Social Sciences (SPSS) software (version 25; IBM, Armonk, New York, United States). A descriptive analysis was performed following data collection. Furthermore, a comparison was made between Saudi and Sudanese regarding the number of roots and type of root canal configuration present in first and second mandibular premolars using the chi-square test. A comparison was also

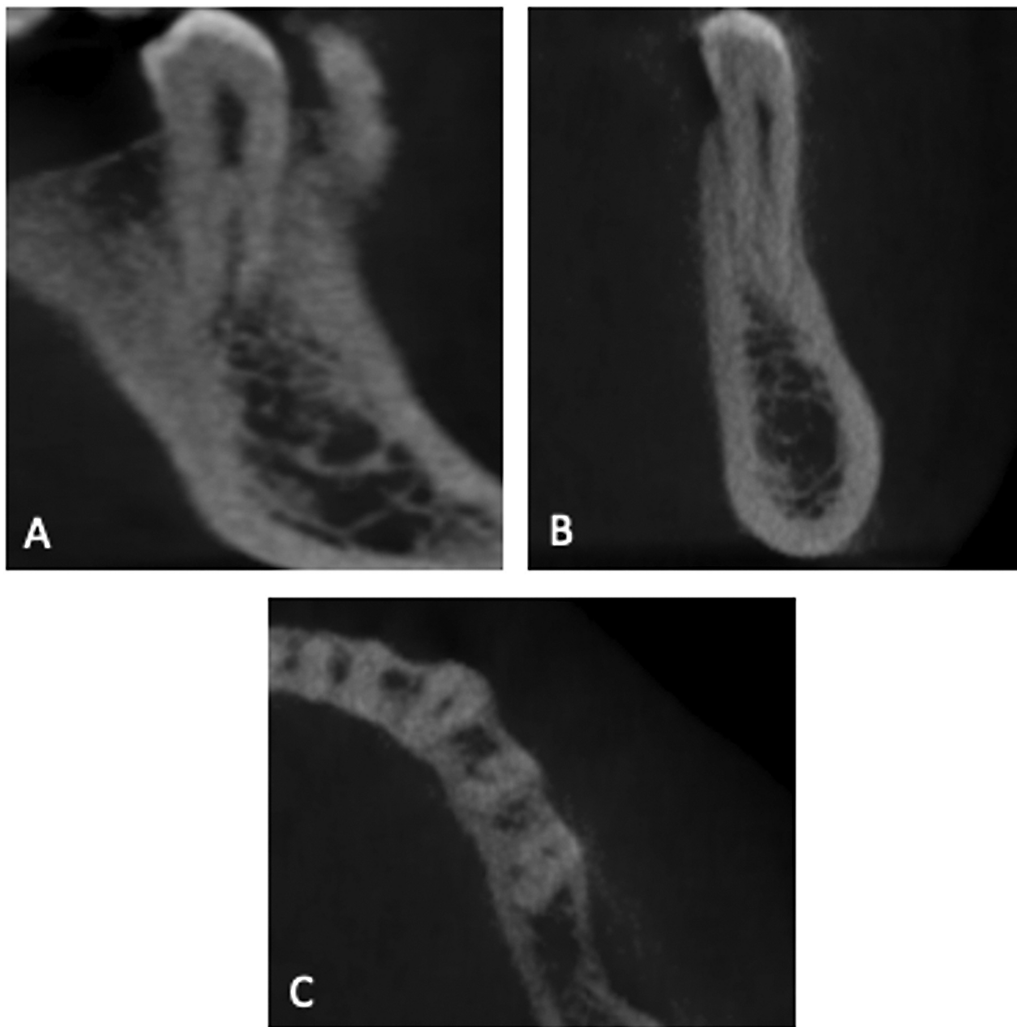


Fig. 1 Sagittal view (A) showing two roots of mandibular second premolar, Coronal view (B) showing type III of root canal configuration, and axial (C) views exhibiting two canals of mandibular first and second premolars.

made between the average root canal length of the first and second mandibular premolars in Saudi and Sudanese using the independent sample *t*-test.

Results

In this study, 600 mandibular premolars were evaluated, 300 from the Saudis and 300 from the Sudanese; 150 first and 150 second premolars were evaluated in each subpopulation. The percentage of male and female participants in the Saudi were 57 and 43%, respectively, and 35 and 65% in the Sudanese, respectively (► **Fig. 2**).

Saudi males had single roots in 95.5 and 98.8% of their first and second mandibular premolars, respectively. However, two roots were observed in 4.5% of male participants' first premolars and 1.2% of male participants' second premolars. Furthermore, females had only one root in their first and second premolars. There was no statistical difference between males and females in the number of roots in the first ($p = 0.089$) and second mandibular premolars ($p = 0.367$). In the Sudanese subpopulation, the percentage of single roots observed in the first mandibular premolar was 88.9% in male

participants and 95.8% in female participants; 11.1% of male participants had two roots compared with 4.2% of females, with no statistical difference between males and females ($p = 0.102$). Furthermore, most mandibular second premolars had a single root (92.2% in males and 99% in females), compared with two roots in 7.8% of male participants and only 1% in female participants. There was a statistical difference between Sudanese males and females ($p = 0.027$) in the number of roots of the second mandibular premolars (► **Table 1**). Clinically, it is important to consider the possibility of a second root, especially in Saudi male patients and in all Sudanese patients.

When the number of roots was compared based on population, the percentage of single and two roots in the first premolar of the Saudis was 97.3 and 2.7%, respectively, compared with 93.3% (single root) and 6.7% (two roots) in Sudanese. There was no statistical difference regarding the number of roots in the first mandibular premolar between the Saudis and Sudanese ($p = 0.101$). On the other hand, the second mandibular premolar was single rooted in 99.3% and two roots in 0.7% of Saudis compared with 96.7% (single root) and 3.3% (two roots) in Sudanese. Again, there was no

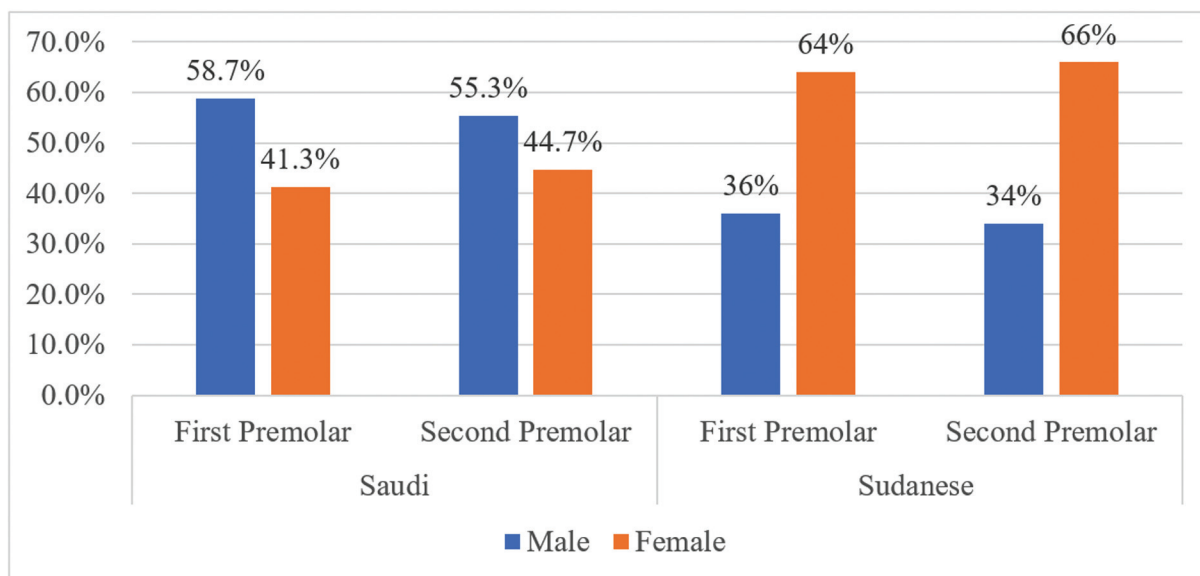


Fig. 2 The frequency (percentage) of first and second mandibular premolars according to gender among Saudis and Sudanese subpopulation.

statistical difference regarding the number of roots in the second mandibular premolar between the Saudis and Sudanese ($p = 0.099$) (►Table 2).

Each root was evaluated for the canal configuration type according to Vertucci's classification. The majority (98%) of mandibular first premolars in the Saudi subpopulation had a type I root canal configuration, followed by type V (1.3%), with type III being the least common (0.7%). Similarly, the second mandibular premolar of the Saudi subpopulation showed type I root canal configuration as a major type observed (98.7%), followed by type V (1.3%). For the Sudanese subpopulation, the root canal configurations of the first mandibular premolar showed type I (82%), III (10.7%), IV (0.7%), and V (6.7%) in the first root. The second mandibular premolar showed type I (96%), II (0.7%), III (0.7%), and V. (2.7%) root canal configurations. If a second root was present in the first or second mandibular premolar, type I was the only root canal configuration observed in both subpopulations. When the two subpopulations were compared, there was a statistically significant difference in the types of root canal configurations observed only in the first mandibular premolar ($p < 0.05$). This finding suggests that dental practitioners should pay greater attention to the unique anatomical characteristics of the Sudanese population when performing root canal treatments in mandibular premolars. Proper identification and management of these variations can help ensure optimal outcomes and reduce the risk of complications. The distribution of different types of canal configurations observed in Saudis and Sudanese based on gender is represented in ►Table 3.

The mean length of the first canal in Saudi's single-rooted first mandibular premolar was 19.4 mm, and 19.5 mm if a second canal was present. In the case of two roots, the second root had a mean canal length of 20.4 mm. The mean length of the second mandibular premolar was 19.9 mm, and 19.8 mm if a second canal was observed in a single-rooted tooth. On the other hand, a second root (if present) had a mean canal length of 21.95 mm.

The single-rooted first mandibular premolars in the Sudanese had a mean length of 20.29 mm in the first canal and 20.52 mm in the second canal, if present. The average canal length when a second root was present was 18.98 mm. The mean canal length of a single-rooted second mandibular premolar was 20.54 mm in the first canal, and 21.10 mm if the second canal was present. The mean canal length of the second root (if observed) was 19.87 mm. The mean length of each canal in Saudi and Sudanese males and females is presented in ►Table 4. By comparing the two subpopulations, there was a statistical difference in the root canal length of the first and second mandibular premolars if a single root was observed ($p < 0.05$) (►Table 5).

Discussion

Detection of anatomical variations of the root canal system prior to endodontic treatment is essential and valuable to predict the difficulty of endodontic treatment. Hence, optimal treatment options can be delivered. CBCT is one of the radiographic images that allows an in-depth and better understanding and visualization of the internal and external root anatomy (root canal system) and to detect any periapical pathology in a three-dimensional view.^{19,20} Mandibular premolars are one of the teeth that showed multiple anatomical variations among different ethnic groups.¹³⁻¹⁵

In this study, it was difficult to standardize the protocol for CBCT images as two different devices were used in Saudi and Sudan, which may compromise the collection of standardized images for comparison. A similar device is recommended in future studies to reduce the possible error during comparison. The CBCT images analyzed in this study represent only a sample of the population attending the two radiological centers at the time of the study, which may be one of the study's shortcomings and may not provide a complete representation of both populations. However, the

Table 1 The distribution (percentage and frequency) of root canal configurations observed in Saudis' and Sudanese's first and second mandibular premolars

Population	Gender	First mandibular premolar										Second mandibular premolar										
		Type of root canal configuration										Type of root canal configuration										
		First root					Second root					First root					Second root					
		I	III	IV	V		p-value	Second root	p-value	I	II	III	V		p-value	Second root	p-value	I	II	III	V	
Saudi	Male	85 (96.6%)	1 (1.1%)	-	2 (2.3%)	0.34	4 (100%)	-	81 (97.6%)	-	-	2 (2.4%)	0.20	1 (100%)	-	-	1 (100%)	-	-	-	-	-
	Female	62 (100%)	-	-	-		-	-	67 (100%)	-	-	-		-	-	-	-	-	-	-	-	-
Sudanese	Male	42 (77.8%)	8 (14.8%)	-	4 (7.4%)	0.54	6 (100%)	-	49 (96.1%)	-	1 (2%)	1 (2%)	0.46	4 (100%)	-	-	4 (100%)	-	-	-	-	-
	Female	81 (84.4%)	8 (8.3%)	1 (1%)	6 (6.3%)		4 (100%)	-	95 (96%)	1 (1%)	0 (0%)	3 (3%)		1 (100%)	-	-	1 (100%)	-	-	-	-	-
Total (Comparison between the two populations)	Saudi	147 (98%)	1 (0.7%)	0 (0.0%)	2 (1.3%)	<0.05 ^a	4 (100%)	-	148 (98.7%)	0	0	2 (1.3%)	0.44	1 (100%)	-	-	1 (100%)	-	-	-	-	-
	Sudanese	123 (82%)	16 (10.7%)	1 (0.7%)	10 (6.7%)		10 (100%)	-	144 (96.0%)	1 (0.7%)	1 (0.7%)	4 (2.7%)		5 (100%)	-	-	5 (100%)	-	-	-	-	-

Abbreviations: ^a Significant with Chi-square test.

Table 2 Comparison between males' and females' root canal length observed in Saudi and Sudanese subpopulations' first and second mandibular premolars

Root number	Root canal length	Nationality	Gender	First mandibular premolar					Second mandibular premolar					p-Value
				N	Mean	Mean Difference (S.E.)	95% confidence interval of the difference	p-Value	N	Mean	Mean Difference (S.E.)	95% confidence interval of the difference		
First root	First canal	Saudi	Male	88	19.95	1.30 (0.28)	0.75-1.86	<0.05 ^a	83	20.42	1.22 (0.31)	0.61-1.84	<0.05 ^a	
			Female	62	18.65				67	19.20				
	Sudanese	Male	54	20.52	0.36 (0.32)	-0.27-0.98	0.26	51	20.53	-0.01 (0.29)	-0.58-0.57	0.98		
		Female	96	20.16				99	20.54					
Second canal	Saudi	Male	3	19.50	-	-	-	2	19.77	-	-	-		
		Female	0	-				0	-					
Second root	First canal	Saudi	Male	12	21.00	0.86 (0.69)	-0.55-2.28	0.22	1	19.48	-2.02 (1.92)	-8.13-4.09	0.37	
			Female	15	20.13				4	21.50				
	Sudanese	Male	4	20.42	-	-	-	1	21.95	-	-	-		
		Female	0	-				0	-					
Second canal	Sudanese	Male	6	19.44	1.15 (0.90)	-0.92-3.22	0.24	4	20.29	2.09 (2.66)	-6.38-10.56	0.49		
		Female	4	18.29				1	18.20					

Abbreviations: N, number.

SE, standard error.

^aSignificant with independent t-test

Table 3 The distribution (percentage and frequency) of root canal configurations observed in Saudis' and Sudanese' first and second mandibular premolars

Population	Gender	Second mandibular premolar												
		First mandibular premolar					Second mandibular premolar							
		Type of root canal configuration					Type of root canal configuration							
First root		Second root		p-Value	First root		Second root		p-Value	First root		Second root		p-Value
I	III	IV	V		I	II	III	V		I	II	III	V	
Saudi	Male	85 (96.6%)	1 (1.1%)	-	2 (2.3%)	4 (100%)	0.34	81 (97.6%)	-	-	2 (2.4%)	1 (100%)	0.20	-
	Female	62 (100%)	-	-	-	-	-	67 (100%)	-	-	-	-	-	-
Sudanese	Male	42 (77.8%)	8 (14.8%)	-	4 (7.4%)	6 (100%)	0.54	49 (96.1%)	-	1 (2%)	1 (2%)	4 (100%)	0.46	-
	Female	81 (84.4%)	8 (8.3%)	1 (1%)	6 (6.3%)	4 (100%)	<0.05 ^a	95 (96%)	1 (1%)	0 (0%)	3 (3%)	1 (100%)	0.44	-
Total (comparison between the two populations)	Saudi	147 (98%)	1 (0.7%)	0 (0.0%)	2 (1.3%)	4 (100%)		148 (98.7%)	0	0	2 (1.3%)	1 (100%)		
	Sudanese	123 (82%)	16 (10.7%)	1 (0.7%)	10 (6.7%)	10 (100%)		144 (96.0%)	1 (0.7%)	1 (0.7%)	4 (2.7%)	5 (100%)		

^aSignificant with Chi-square test.

Table 4 Comparison between males' and females' root canal length observed in Saudi and Sudanese subpopulations' first and second mandibular premolars

Root number	Root canal length	Nationality	Gender	First mandibular premolar					Second mandibular premolar				
				N	Mean	Mean difference (SE)	95% confidence interval of the difference	p-Value	N	Mean	Mean difference (SE)	95% confidence interval of the difference	p-Value
First root	First canal	Saudi	Male	88	19.95	1.30 (0.28)	0.75-1.86	<0.05 ^a	83	20.42	1.22 (0.31)	0.61-1.84	<0.05
			Female	62	18.65				67	19.20			
	Sudanese	Male	54	20.52	0.36 (0.32)	-0.27 to 0.98	0.26	51	20.53	-0.01 (0.29)	-0.58 to -0.57	0.98	
		Female	96	20.16				99	20.54				
Second canal	Saudi	Male	3	19.50	-	-	-	2	19.77	-	-	-	
		Female	0 ^b					0 ^b					
	Sudanese	Male	12	21.00	0.86 (0.69)	-0.55 to 2.28	0.22	1	19.48	-2.02 (1.92)	-8.13 to -4.09	0.37	
		Female	15	20.13				4	21.50				
Second root	First canal	Saudi	Male	4	20.42	-	-	-	1	21.95	-	-	-
			Female	0 ^b					0 ^b				
	Sudanese	Male	6	19.44	1.15 (0.90)	-0.92 to 3.22	0.24	4	20.29	2.09 (2.66)	-6.38 to 10.56	0.49	
		Female	4	18.29				1	18.20				

Abbreviations: N, number; SE, standard error.

^aSignificant with independent t-test.

Table 5 Comparison between the Saudis and Sudanese regarding the canal length of the first and second mandibular premolars

Root number	Root canal length	Nationality	First mandibular premolar				Second mandibular premolar				p-Value	
			N	Mean	Mean Difference (S.E.)	95% confidence interval of the difference	N	Mean	Mean Difference (S.E.)	95% confidence interval of the difference		
First root	First canal	Saudi	150	19.41	0.88 (0.21)	0.46-1.29	150	19.87	0.66 (0.21)	0.25-1.08	< 0.05 ^a	
		Sudanese	150	20.29			150	20.54				
	Second canal	Saudi	3	19.50	1.02 (1.06)	-1.14-3.18	2	19.77	1.33 (1.34)	-2.11-4.76		0.37
		Sudanese	27	20.52			5	21.10				
Second root	First canal	Saudi	4	20.42	-1.44 (0.88)	-3.36-0.48	1	21.95	-2.08 (2.48)	-8.96-4.81	0.45	
		Sudanese	10	18.98			5	19.87				

Abbreviations: N, number.

^aSignificant with independent t-test.

sample size of this study was comparable to what is available in the literature.^{14,17,21,22}

The current study evaluated and compared the first and second mandibular premolars root canal morphology of Saudis and Sudanese using CBCT. Although there was a minor variation in the root canal morphology of the first and second mandibular premolars in the Saudi and Sudanese subpopulations, most of the findings of this study showed that the two groups have a similar root canal morphology in the first and second mandibular premolars except for the types of root canal configuration present in first mandibular premolars and root canal length in a single rooted first and second mandibular premolars. However, there is still a need to evaluate the root canal morphology of these two populations with a larger sample size.

Mandibular premolars are usually present with a single root and a single canal.²³ The present study showed a high percentage of single roots in Saudis and Sudanese first and second mandibular premolars with no statistical difference between the two subpopulations and the males and females in the same subpopulation. However, a small percentage of a second root was observed in both subpopulations' first and second mandibular premolars. Although all Saudi female participants showed single roots in the first and second mandibular premolars, and only one Saudi male participant showed two roots in the second mandibular premolar, there was no statistical difference between all groups. The result of the present study was similar to what was observed in Caucasian subpopulations,²⁴ in which a single root represented 94.2% of mandibular first premolars and 96.6% of mandibular second premolars. However, the percentage of root numbers of mandibular premolars was different in different ethnic groups; for instance, in the Kuwaiti subpopulation, the mandibular premolars showed single roots in 73%, two roots in 24%, and multiple roots in < 1.2%. In addition, in the second mandibular premolars, the single-rooted teeth represent 79.2% compared with 20.8% with two roots.²⁵ These variations in the number of roots of mandibular premolars between different populations demonstrate ethnic variation in the root canal morphology between different groups.

Type I root canal configuration was the most prevalent type observed in both subpopulations. Similar results that show a higher percentage of type I root canal configurations observed in second premolars were also reported in the literature.^{14,24,26} In Saudis, only types I, III, and V root canal configurations were observed in the first and second mandibular premolars. However, this did not correspond with other study,¹⁶ which showed that all types of root canal configurations were observed in the Saudi population except type VII. This variation may be due to the difference in the sample size between the two studies. In Sudanese, multiple root canal configurations were observed (types I, II, III, IV, and V) compared with Saudis, which was statistically significant. Due to the limited studies available in the literature that evaluated the root canal morphology of Sudanese mandibular premolars, a comparison between our findings and

other findings could not be made. Other ethnic groups reported that 64.04% of mandibular first premolars possessed single canal, 34.27% had two canals, and 1.69% had three canals.²¹ The variation in the root canal configuration between the Saudi and Sudanese subpopulations and other populations reported in the literature demonstrates that each ethnic group may possess a different type of root canal configuration.

The root canal length was measured from the tip of the buccal cusp to the apical constriction using the CBCT measuring tools to predict the initial working length. In Saudis, the average length of the first mandibular premolar was in a range of 19.41 to 20.42 mm, and 19.77 to 21.95 mm in second premolars, while in Sudanese, the average canal length of the first mandibular premolar was in a range of 18.98 to 20.52 mm, and 19.87 to 20.1 mm in second premolar. Although there was a minor difference between the canal length in the two groups, there was a statistical difference between the Saudis and Sudanese in the canal length of the first mandibular premolar. The canal lengths of mandibular premolars in each group were in the same range as other lengths reported in the literature for different ethnic groups.¹⁴ Again, this may demonstrate the difference between the two ethnic groups in the morphology of the teeth.

Conclusion

Based on study results, the mandibular premolars are more likely to have a single root with a single canal and type I root canal configuration in the Saudi and Sudanese subpopulations. However, some variations exist between the Saudis and Sudanese within the same subpopulation. These anatomical variations between the two ethnic groups require considerable attention from dentists as they may complicate endodontic treatment. The limitations of this study include the use of different CBCT devices and software to evaluate the root canal morphology of mandibular premolars, which may have compromised image quality standardization. Additionally, a larger sample size is needed to gain better insight into the root canal morphology of mandibular premolars of both populations.

Funding

This research did not receive any specific grant from funding agencies in the public, commercial, or not-for-profit sectors.

Conflict of Interest

None declared.

Acknowledgments

The authors would like to acknowledge the College of Dentistry, King Faisal University, Saudi Arabia, and the 3D Scan Centre, Dental Radiology Centre, Sudan, for providing the data. Also, the authors would like to acknowledge Dr. Elwalid Fadul for the statistical analysis.

References

- 1 Wu MK, Dummer PM, Wesselink PR. Consequences of and strategies to deal with residual post-treatment root canal infection. *Int Endod J* 2006;39(05):343–356
- 2 Siqueira JF Jr, Rôças IN. Present status and future directions: microbiology of endodontic infections. *Int Endod J* 2022;55 (Suppl 3):512–530
- 3 Martins JNR, Marques D, Mata A, Caramês J. Root and root canal morphology of the permanent dentition in a Caucasian population: a cone-beam computed tomography study. *Int Endod J* 2017; 50(11):1013–1026
- 4 Vertucci FJ. Root canal morphology and its relationship to endodontic procedures. *Endod Topics* 2005;10(01):3–29
- 5 Vertucci FJ. Root canal anatomy of the human permanent teeth. *Oral Surg Oral Med Oral Pathol* 1984;58(05):589–599
- 6 Setzer FC, Lee S-M. Radiology in endodontics. *Dent Clin North Am* 2021;65(03):475–486
- 7 Velvart P, Hecker H, Tillinger G. Detection of the apical lesion and the mandibular canal in conventional radiography and computed tomography. *Oral Surg Oral Med Oral Pathol Oral Radiol Endod* 2001;92(06):682–688
- 8 Hounsfield GN. Computerized transverse axial scanning (tomography). 1. Description of system. *Br J Radiol* 1973;46(552):1016–1022
- 9 Scarfe WC, Farman AG. What is cone-beam CT and how does it work? *Dent Clin North Am* 2008;52(04):707–730, v
- 10 Patel S, Brown J, Pimentel T, Kelly RD, Abella F, Durack C. Cone beam computed tomography in endodontics - a review of the literature. *Int Endod J* 2019;52(08):1138–1152
- 11 Vertucci FJ. Root canal morphology of mandibular premolars. *J Am Dent Assoc* 1978;97(01):47–50
- 12 Bulut DG, Kose E, Ozcan G, Sekerci AE, Canger EM, Sisman Y. Evaluation of root morphology and root canal configuration of premolars in the Turkish individuals using cone beam computed tomography. *Eur J Dent* 2015;9(04):551–557
- 13 Kottoor J, Albuquerque D, Velmurugan N, Kuruvilla J. Root anatomy and root canal configuration of human permanent mandibular premolars: a systematic review. *Anat Res Int* 2013;2013:254250
- 14 Pedemonte E, Cabrera C, Torres A, et al. Root and canal morphology of mandibular premolars using cone-beam computed tomography in a Chilean and Belgian subpopulation: a cross-sectional study. *Oral Radiol* 2018;34(02):143–150
- 15 Wolf TG, Anderegg AL, Wierichs RJ, Campus G. Root canal morphology of the mandibular second premolar: a systematic review and meta-analysis. *BMC Oral Health* 2021;21(01):309
- 16 Alfawaz H, Alqedairi A, Al-Dahman YH, et al. Evaluation of root canal morphology of mandibular premolars in a Saudi population using cone beam computed tomography: a retrospective study. *Saudi Dent J* 2019;31(01):137–142
- 17 Chourasia HR, Boreak N, Tarrosh MY, Mashyakhly M. Root canal morphology of mandibular first premolars in Saudi Arabian southern region subpopulation. *Saudi Endod J* 2017;7(02):77–81
- 18 Mashyakhly M, AlTuwaijri N, Alessa R, et al. Anatomical evaluation of root and root canal morphology of permanent mandibular dentition among the Saudi Arabian population: a systematic review. *BioMed Res Int* 2022;2022:2400314
- 19 Nasseh I, Al-Rawi W. Cone beam computed tomography. *Dent Clin North Am* 2018;62(03):361–391
- 20 Todd R. Cone beam computed tomography updated technology for endodontic diagnosis. *Dent Clin North Am* 2014;58(03): 523–543
- 21 Dou L, Li D, Xu T, Tang Y, Yang D. Root anatomy and canal morphology of mandibular first premolars in a Chinese population. *Sci Rep* 2017;7(01):750
- 22 Kaya Büyükbayram I, Sübay RK, Çolakoğlu G, Elçin MA, Ordu Sübay M. Investigation using cone beam computed tomography analysis, of radicular grooves and canal configurations of

- mandibular premolars in a Turkish subpopulation. *Arch Oral Biol* 2019;107:104517
- 23 Cleghorn BM, Christie WH, Dong CC. Anomalous mandibular premolars: a mandibular first premolar with three roots and a mandibular second premolar with a C-shaped canal system. *Int Endod J* 2008;41(11):1005–1014
- 24 Corbella S, Baruffaldi M, Perondi I, Taschieri S. Cone-beam computed tomography investigation of the anatomy of permanent mandibular premolars in a cohort of Caucasians. *J Investig Clin Dent* 2019;10(01):e12373
- 25 Alenezi DJ, Al-Nazhan SA, Al-Maflehi N, Soman C. Root and canal morphology of mandibular premolar teeth in a Kuwaiti subpopulation: a CBCT clinical study. *Eur Endod J* 2020;5(03):248–256
- 26 Yu X, Guo B, Li K-Z, et al. Cone-beam computed tomography study of root and canal morphology of mandibular premolars in a western Chinese population. *BMC Med Imaging* 2012;12:18