




# A Forgotten Cause of Dyspepsia

Brij Sharma<sup>1</sup> Vishal Bodh<sup>1</sup> Anshul Bhateja<sup>1</sup> 

<sup>1</sup> Department of Gastroenterology, IGMC – Shimla, Himachal Pradesh, India

J Digest Endosc

**Address for correspondence** Anshul Bhateja, MD, Senior Resident, Department of Gastroenterology, IGMC-Shimla, Himachal Pradesh, 171001, India (e-mail: dr.anshulabh@gmail.com).

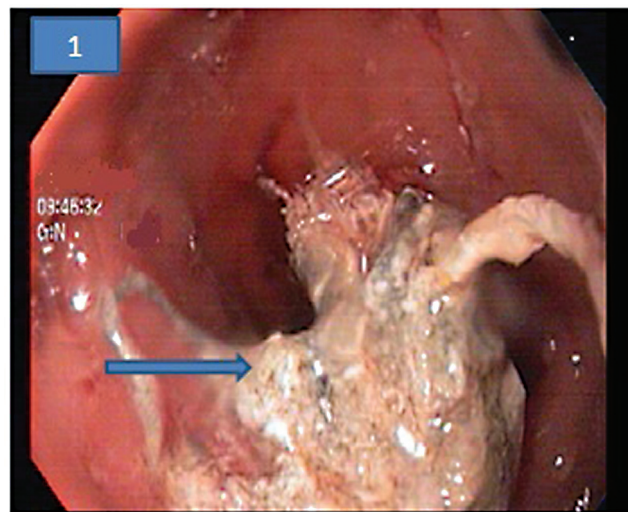
## Abstract

A 63-year-old female patient presented with complaints of epigastric pain for 2 months associated with postprandial fullness and early satiety. She gave history of open cholecystectomy 2 years back at a peripheral hospital. Her general physical and systemic examinations were within normal limits. Her routine investigations including hemogram, liver and renal biochemistries, and ultrasound abdomen were normal. She had received multiple courses of oral proton pump inhibitors, prokinetics, antacids, and antispasmodics but had no relief. In view of her persistent complaint and age more than 60 years, her esophagogastroduodenoscopy (EGD) was planned. Her EGD revealed deeply embedded large gauze piece in the posterior wall of the first part of duodenum. Her contrast-enhanced computed tomography revealed mottled appearance in first part of duodenum, which is nonmobile in subsequent images suggestive of gossypiboma. A final diagnosis of gossypiboma with partial migration of gauge into duodenal lumen was made. Endoscopic removal was not attempted in view of possible risk of perforation and patient shifted to the department of surgery for further management.

## Keywords

- ▶ dyspepsia
- ▶ endoscopy
- ▶ foreign body
- ▶ gossypiboma
- ▶ pain abdomen

A 63-year-old female patient presented with complaints of epigastric pain for the last 2 months associated with postprandial fullness and early satiety. She gave a history of open cholecystectomy 2 years back at a peripheral hospital. Her general physical and systemic examinations were within normal limits. Her routine investigations including hemogram, liver and renal biochemistries, and ultrasound abdomen were normal. She had received multiple courses of oral proton pump inhibitors, prokinetics, antacids, and antispasmodics but had no relief. In view of her persistent complaint and age more than 60 years, her esophagogastroduodenoscopy (EGD) was planned. Her EGD revealed deeply embedded large gauze piece in the posterior wall of the first part of duodenum (►Fig. 1). Rapid urease test was done for *Helicobacter pylori* and was reported negative. Her contrast-enhanced computed tomography revealed mottled appearance in first part of duodenum, which is nonmobile in subsequent images suggestive of gossypiboma (►Fig. 2). A final diagnosis of gossypiboma with partial migration of



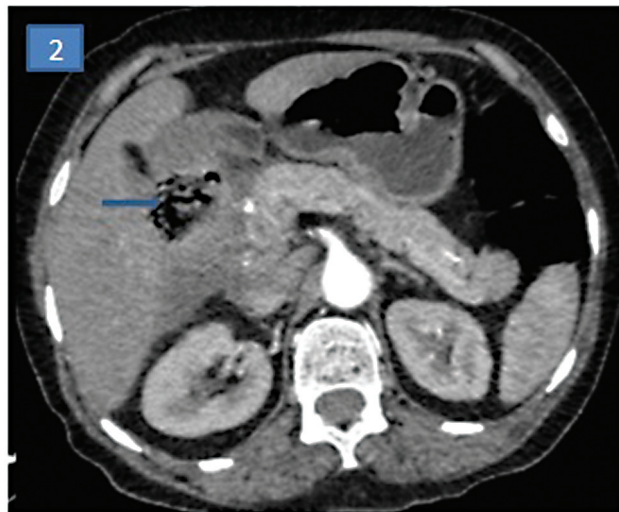
**Fig. 1** Esophagogastroduodenoscopy image showing deeply embedded large gauze piece in the posterior wall of the first part of duodenum (blue solid arrow).

DOI <https://doi.org/10.1055/s-0044-1785225>.  
ISSN 0976-5042.

© 2024. The Author(s).

This is an open access article published by Thieme under the terms of the Creative Commons Attribution License, permitting unrestricted use, distribution, and reproduction so long as the original work is properly cited. (<https://creativecommons.org/licenses/by/4.0/>)

Thieme Medical and Scientific Publishers Pvt. Ltd., A-12, 2nd Floor, Sector 2, Noida-201301 UP, India



**Fig. 2** Contrast-enhanced computed tomography image arrow showing mottled appearance in first part of duodenum suggestive of gossypiboma.

gauge into duodenal lumen was made. Endoscopic removal was not attempted in view of possible risk of perforation and

patient shifted to the department of surgery. Post-surgical removal of the gauze, the symptoms improved drastically and on follow-up, the patient was symptom free.

The term gossypiboma is derived from the Latin word “gossypium” (cotton) and the Swahili “Boma” (place of concealment) that denotes retained surgical sponge.<sup>1</sup> The patient can remain asymptomatic for years or present with vague symptoms like pain abdomen and lump abdomen.<sup>2</sup> Surgical removal remains the mainstay for the treatment, although percutaneous extraction has also been reported.<sup>3</sup>

#### Conflict of Interest

None declared.

#### References

- 1 Gibbs VC, Coakley FD, Reines HD. Preventable errors in the operating room: retained foreign bodies after surgery-Part I. *Curr Probl Surg* 2007;44(05):281-337
- 2 Ray S, Das K. Gossypiboma presented as abdominal lump seven years after open cholecystectomy. *J Surg Case Rep* 2011; 2011(08):2
- 3 Gencosmanoglu R, Inceoglu R. An unusual cause of small bowel obstruction: gossypiboma-case report. *BMC Surg* 2003;3:6