



Prostate Carcinoma: Urologist's Perspective

Anandan Murugesan¹ Gowtham S.M.²

¹ Department of Urology, Kovai Medical Centre and Hospital, Coimbatore, Tamil Nadu, India

² Department of Radiology, Kovai Medical Center and Hospital, Coimbatore, Tamil Nadu, India

Address for correspondence Anandan Murugesan, MS, MCh, Department of Urology, Kovai Medical Centre and Hospital, Coimbatore 641014, Tamil Nadu, India
(e-mail: anandan79@gmail.com; gowthamsm22@gmail.com).

J Gastrointestinal Abdominal Radiol ISGAR

Abstract

Prostate cancer management has undergone radical changes in recent times, due to early diagnosis in localized stage and availability of multiple treatment modalities. But the onus of selecting appropriate treatment rests with the urologist. Radiological investigations are immensely important in these patients. Measurement of prostate-specific antigen and its derivatives is the primary investigation in the diagnosis of prostate carcinoma. Ultrasonogram is of limited utility in prostate carcinoma. Magnetic resonance imaging provides extensive information to the treating physician regarding the approach and the treatment modality to be used in the management of prostate carcinoma. Radiological investigations are the cornerstones for efficient management of prostate carcinoma.

Keywords

- ▶ MRI prostate
- ▶ prostate
- ▶ prostate cancer
- ▶ prostate imaging

Prostate Cancer Imaging: What the Urologist Wants

Prostate cancer (Ca P) is the second most common cancer affecting men. The incidence of Ca P is increasing worldwide and the disease-related mortality is decreasing, due to early diagnosis with better disease detecting modalities and early and effective treatment.¹ The management of Ca P has undergone radical changes from the days of orchidectomy and open radical retropubic prostatectomy to conformal radiotherapy and robot-assisted radical prostatectomy. Minimally invasive treatments like high-frequency focused ultrasound (HIFU) and cryotherapy are also found to have an increasing role in the curative treatment of Ca P in select patients with localized Ca P.²

The availability of various management options has put the onus on the treating urologists to find the most apt option for individualized treatment of patients with Ca P. In this article, we elaborate on the basic diagnostic modalities for Ca P and the information needed from the radiologic investigations in the management of Ca P.

Diagnosis of Carcinoma Prostate

Discussion on the basic clinical features of Ca P is beyond the scope of the article. Most of them are diagnosed based on elevated prostate-specific antigen (PSA) on opportunistic screening.³ The debate on the need for population screening with PSA is still unsettled.⁴ A study by Johansson et al has shown that 230 men need to be screened to prevent 1 death due to Ca P.⁵ Twenty percent to 35% reduction in Ca P mortality over 16 to 18 years has been inferred from a study on Ca P screening.⁶ But 17 years of follow-up with the prostate, lung, colorectal, ovarian screening trial showed no difference in mortality.⁷ Most of the PSA testing is done nowadays in men with lower urinary tract symptoms (LUTSs) who visit a general physician or a urologist.

PSA is the first widely used marker evaluated to diagnose Ca P. It is a member of human kallikrein (hK2) gene family. It is a serine protease helpful in lysis of semen coagulum. Although PSA is elevated in most cases of Ca P, it is not cancer specific. It is fairly organ specific, but not cancer specific.⁸

DOI <https://doi.org/10.1055/s-0044-1782694>.
ISSN 2581-9933.

© 2024. The Author(s).

This is an open access article published by Thieme under the terms of the Creative Commons Attribution License, permitting unrestricted use, distribution, and reproduction so long as the original work is properly cited. (<https://creativecommons.org/licenses/by/4.0/>)
Thieme Medical and Scientific Publishers Pvt. Ltd., A-12, 2nd Floor, Sector 2, Noida-201301 UP, India

The serum concentration of PSA gradually increases with age. Age-specific PSA level is important in selecting patients for biopsy or further evaluation.⁹ The "normal" PSA value cannot be defined. Thompson et al performed prostate biopsies of all patients with PSA less than 4 ng/mL. Fifteen percent of them were found to have Ca P. Interestingly, only 16% of them had clinically significant Ca P with Gleason score of ≥ 7 .¹⁰ 22 to 25% of those with PSA of 4 to 10 ng/mL and 50 to 67% of those with PSA greater than 10 ng/mL have prostate Ca P.¹¹

To improve specificity, analysis of molecular derivatives like free and complexed PSA are used. It is mainly used in PSA values between 2 and 10 ng/dL. The cutoff value for free PSA proportion varies between 15 and 25% in various studies, with more specificity if free PSA is low. Twenty-five percent cutoff led to 20% reduction in biopsies and 95% ca P detection.^{12,13}

The other derivatives of PSA are PSA density and PSA velocity. In PSA values between 4 and 10 ng/mL, PSA density of more than 0.15 had high yield in biopsies. PSA density is calculated by dividing the PSA value by the prostate volume. It is a parameter in risk stratification of patients to manage with active surveillance. It is a marker of aggressiveness of the tumor. PSA velocity is the rate of PSA rise over a particular time period. PSA velocity of more than 0.75 ng/mL/y is significantly associated with Ca p.^{14,15}

Prostate Health Index (PHI) combines total PSA (tPSA), free PSA (fPSA), and p2PSA (prepro - PSA) levels with a specific formula to get the probability of Ca P and the need for biopsy.¹⁶ The 4-kallikrein (4K) panel test is another recent addition to predict the probability of positive clinically significant cancer. It combines the values of tPSA, fPSA, single-chain iPSA (intact), and hK2 to formulate the probability of Ca P and the need for biopsy.¹⁷ PCA3 and TMPRSS: ERG gene fusion mRNA are the urinary biomarkers in line needing further studies for use in the diagnosis of Ca P.¹⁸

Radiological Investigations in Prostate Cancer

Ultrasonography (USG) and magnetic resonance imaging (MRI) are the cornerstones in the diagnosis and management of Ca P.

Ultrasonography in the Diagnosis of Ca P

Transabdominal USG has a limited role in the diagnosis of ca P. It is mainly useful in assessing the detrusor wall thickness. Transrectal ultrasound is useful in accurate measurement of prostate volume. It is also the standard for guided biopsy of the prostate.

Transrectal Ultrasound Guided Biopsy

Twelve-core biopsy is the standard for diagnosis of Ca P. Each biopsy core needs to be sent separately as a template. This detail will help in planning nerve sparing during radical prostatectomy. Higher number of cores may increase the yield, especially in large glands. transrectal ultrasound (TRUS) guided biopsy can be performed by both transrectal and transperineal approaches. The transrectal approach is

the standard for prostate biopsies. But transperineal biopsies are preferred now, with the advantage of less infections and higher yield from anterior gland biopsies and apical biopsies.¹⁹ Targeted biopsies from hypoechoic and other suspicious areas can be done in addition to standard cores.

Magnetic Resonance Imaging in Prostate Cancer

MRI is the cornerstone in the diagnosis and management of Ca P in the present era. Multiparametric MRI (mpMRI) with PI-RADS 2.1 reporting is the standard now.²⁰ MRI-guided fusion biopsies increase the yield of the biopsy cores. Standard 12-core biopsies are mandatory along with targeted biopsies (PI-RADS 3, 4, 5 lesions). Clinically significant cancers are picked up more with targeted biopsy cores of PI-RADS 4 and 5 lesions (**►Fig. 1**).²¹ PI-RADS grades of each lesion in the prostate are necessary. The Patient-Reported Outcomes Measurement Information System trial showed that 27% of patients might avoid biopsy by doing a preprocedure mpMRI.²² Thus, mpMRI may be beneficial to avoid unnecessary biopsies and its related complication and diagnose only clinically significant cancers.

The pictorial representation of the target lesions is helpful during radical prostatectomy. These are even more important in the minimally invasive treatment modalities like cryotherapy and high-intensity focused ultrasound to specifically target the lesions. The findings in MRI, which suggest extravesical spread, indicate the need for extra-fascial dissection during radical prostatectomy.

The signal characteristics of the seminal vesicle indicate the presence of inflammation and hemorrhage. It helps while dissecting seminal vesicles to anticipate adhesions around them and precise surgery. Obvious involvement of the seminal vesicles upstages the disease and might change the management options. Prior information regarding the exact prostate volume and the prominent intravesical protrusion of the prostate is necessary to anticipate intraoperative difficulties. The distance of the ureteric orifices from the bladder neck (especially in those with short trigones) will help in preventing injuries to ureteric orifices during bladder neck division. Bladder wall thickness and upper tract status should be known. The presence of significant lymphadenopathy (pelvic) necessitates further evaluation with prostate-specific membrane antigen (PSMA) positron emission tomography (PET) to rule out other sites of metastases. Definite evidence of axial skeleton involvement with sclerotic bone metastases made out on MRI upstages the disease to stage IV.

Positron Emission Tomography

PSMA PET has been used primarily to assess the metastatic status of Ca P. PET may be used to diagnose lymphatic involvement, if nomograms indicate higher probability of metastases. MRI might show enlargement of lymphnodes, but activity in PET is more suggestive of metastases. PSMA PET is also more sensitive for bone metastases compared to Tc-99m methylene diphosphonate bone scan. (68% vs 98%).²³ Exact load of metastatic disease is essential to decide the

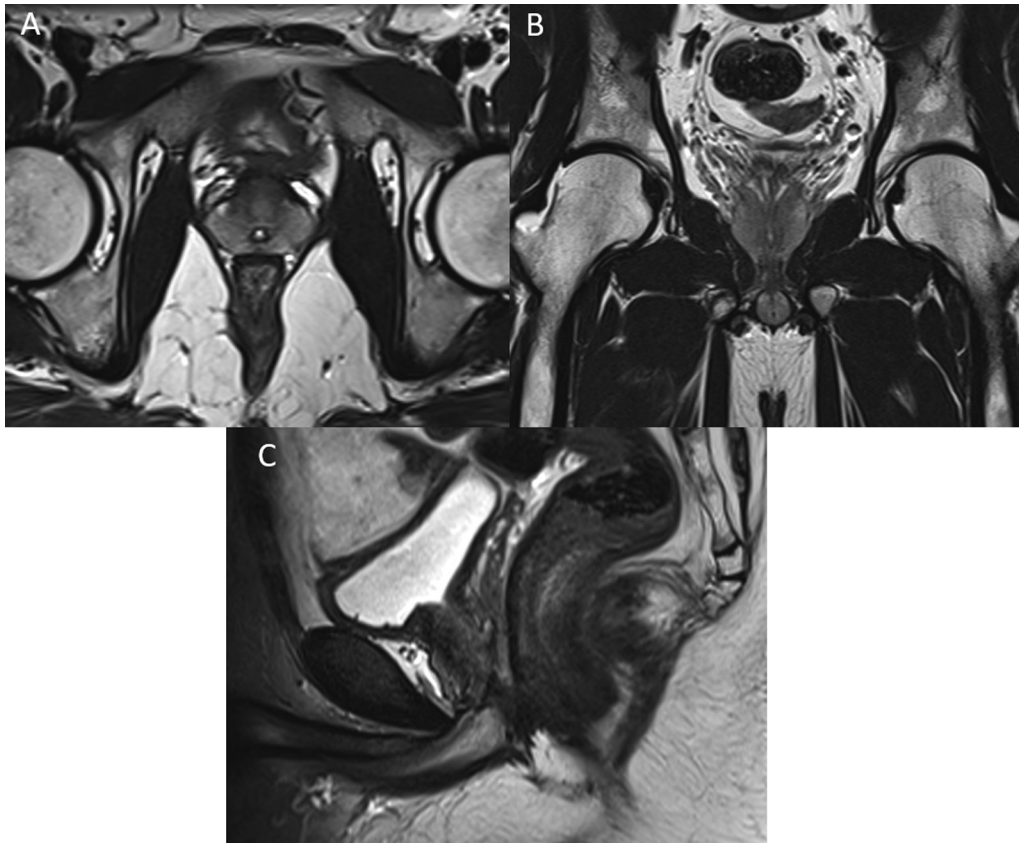


Fig. 1 Axial (A), coronal (B) and sagittal (C) T2 MR images showing normal prostate gland in 30 year old man.

management and PSMA PET is helpful in that aspect. Recently PSMA PET has also been evaluated for diagnosis and selection of patients for biopsy, showing promising results.²⁴

Bone Scan and Computed Tomography

Computed tomography (CT) has limited role in Ca P. Bone scan (Tc MDP), though of lesser sensitivity, is the standard for metastatic workup according to major guidelines. Metastatic lesions light up in bone scan due to osteoblastic activity. SPECT CT with bone scan increases the sensitivity.²³

Pentafecta in Postsurgery Outcomes

Continence, potency, recurrence-free survival, negative surgical margins, and no postoperative complications designate the pentafecta outcome evaluation criteria.^{24,25} These primarily depend on meticulous preoperative planning and individualization of surgical approach. Target lesions identified in the MRI in the apex or base requires meticulous dissection in the concerned areas to prevent positive margins.

Conclusion

Imaging studies in Ca P are an essential part of treatment planning. Accurate information regarding the tumor location and extent along with that of nearby organs will have an impact on the successful management of Ca P.

Funding

None.

Conflict of Interest

None declared.

References

- Bergengren O, Pekala KR, Matsoukas K, et al. 2022 update on prostate cancer epidemiology and risk factors: a systematic review. *Eur Urol* 2023;84(02):191–206
- Valerio M, Ahmed HU, Emberton M, et al. The role of focal therapy in the management of localised prostate cancer: a systematic review. *Eur Urol* 2014;66(04):732–751
- Dubey D. The routine use of prostate-specific antigen for early detection of cancer prostate in India: is it justified? *Indian J Urol* 2009;25(02):177–184
- Carlsson SV, Vickers AJ. Screening for prostate cancer. *Med Clin North Am* 2020;104(06):1051–1062
- Hugosson J, Roobol MJ, Månsson M, et al; ERSPC investigators. A 16-yr follow-up of the European randomized study of screening for prostate cancer. *Eur Urol* 2019;76(01):43–51
- Hugosson J, Godtman RA, Carlsson SV, et al. Eighteen-year follow-up of the Göteborg Randomized Population-based Prostate Cancer Screening Trial: effect of sociodemographic variables on participation, prostate cancer incidence and mortality. *Scand J Urol* 2018;52(01):27–37
- Pinsky PF, Miller E, Prorok P, Grubb R, Crawford ED, Andriole G. Extended follow-up for prostate cancer incidence and mortality among participants in the prostate, lung, colorectal and ovarian randomized cancer screening trial. *BJU Int* 2019;123(05): 854–860

- 8 Makarov DV, Carter HB. The discovery of prostate specific antigen as a biomarker for the early detection of adenocarcinoma of the prostate. *J Urol* 2006;176(6, Pt 1):2383–2385
- 9 Matti B, Xia W, van der Werf B, Zargar-Shoshtari K. Age-adjusted reference values for prostate specific antigen: a systematic review and meta-analysis. *Clin Genitourin Cancer* 2022;20(02): e114–e125
- 10 Thompson IM, Pauler DK, Goodman PJ, et al. Prevalence of prostate cancer among men with a prostate-specific antigen level < or =4.0 ng per milliliter. *N Engl J Med* 2004;350(22):2239–2246
- 11 Sivaraman A, Bhat KRS. Screening and detection of prostate cancer: review of literature and current perspective. *Indian J Surg Oncol* 2017;8(02):160–168
- 12 Yim K, Ma C, Carlsson S, et al. Free PSA and clinically significant and fatal prostate cancer in the PLCO screening trial. *J Urol* 2023; 210(04):630–638
- 13 Roddam AW, Duffy MJ, Hamdy FC, et al; NHS Prostate Cancer Risk Management Programme. Use of prostate-specific antigen (PSA) isoforms for the detection of prostate cancer in men with a PSA level of 2–10 ng/ml: systematic review and meta-analysis. *Eur Urol* 2005;48(03):386–399, discussion 398–399
- 14 Djavan B, Zlotta A, Kratzik C, et al. PSA, PSA density, PSA density of transition zone, free/total PSA ratio, and PSA velocity for early detection of prostate cancer in men with serum PSA 2.5 to 4.0 ng/mL. *Urology* 1999;54(03):517–522
- 15 Nordström T, Akre O, Aly M, Grönberg H, Eklund M. Prostate-specific antigen (PSA) density in the diagnostic algorithm of prostate cancer. *Prostate Cancer Prostatic Dis* 2018;21(01):57–63
- 16 Loeb S, Sanda MG, Broyles DL, et al. The prostate health index selectively identifies clinically significant prostate cancer. *J Urol* 2015;193(04):1163–1169
- 17 McDonald ML, Parsons JK. 4-kallikrein test and kallikrein markers in prostate cancer screening. *Urol Clin North Am* 2016;43(01): 39–46
- 18 Tosoian JJ, Ross AE, Sokoll LJ, Partin AW, Pavlovich CP. Urinary biomarkers for prostate cancer. *Urol Clin North Am* 2016;43(01): 17–38
- 19 Sivaraman A, Ramasamy V, Aarthi P, Sankar V, Sivaraman PB. Safety and feasibility of freehand transperineal prostate biopsy under local anesthesia: our initial experience. *Indian J Urol* 2022; 38(01):34–41
- 20 Razeek AAKA, El-Diasty T, Elhendy A, Fahmy D, El-Adalany MA. Prostate Imaging Reporting and Data System (PI-RADS): what the radiologists need to know? *Clin Imaging* 2021;79:183–200
- 21 Ahdoot M, Lebastchi AH, Long L, et al; Trio Study Group. Using Prostate Imaging-Reporting and Data System (PI-RADS) scores to select an optimal prostate biopsy method: a secondary analysis of the Trio study. *Eur Urol Oncol* 2022;5(02):176–186
- 22 Ahmed HU, El-Shater Bosaily A, Brown LC, et al; PROMIS study group. Diagnostic accuracy of multi-parametric MRI and TRUS biopsy in prostate cancer (PROMIS): a paired validating confirmatory study. *Lancet* 2017;389(10071):815–822
- 23 Mohseninia N, Zamani-Siahkali N, Harsini S, Divband G, Pirich C, Beheshti M. Bone metastasis in prostate cancer: bone scan versus PET imaging. *Semin Nucl Med* 2024;54(01):97–118
- 24 Hicks RM, Simko JP, Westphalen AC, et al. Diagnostic accuracy of ⁶⁸Ga-PSMA-11 PET/MRI compared with multiparametric MRI in the detection of prostate cancer. *Radiology* 2018;289(03): 730–737
- 25 Patel VR, Sivaraman A, Coelho RF, et al. Pentafecta: a new concept for reporting outcomes of robot-assisted laparoscopic radical prostatectomy. *Eur Urol* 2011;59(05):702–707