



Antithrombotic Therapy for Inferior Vena Cava Stenting of Malignant Inferior Vena Cava Syndrome: A Questionnaire Study of Japan Interventional Radiology Study Group (JIVROSG)

Mizuki Ozawa¹ Miyuki Sone¹ Shunsuke Sugawara¹ Yasuaki Arai¹ Masahiko Kusumoto¹

¹Department of Diagnostic Radiology, National Cancer Center Hospital, Tsukiji, Chuo-ku, Tokyo, Japan

Address for correspondence Mizuki Ozawa, MD, Department of Diagnostic Radiology, National Cancer Center Hospital, 5-1-1, Tsukiji, Chuo-ku, Tokyo 1040045, Japan (e-mail: mizukiozawa0717@gmail.com).

Arab J Intervent Radiol

Abstract

Purpose The aim of this study was to evaluate the differences in antithrombotic therapy policies for inferior vena cava (IVC) stent placement among institutions and interventional radiologists in Japan.

Materials and Methods The cross-sectional online-based questionnaire was conducted between December 2022 and January 2023, and a total of 114 institutions were included in this study. The questionnaire contained eight questions that were grouped into three sections: (1) whether IVC stents have been performed or not, (2) the number of IVC stent placements, and (3) the basic strategy of antithrombotic therapy for pre-, intra-, and post-IVC stent placement.

Results Of the 114 institutions, 38 responses (33%) were collected. Twenty-four of the 38 institutions (63%) had performed IVC stent placement during the study period. The mean number of IVC stent placements during the study period was 3.4 cases per institution. The most frequently selected antithrombotic therapeutic strategies pre-, intra-, and post-stenting were no antithrombotic therapy (62.5%), anticoagulation therapy (54.2%), and no antithrombotic therapy (41.7%).

Conclusion This study has revealed there is no consensus regarding antithrombotic therapy for IVC stent placement in Japan. The results of this study may contribute to our understanding of the status of antithrombotic therapy for IVC stent placement. Future prospective studies are warranted to clarify the periprocedural antithrombotic therapy for IVC stent placement.

Keywords

- ▶ malignant IVC syndrome
- ▶ inferior vena cava stent
- ▶ anticoagulation therapy

Introduction

Inferior vena cava (IVC) stent placement for malignant IVC syndrome is highly feasible and effective.¹⁻⁶ Although some studies have presented evidence for antithrombotic therapy after arterial stenting, including that of coronary arteries,^{7,8} the necessity of antithrombotic therapy for IVC stent placement remains controversial. In addition, the selection and

duration of antithrombotic therapy is not standardized and are determined based on both the experience of interventional radiologists and the policies of individual institutions. Unnecessary antithrombotic therapy should be avoided, especially in patients with cancer who are prone to coagulation abnormalities. Therefore, the lack of a standardized antithrombotic therapy policy for IVC stent placement is undesirable.

DOI <https://doi.org/10.1055/s-0044-1782693>.
ISSN 2542-7075.

© 2024. The Author(s).

This is an open access article published by Thieme under the terms of the Creative Commons Attribution License, permitting unrestricted use, distribution, and reproduction so long as the original work is properly cited. (<https://creativecommons.org/licenses/by/4.0/>).

Thieme Medical and Scientific Publishers Pvt. Ltd., A-12, 2nd Floor, Sector 2, Noida-201301 UP, India

- 1) Whether IVC stent placements have been performed since October 2019 (after the insurance coverage of IVC stent in our country). If no IVC stent placement was performed during the period, subsequent questions could be omitted.
- 2) Please indicate the number of IVC stent placement from October to December 2019.
- 3) Please indicate the number of IVC stent placement from January to December 2020.
- 4) Please indicate the number of IVC stent placement from January to December 2021.
- 5) Please indicate the number of IVC stent placement from January to December 2022.
- 6) Please select the basic strategy of antithrombotic therapy for pre-IVC stent placement from the following four categories.
 - i. No antithrombotic therapy
 - ii. Anticoagulation therapy
 - iii. Antiplatelet therapy
 - iv. Combination of antiplatelet and anticoagulation therapy
- 7) Please select the basic strategy of antithrombotic therapy for intra-IVC stent placement from the four categories listed in question no.6.
- 8) Please select the basic strategy of antithrombotic therapy for post-IVC stent placement from the four categories listed in question no.6.

Fig. 1 Questionnaire for Interventional Radiologists on Antithrombotic Therapy for Inferior Vena Cava Stenting of Malignant Inferior Vena Cava Syndrome. IVC, inferior vena cava.

In Japan, IVC stents were covered by insurance in 2019 after many years of off-label use. As a result, the number of cases has increased and is expected to increase further in the future; however, the status of antithrombotic therapy in clinical practice remains unclear.

This study aimed to assess the current status of antithrombotic therapy for IVC stent placement and identify the differences in antithrombotic therapy policies among institutions and interventional radiologists in Japan.

Materials and Methods

Study Design

This cross-sectional online questionnaire was conducted between December 2022 and January 2023. This study was approved by the local institutional review board (IRB), and the need for informed consent was waived. A total of 114 member institutions of the Japan Interventional Radiology in Oncology Study Group (JIVROSG) were included. JIVROSG is a Japanese multicenter academic organization established in 2002 to conduct clinical trials of interventional radiology in the field of oncology, also known as interventional oncology.

One reminder was sent during the study period, and only a single response was allowed. A questionnaire response was considered complete if the respondent completed all components of each section of the questionnaire.

Questionnaire

This questionnaire contained eight questions that were grouped into three sections: (1) whether IVC stents have been used since October 2019 (after insurance coverage of IVC stents commenced in Japan), (2) the number of IVC stent

placements, and (3) the basic strategy of antithrombotic therapy for IVC stent placement. The details of the questionnaire are shown in ► **Fig. 1**.

Antithrombotic therapy strategies were classified into the following four categories: (1) no antithrombotic therapy, (2) antiplatelet therapy, (3) anticoagulation therapy, and (4) a combination of antiplatelet and anticoagulation therapy. Answers to the pre-, intra-, and poststenting strategies of antithrombotic therapy based on the four categories were obtained from each institution, and the ratio of each category was calculated.

Results

Of the 114 institutions, 38 responses were collected (a 33% response rate). Twenty-four of the 38 institutions (63%) had performed IVC stent placement during the study period. The total number of IVC stent placements during the study period was 82 (mean: 3.4 cases per institution). For pre-stenting therapy, no antithrombotic therapy (15/24, 62.5%) was the most commonly selected strategy, followed by anticoagulation therapy (6/24, 25%), a combination of antiplatelet and anticoagulation therapy (2/24, 8.3%), and antiplatelet therapy (1/24, 4.2%). For intrastenting, anticoagulation therapy (13/24, 54.2%) was most frequently selected, followed by no antithrombotic therapy (8/24, 33.3%), antiplatelet therapy (2/24, 8.3%), and a combination of antiplatelet and anticoagulation therapy (1/24, 4.2%). For poststenting, no antithrombotic therapy (10/24, 41.7%) was selected, followed by anticoagulation therapy (7/24, 29.1%), a combination of antiplatelet and anticoagulation therapy (4/24, 16.7%), and antiplatelet therapy (3/24, 12.5%; ► **Figs. 2–4**).

Discussion

This survey suggests that there is no consensus in Japan regarding antithrombotic therapy for IVC stent placement. The most frequently selected antithrombotic therapeutic strategies pre-, intra-, and poststenting were no antithrombotic therapy (62.5%), anticoagulation therapy (54.2%), and no antithrombotic therapy (41.7%).

A previous retrospective descriptive study reported that 33% of patients with cancer who received IVC stent placement without anticoagulation therapy experienced symptom recurrence during the follow-up period.¹ In contrast, another study reported no significant difference in symptom recurrence rates after IVC stent placement with or without anticoagulation therapy.⁹ Furthermore, Arendt et al recently published that there was no difference between patient groups with subtherapeutic and therapeutic anticoagulation in terms of procedure-related complication rates, rates of reintervention, and clinical improvement after nonthrombotic venous stent placement.¹⁰ Thus, there is insufficient evidence regarding the necessity and appropriate use of antithrombotic therapy for IVC stent placement, and further prospective studies are warranted. Based on the results of this study, the type, amount, and duration of antithrombotic therapy should be standardized in further evaluations.

Basic strategy of antithrombotic therapy for pre-IVC stent placement

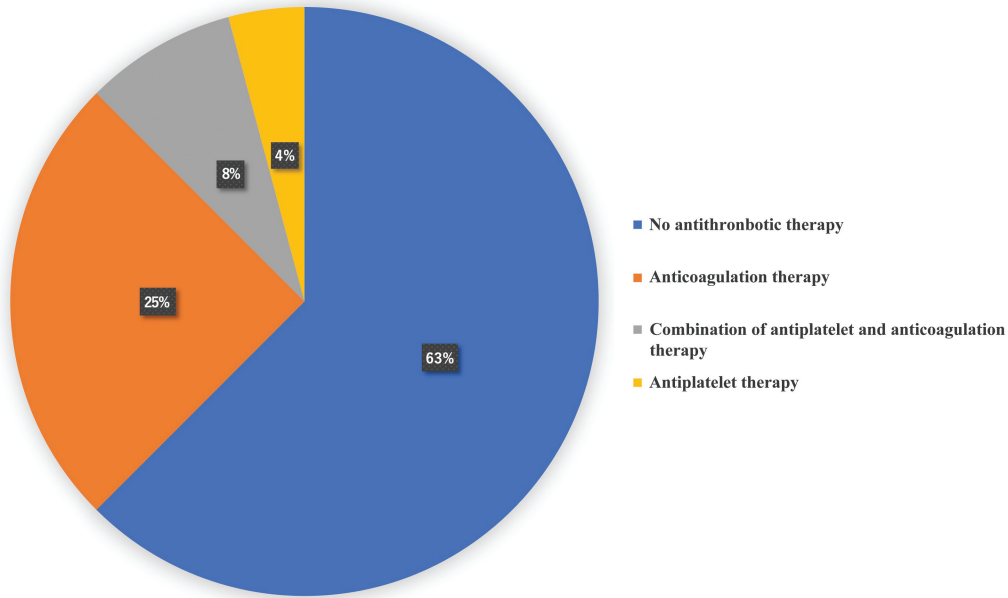


Fig. 2 Pie charts regarding the results of question 6 in questionnaire. IVC, inferior vena cava.

This study had several limitations. First, the study was conducted on a limited number of institutions in a single country. Second, not all of institutions that responded to the questionnaire performed IVC stent placement. In addition, the type, amount, and duration of antithrombotic therapy were not described in detail.

In conclusion, the use of antithrombotic therapy for IVC stent placement varies widely among institutions and interventional radiologists in Japan. The results of this study contribute to our understanding of the current status of

antithrombotic therapy for IVC stent placement. Future research is warranted to clarify specific clinical situations that require periprocedural antithrombotic therapy and determine the optimal strategy.

Ethical Approval Statement

All procedures performed in studies involving human participants were in accordance with the ethical standards of the institutional and/or national research committee and with the 1964 Helsinki declaration and its later

Basic strategy of antithrombotic therapy for intra-IVC stent placement

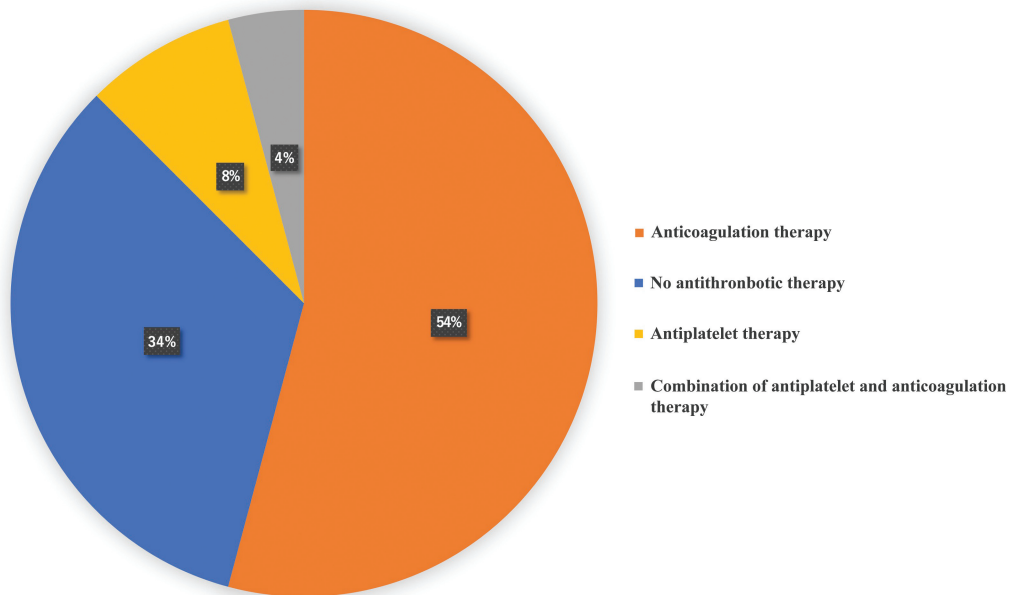


Fig. 3 Pie charts regarding the results of question 7 in questionnaire. IVC, inferior vena cava.

Basic strategy of antithrombotic therapy for post-IVC stent placement

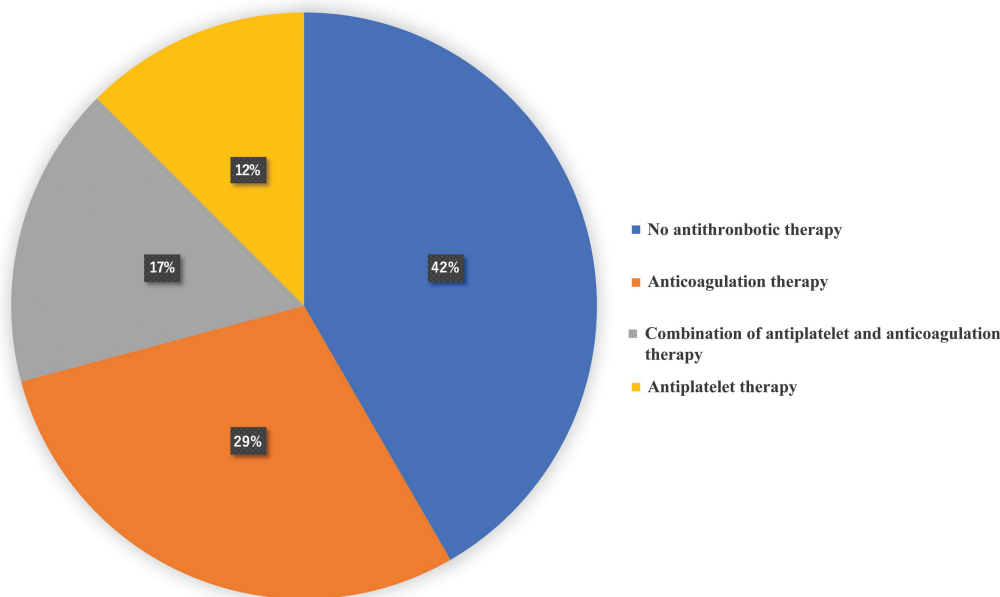


Fig. 4 Pie charts regarding the results of question 8 in questionnaire. IVC, inferior vena cava.

amendments or comparable ethical standards. For this type of study, formal consent is not required. This retrospective study was approved by the Institutional Ethics Committee (approval number: NCCH-2018-049).

Data Availability Statement

All the data published within this article will be made available by the corresponding author, upon reasonable request. We take full responsibility for the data, analyses, interpretation, and research conduct. We have full access to all data and have obtained the rights to publish these results.

Authors' Contribution

All authors made substantial contributions to the study concept or the data analysis or interpretation, drafted the manuscript or revised it critically for important intellectual content, approved the final version of the manuscript to be published, and agreed to be accountable for all aspects of the work.

Funding

This study was funded by the National Cancer Center under the National Cancer Center Research and Development Fund (grant number 2020-J-3). The funding body had no role in the design of the study; collection, analysis, or interpretation of data; or in writing the manuscript.

Conflict of Interest

None declared.

Acknowledgment

We would like to thank Gerard Goh, MD, for his editorial assistance of this manuscript, and the members of Japan

Interventional Radiology in Oncology Study Group for their input and help with the survey. We also would like to thank Editage (www.editage.com) for English language editing. This study has never been presented anywhere.

References

- 1 Brountzos EN, Binkert CA, Panagiotou IE, Petersen BD, Timmermans H, Lakin PC. Clinical outcome after intrahepatic venous stent placement for malignant inferior vena cava syndrome. *Cardiovasc Intervent Radiol* 2004;27(02):129-136
- 2 Kuetting D, Thomas D, Wilhelm K, Pieper CC, Schild HH, Meyer C. Endovascular management of malignant inferior vena cava syndromes. *Cardiovasc Intervent Radiol* 2017;40(12):1873-1881
- 3 Tanigawa N, Sawada S, Mishima K, et al. Clinical outcome of stenting in superior vena cava syndrome associated with malignant tumors. Comparison with conventional treatment. *Acta Radiol* 1998;39(06):669-674
- 4 Takeuchi Y, Arai Y, Sone M, et al. Evaluation of stent placement for vena cava syndrome: phase II trial and phase III randomized controlled trial. *Support Care Cancer* 2019;27(03):1081-1088
- 5 Sato Y, Inaba Y, Yamaura H, Takaki H, Arai Y. Malignant inferior vena cava syndrome and congestive hepatic failure treated by venous stent placement. *J Vasc Interv Radiol* 2012;23(10):1377-1380
- 6 Oudkerk M, Heystraten FMJ, Stoter G. Stenting in malignant vena caval obstruction. *Cancer* 1993;71(01):142-146
- 7 Levine GN, Bates ER, Bittl JA, et al. 2016 ACC/AHA Guideline Focused Update on Duration of Dual Antiplatelet Therapy in Patients With Coronary Artery Disease: A Report of the American College of Cardiology/American Heart Association Task Force on Clinical Practice Guidelines: An Update of the 2011 ACCF/AHA/SCAI Guideline for Percutaneous Coronary Intervention, 2011 ACCF/AHA Guideline for Coronary Artery Bypass Graft Surgery, 2012 ACC/AHA/ACP/AATS/PCNA/SCAI/STS Guideline for the Diagnosis and Management of Patients With Stable Ischemic Heart Disease, 2013 ACCF/AHA Guideline for the Management of ST-Elevation Myocardial Infarction, 2014 AHA/ACC Guideline for the Management of Patients With Non-ST-Elevation Acute Coronary

- Syndromes, and 2014 ACC/AHA Guideline on Perioperative Cardiovascular Evaluation and Management of Patients Undergoing Noncardiac Surgery. *Circulation* 2016;134(10):e123–e155
- 8 Valgimigli M, Bueno H, Byrne RA, et al; ESC Scientific Document Group ESC Committee for Practice Guidelines (CPG) ESC National Cardiac Societies. 2017 ESC focused update on dual antiplatelet therapy in coronary artery disease developed in collaboration with EACTS: The Task Force for dual antiplatelet therapy in coronary artery disease of the European Society of Cardiology (ESC) and of the European Association for Cardio-Thoracic Surgery (EACTS). *Eur Heart J* 2018;39(03):213–260
 - 9 Ozawa M, Sone M, Sugawara S, et al. Necessity of prophylactic anticoagulation therapy following inferior vena cava stent placement in patients with cancer. *Interv Radiol (Higashimatsuyama)* 2023;8(2):70–74
 - 10 Arendt VA, Mabud TS, Kuo WT, et al. Comparison of anticoagulation regimens following stent placement for nonthrombotic lower extremity venous disease. *J Vasc Interv Radiol* 2021;32(11):1584–1590