

Single-Lumen Anastomosis in a Septated Cephalic Vein for Creation of a Proximal AV Fistula

Swaminathan Ravi¹ Parag Sahasrabudhe² Ankur Karanjkar² Avinash Ignatius³ Saurabh Khiste³

¹ Department of Plastic and Reconstructive Surgery, Noble Hospitals, Pune, Maharashtra, India

² Department of Plastic and Reconstructive Surgery, B. J. Government Medical College and Sassoon General Hospitals, Pune, Maharashtra, India

³ Department of Nephrology, Noble Hospitals, Pune, Maharashtra, India

Indian J Plast Surg

Address for correspondence Swaminathan Ravi, MBBS, MS General Surgery, MCh Plastic & Reconstructive Surgery, DrNB Plastic & Reconstructive Surgery, Department of Plastic and Reconstructive Surgeon, Noble Hospitals, 706, Amar Srushti, Off Pune Solapur Highway, Hadapsar, Pune 411028, Maharashtra, India (e-mail: richie2089@gmail.com).

Respected Sir,

The burden of chronic kidney disease requiring hemodialysis in India has been estimated to be 175,000 patients with a prevalence of 129 per million population.¹

We would like to report this interesting anatomical anomaly encountered at our center of a septated cephalic vein proximal to the cubital crease along with our technique of managing the same. We did an extensive literature search and could not find any such anomaly reported during arteriovenous fistula (AVF) creation. Knowledge of the existence of such an anomaly and how to successfully create an AVF and protect an access site will be advantageous.

A 57-year-old male diagnosed with end-stage renal disease (ESRD) and on maintenance hemodialysis via temporary dialysis catheter was referred to us for the creation of an AVF. On evaluation clinically and on preoperative ultrasound Doppler the cephalic vein was diminutive at the wrist with a diameter of less than 2 mm that led to us choosing to create an end-to-side brachiocephalic AVF. The report did not mention the existence of any luminal septum. Intraoperatively, on dividing the cephalic vein distally at the cubital crease, a vertical septum was noted in the lumen. On trimming the vein proximally, the septum was noted to extend up to a distance of approximately 3 cm proximal to the cubital crease (►Fig. 1). A line drawing of the same is depicted (►Fig. 2). Heparinized saline was flushed through both lumens and a thrill was palpable proximally over the vein. An end-to-side anastomosis was done using 7-0 Polypropylene suture incorporating the posterior wall of the arteriotomy with the posterior wall

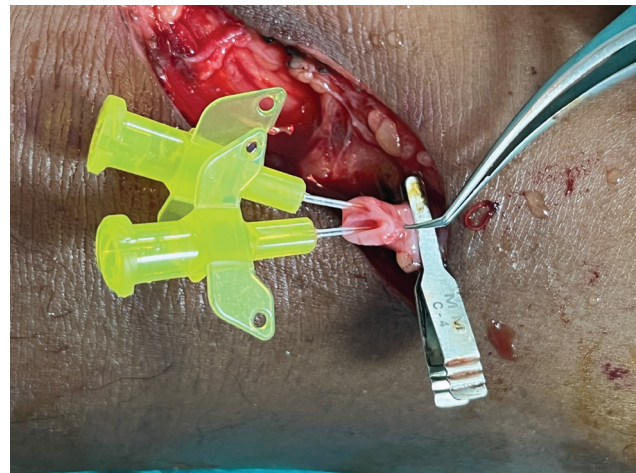


Fig. 1 Septated cephalic vein seen with intracath placed in each of the lumens.

of the cephalic vein and the septum while the anterior wall was completed by approximating the anterior walls of the artery and vein, thus obliterating the smaller lumen (►Fig. 3).

Hemostasis was achieved after removal of the clamps and a palpable thrill was noted in the arm along with an audible bruit. The vein was well dilated with adequate arterial flow.

An ultrasound Doppler was repeated postoperatively that showed a septum in the cephalic vein extending proximally for a distance of 2.6 cm from the site of anastomosis. A similar

DOI <https://doi.org/10.1055/s-0044-1781446>.
ISSN 0970-0358.

© 2024. Association of Plastic Surgeons of India. All rights reserved. This is an open access article published by Thieme under the terms of the Creative Commons Attribution-NonDerivative-NonCommercial-License, permitting copying and reproduction so long as the original work is given appropriate credit. Contents may not be used for commercial purposes, or adapted, remixed, transformed or built upon. (<https://creativecommons.org/licenses/by-nc-nd/4.0/>)

Thieme Medical and Scientific Publishers Pvt. Ltd., A-12, 2nd Floor, Sector 2, Noida-201301 UP, India

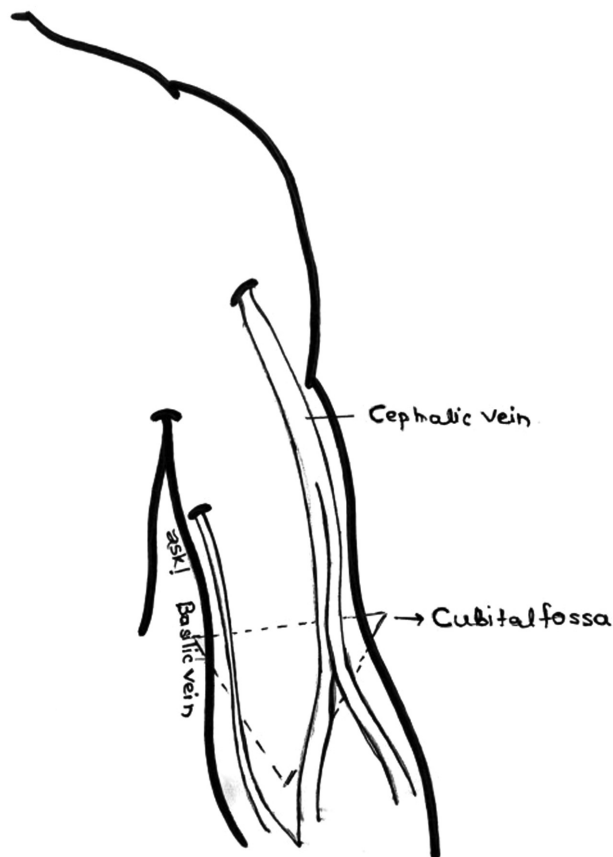


Fig. 2 Line drawing depicting the formation of the cephalic vein and persistent septum.

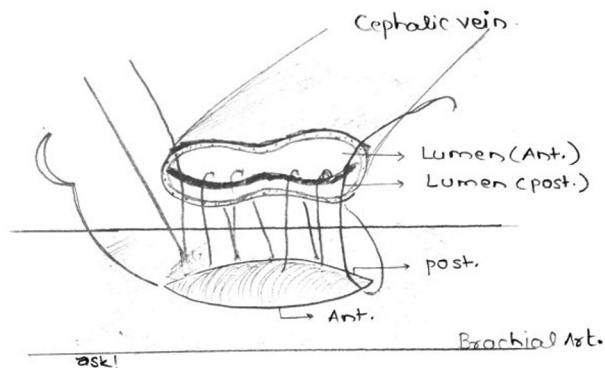


Fig. 3 Line drawing depicting the technique of anastomosis of one of the lumens with the brachial artery posterior wall using continuous sutures.

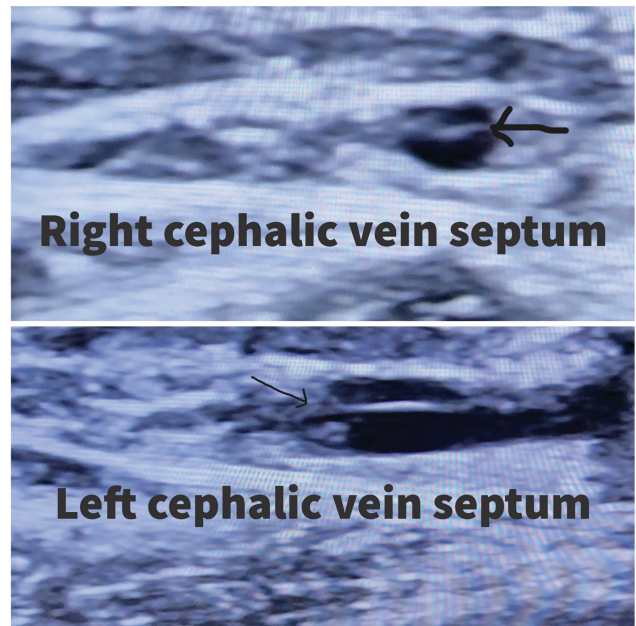


Fig. 4 Ultrasound image showing the septum in the lumen of the right and left cephalic veins marked by arrows.

septum was noted in the right cephalic vein from the confluence of the forearm veins running into the arm with healthy color flow noted in both lumens (**►Fig. 4**).

The patient successfully underwent hemodialysis by cannulation of the matured AVF after 6 weeks with adequate flow velocity in the cephalic vein. Most AVF are created under local anesthesia with relatively smaller access incisions and encountering such an anomaly intraoperatively limits our option to trim the vein proximally and perform a higher anastomosis. Each AVF site for ESRD patients is precious and needs to be carefully used and preserved. In this patient, we have proposed a method of anastomosis to one of the lumens while simultaneously closing the other lumen with the suture, which led to successful maturation and use of the vein for hemodialysis.

Conflict of Interest

None declared.

Reference

- 1 Bharati J, Jha V. Global dialysis perspective: India. *Kidney360* 2020;1(10):1143–1147